
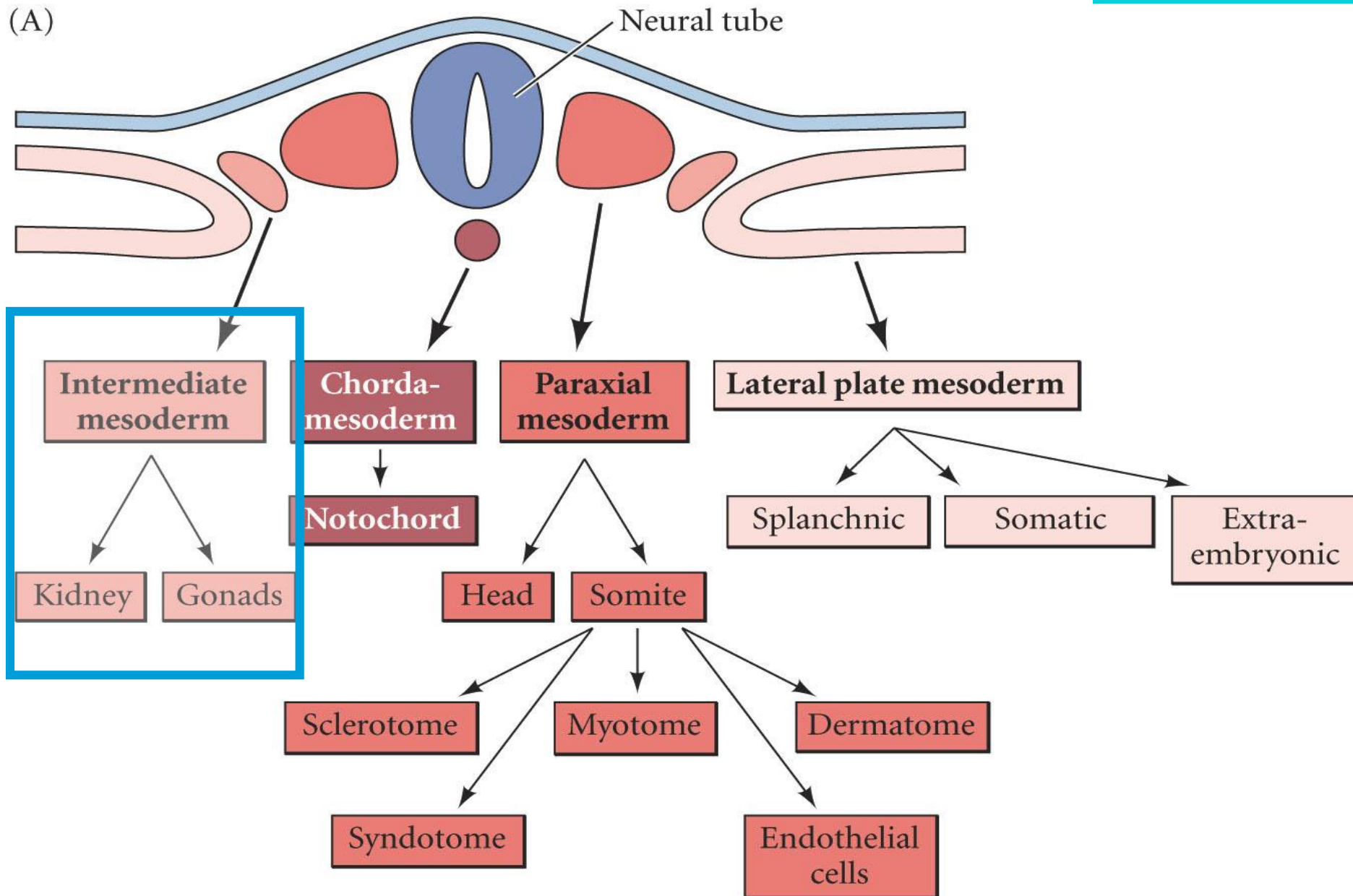
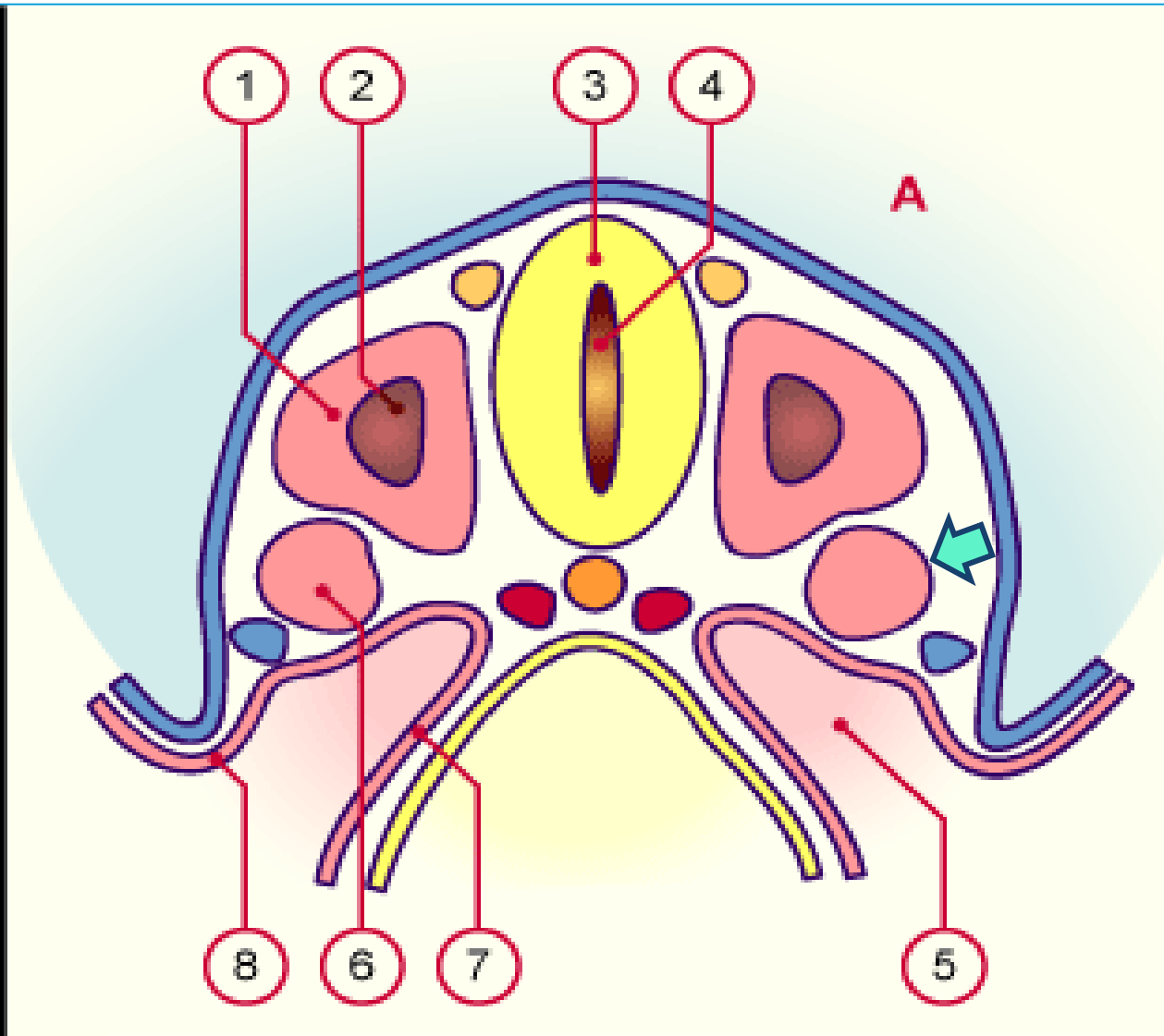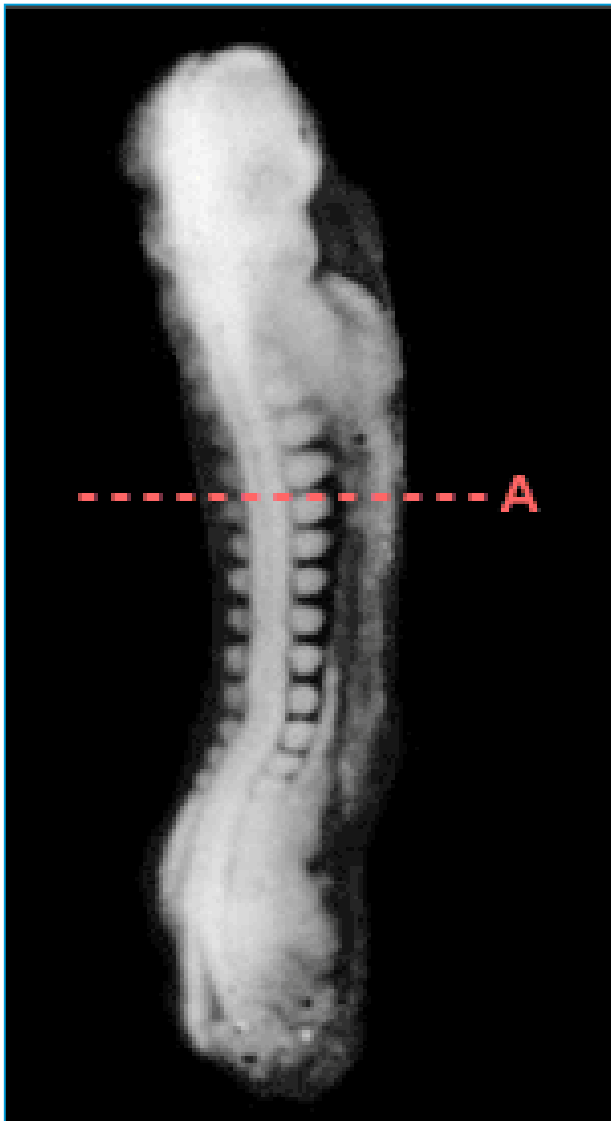


# Neurulación

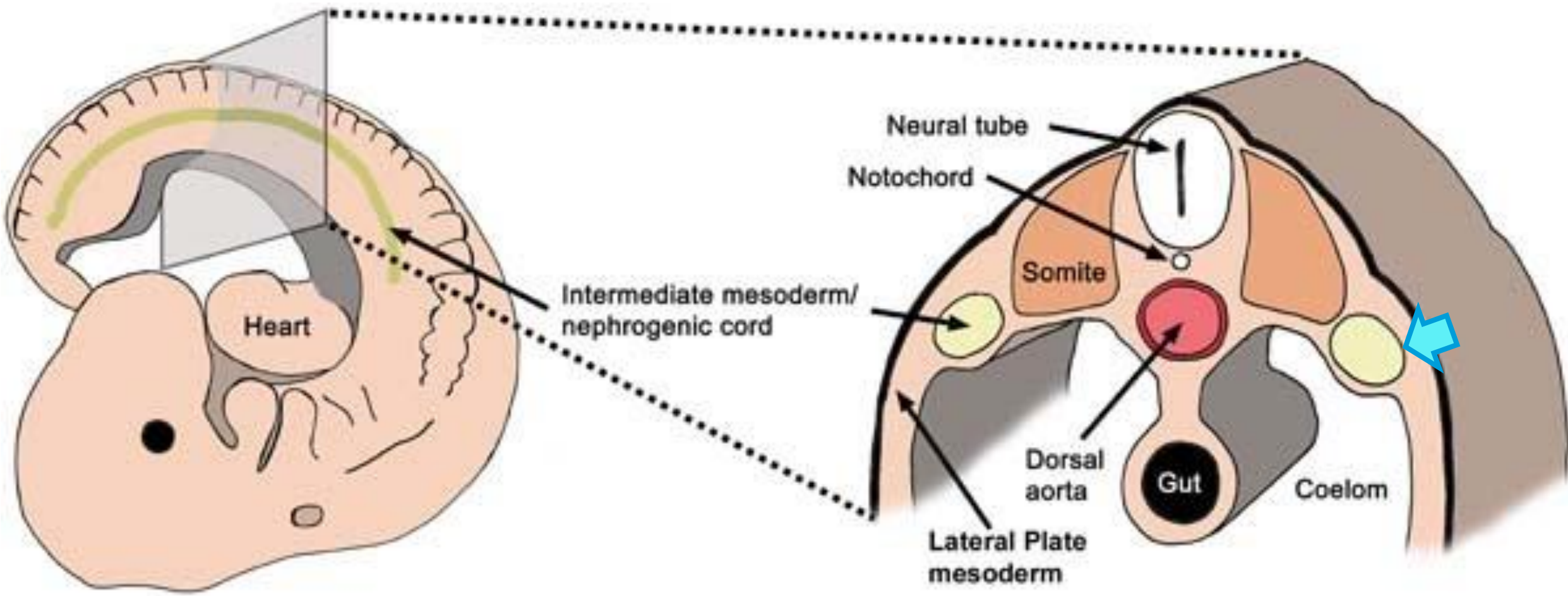




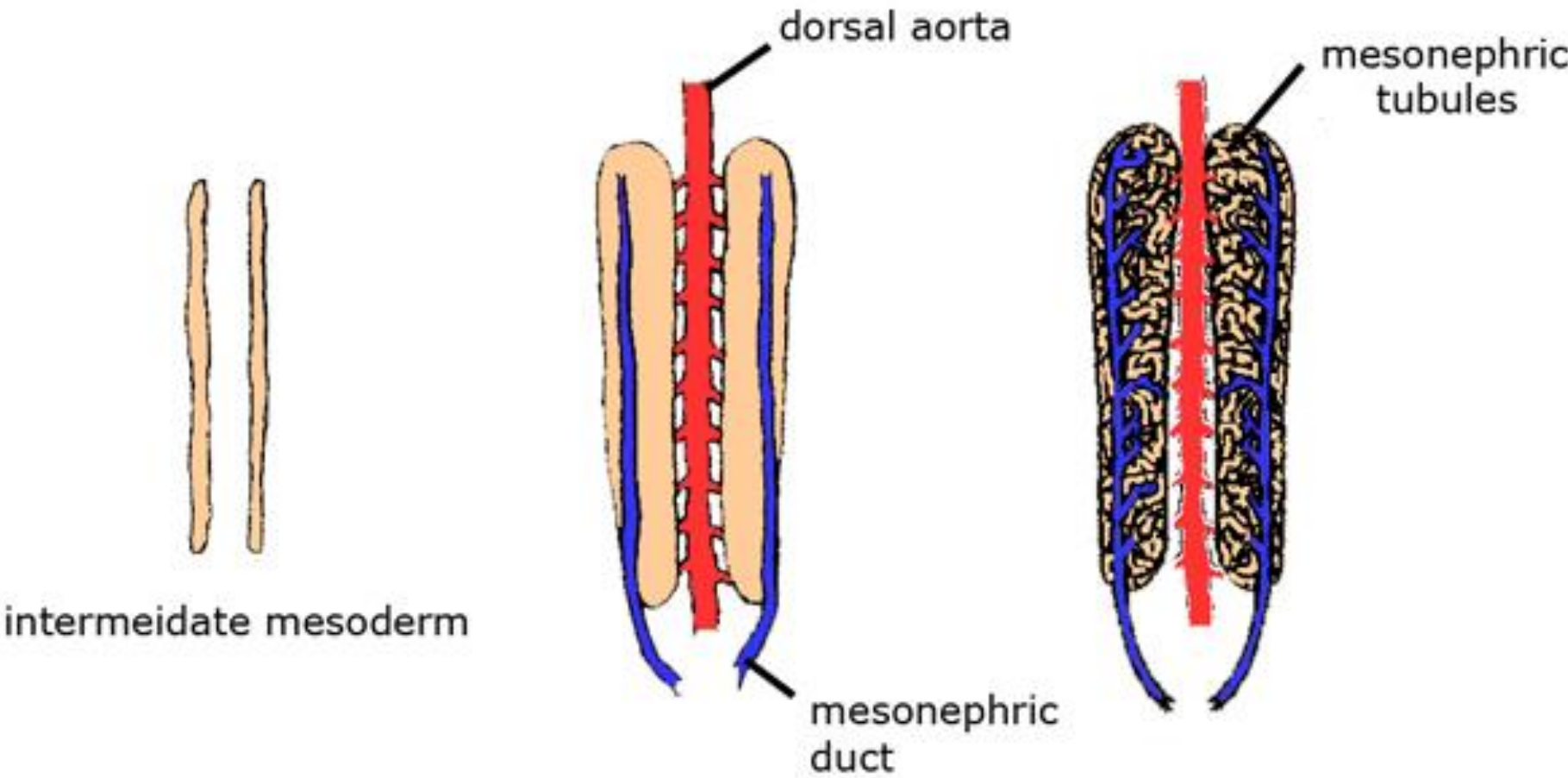


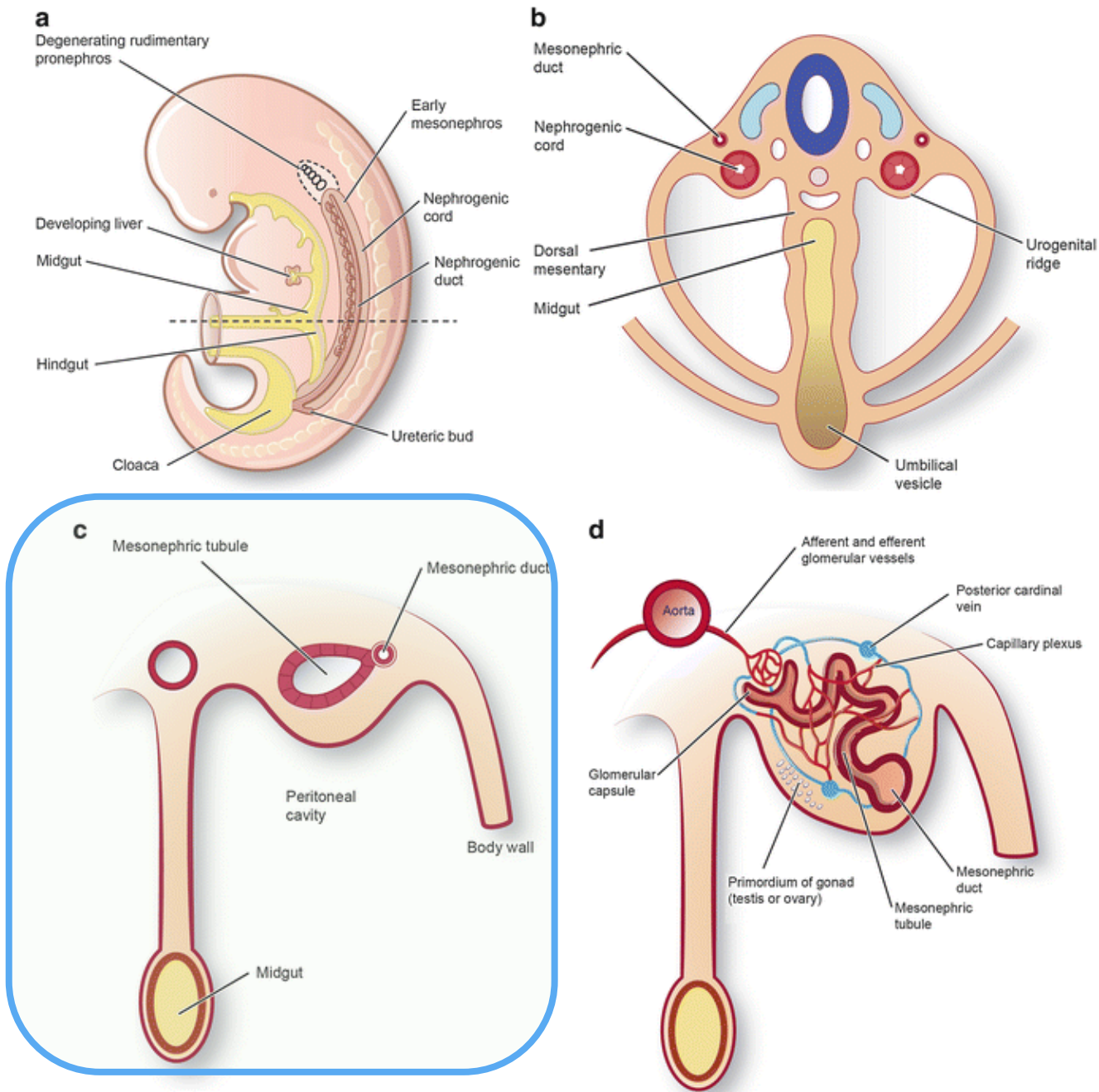
1. Somita
2. Lumen de cada somita
3. Tubo neural
4. Canal endodimal
5. Celoma
6. **Mesodermo intermedio**
7. Esplacnopleura
8. Somatopleura

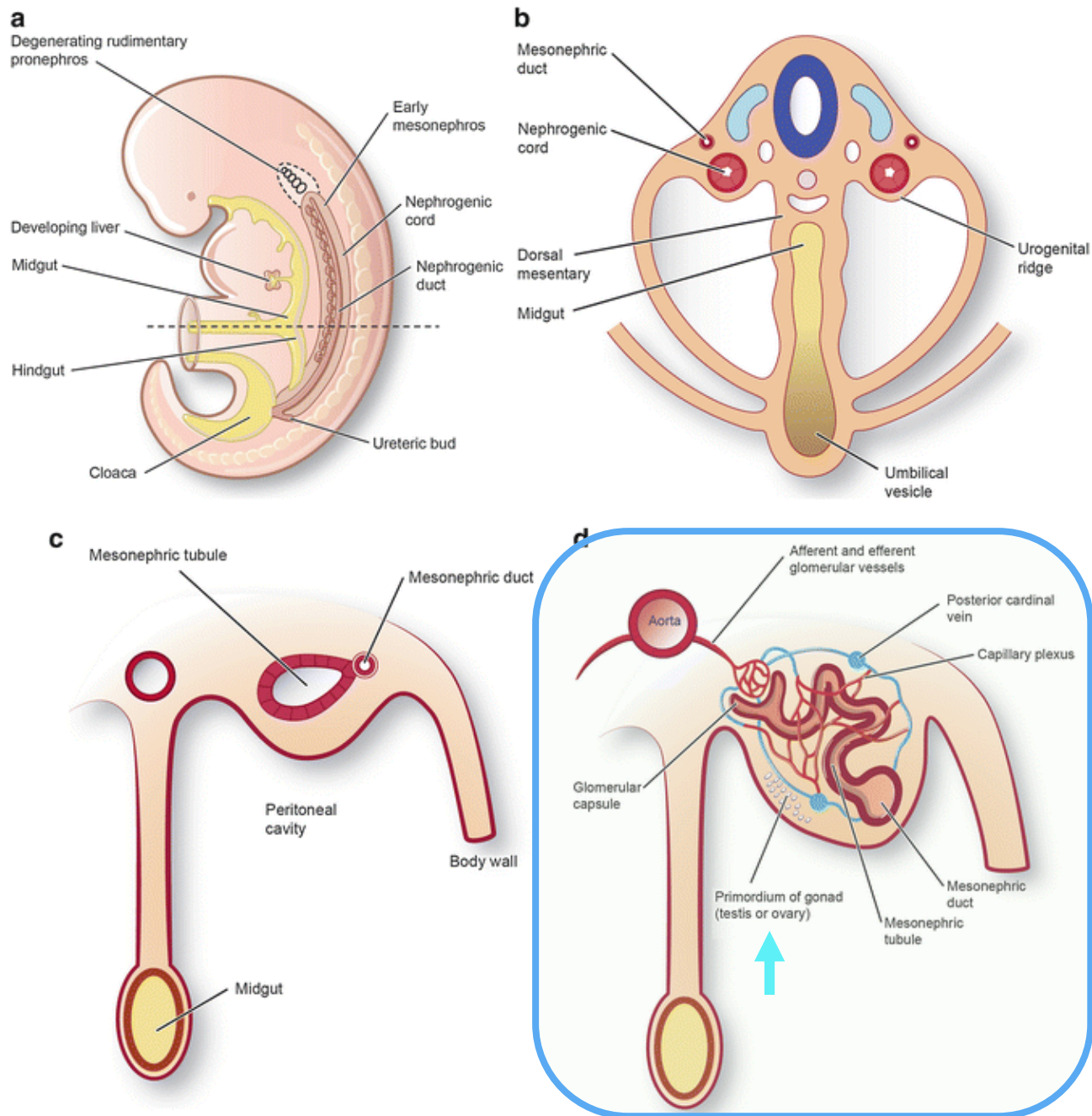


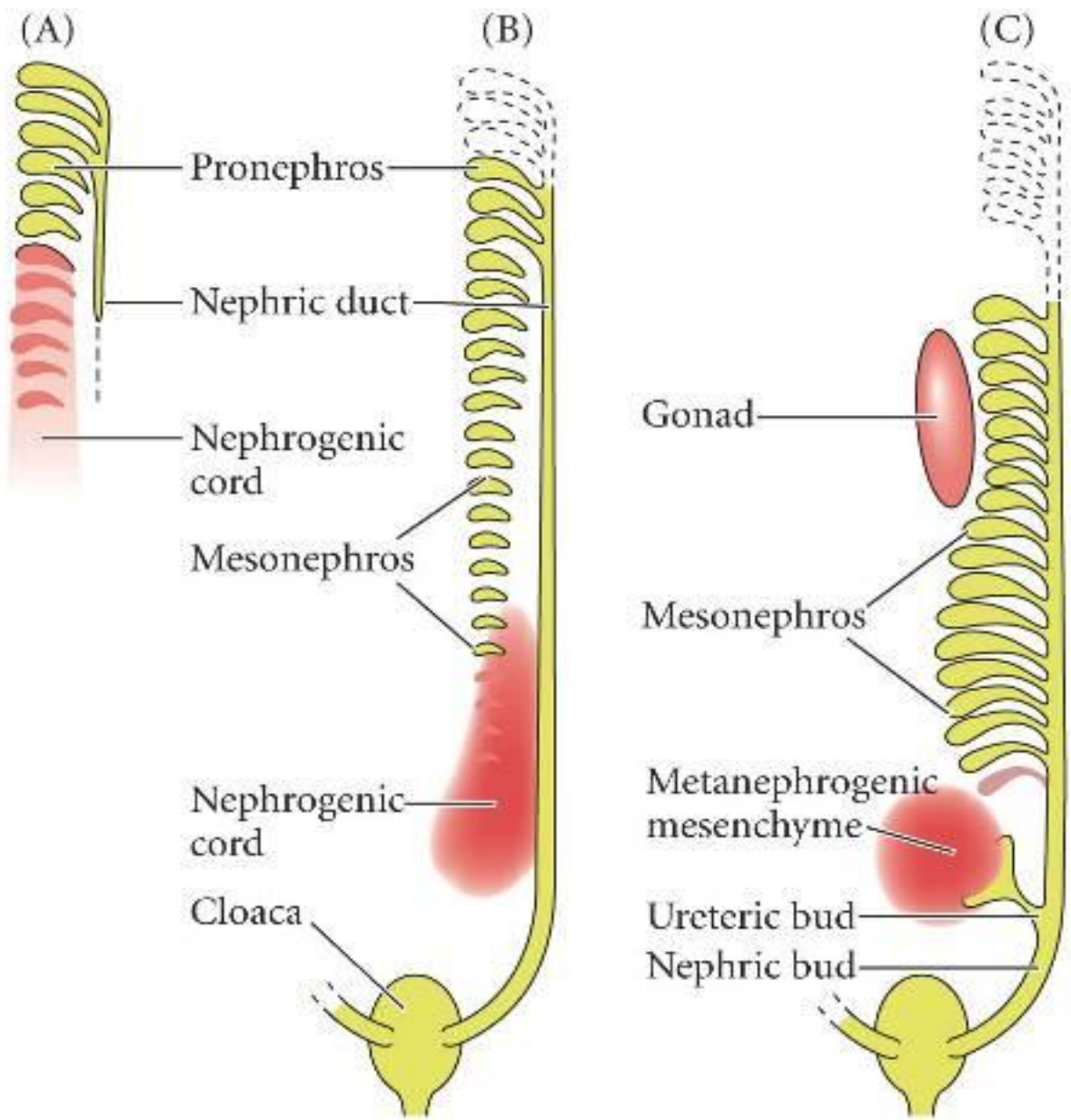


# Embryonic progress of mesonephros development



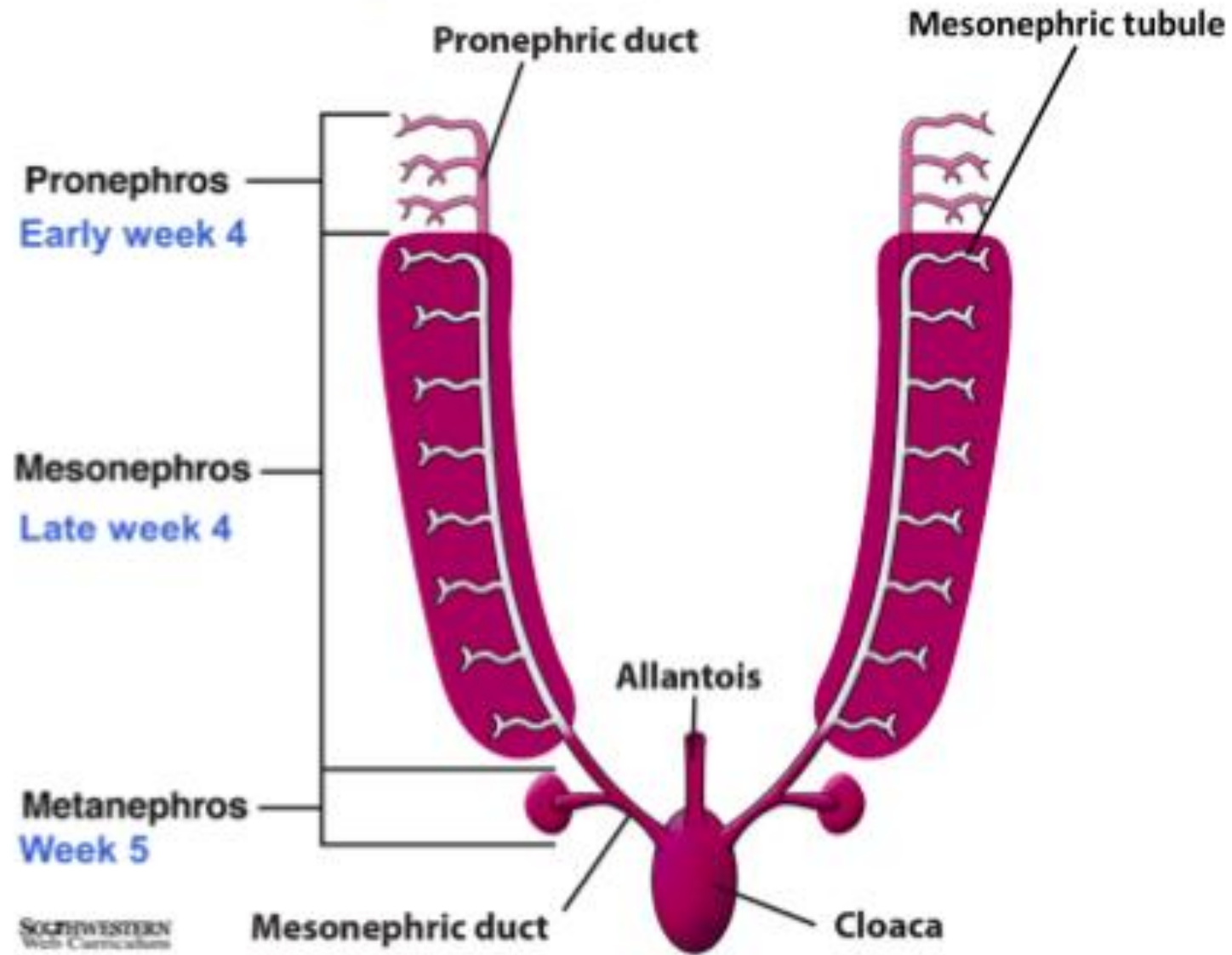


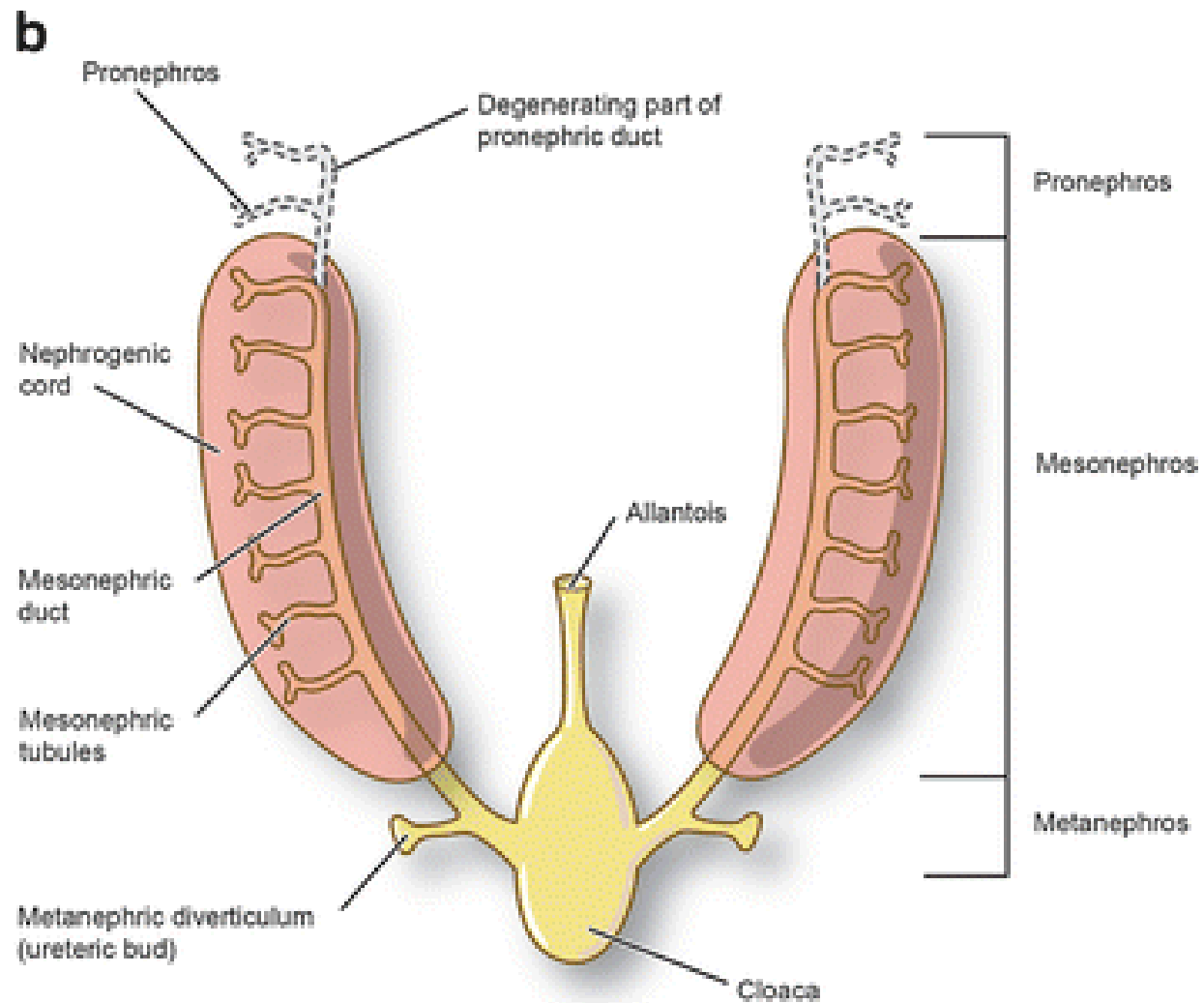
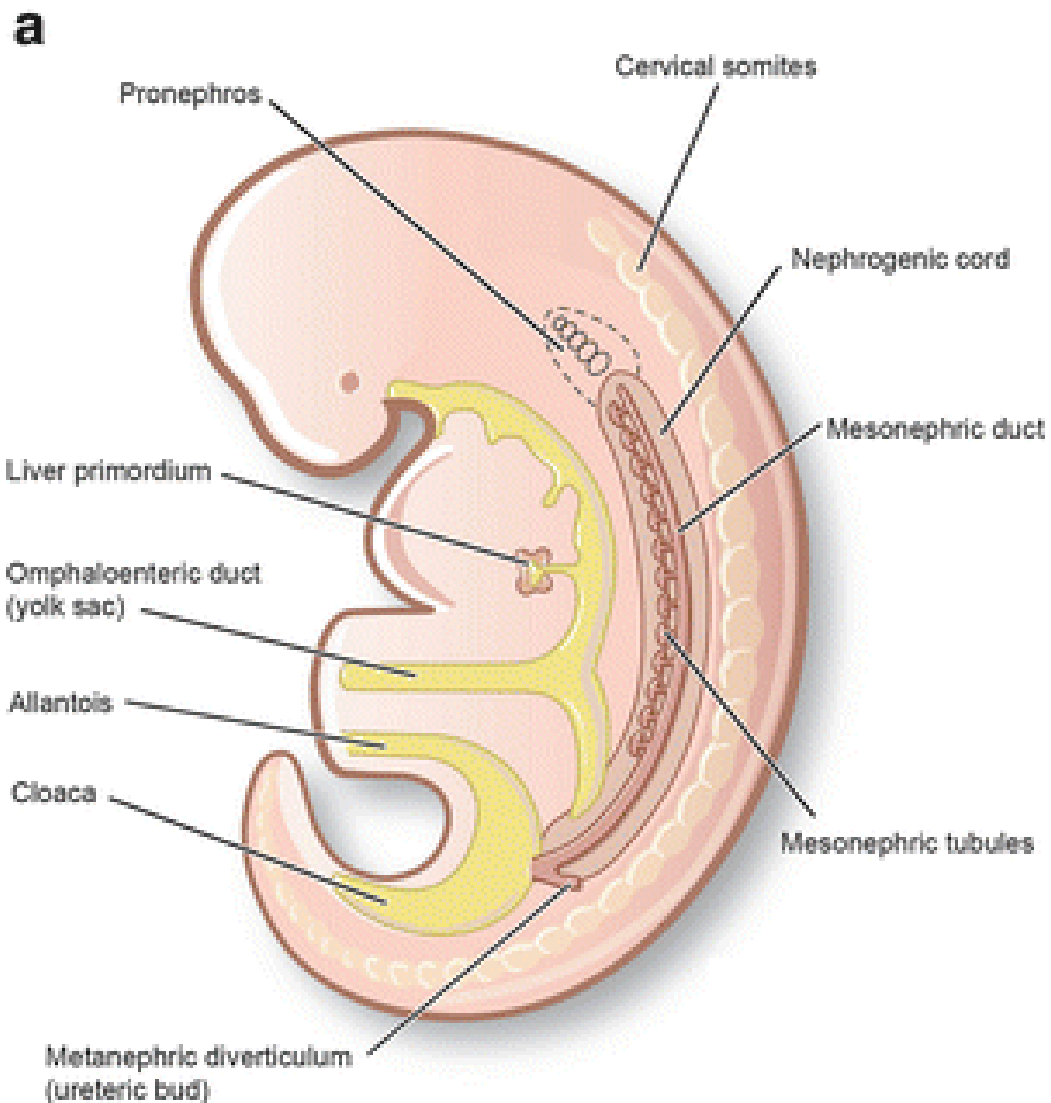


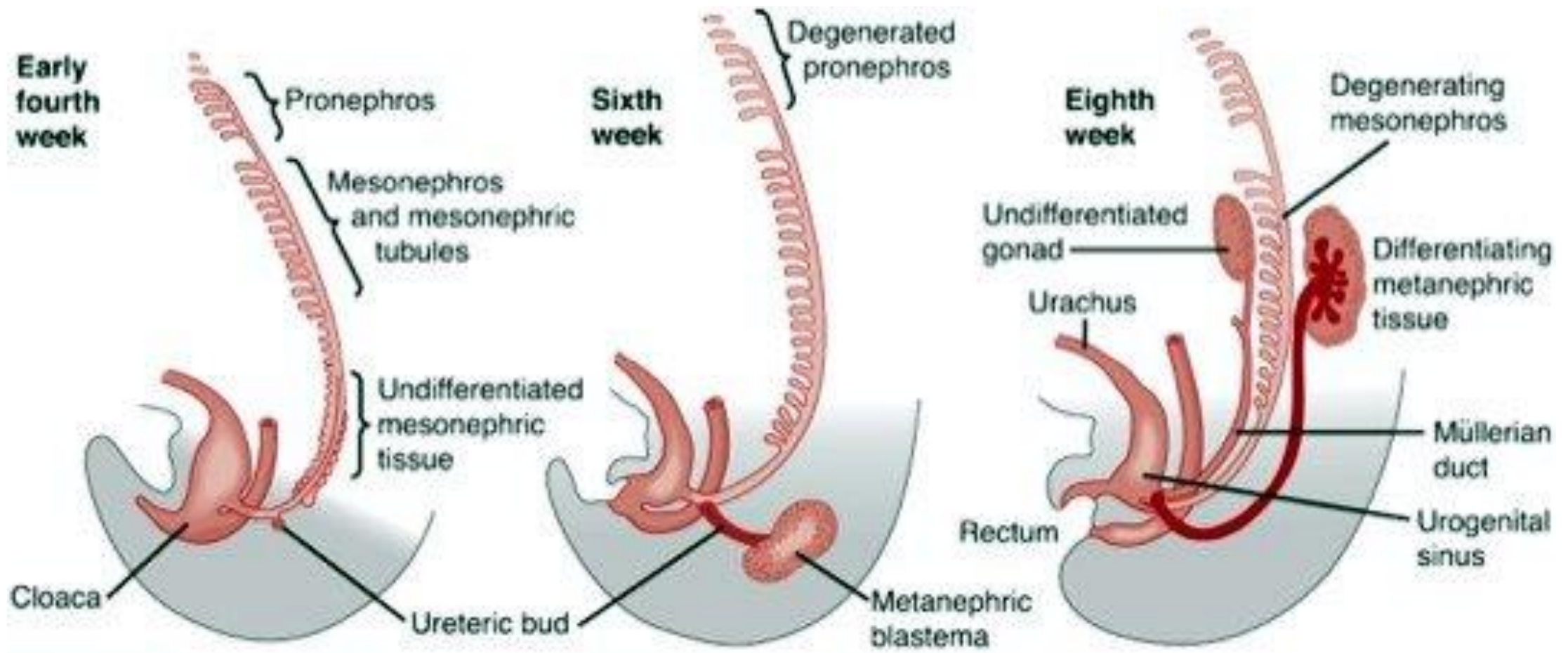




# Kidney development

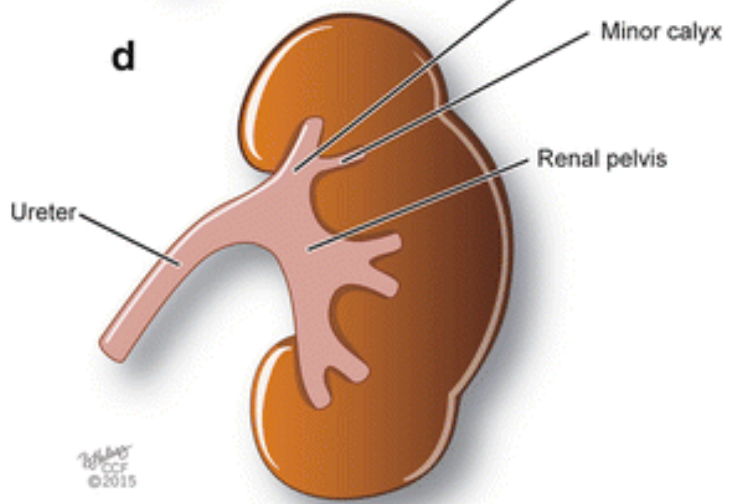
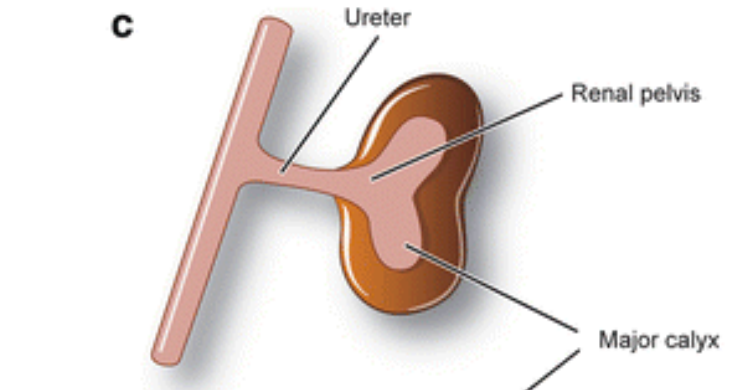
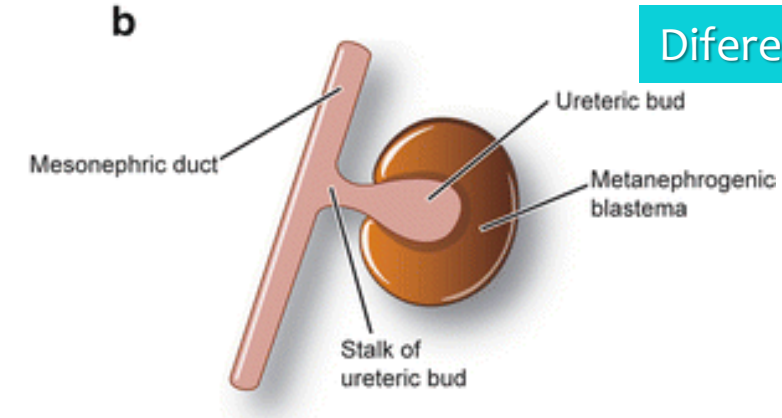
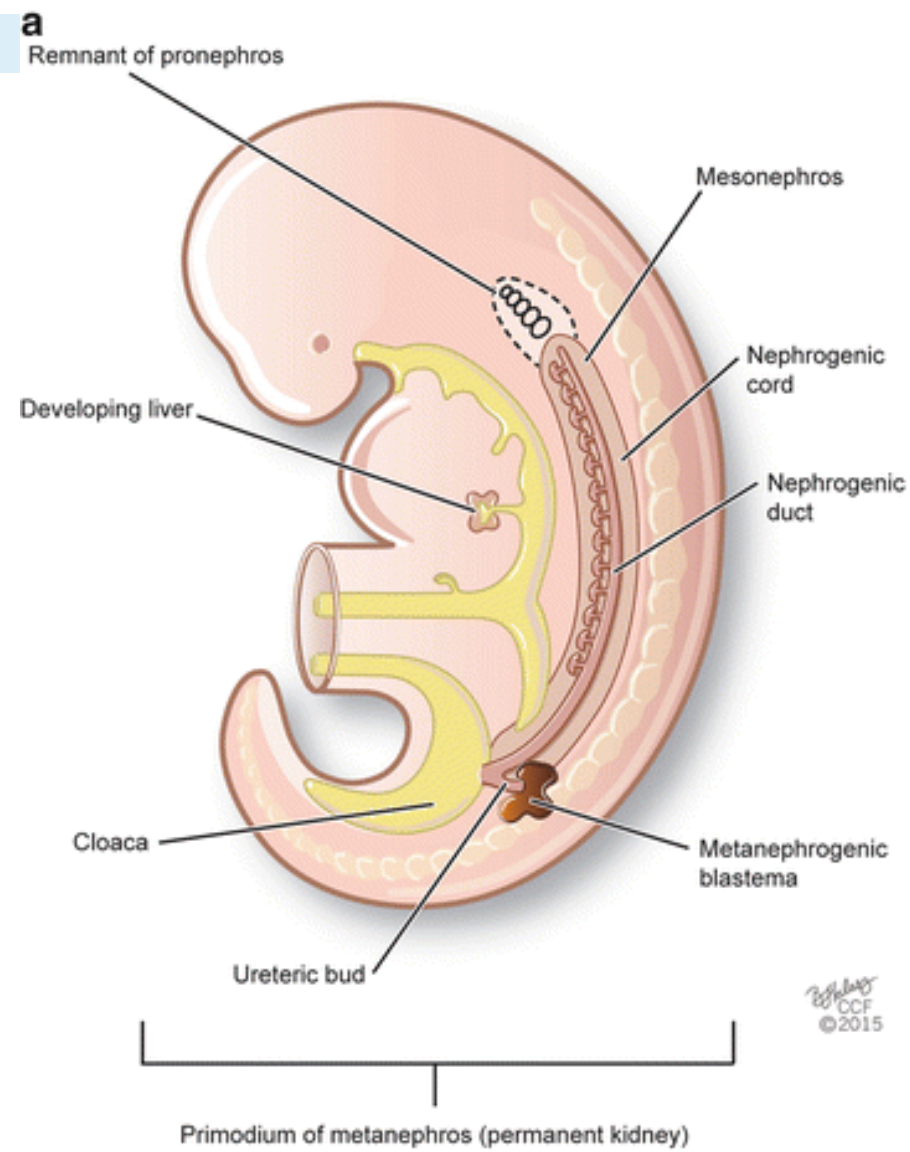






Source: Gerard M. Doherty; *CURRENT Diagnosis & Treatment: Surgery, 13th Edition*: <http://www.accessmedicine.com>  
Copyright © The McGraw-Hill Companies, Inc. All rights reserved.



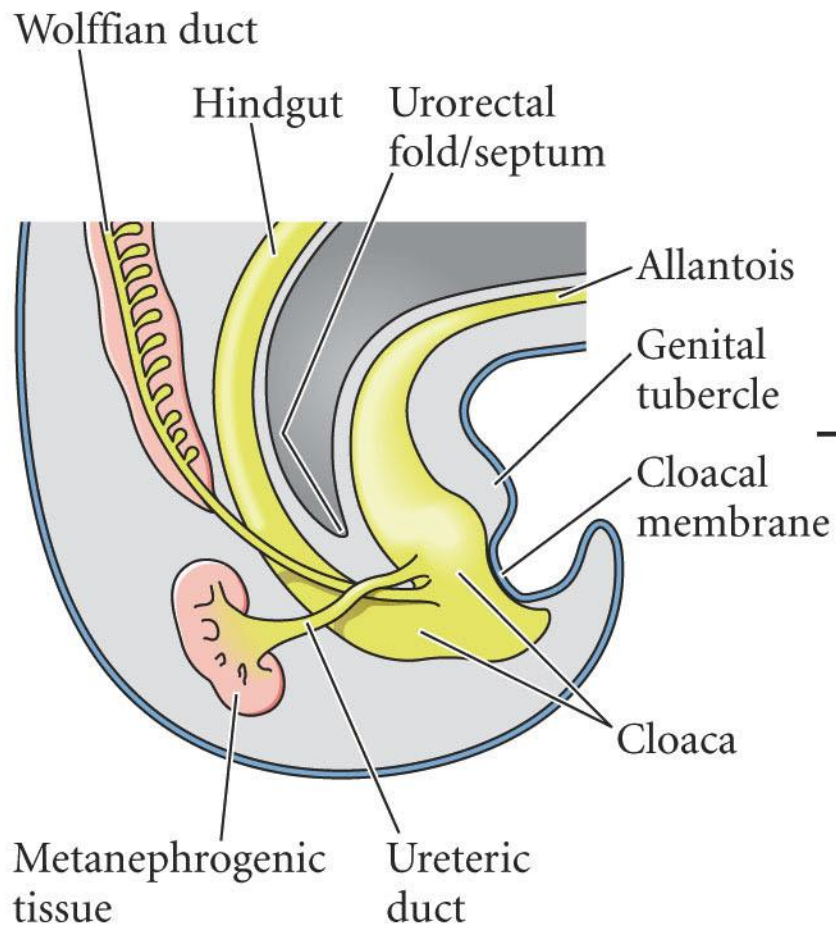


© 2015

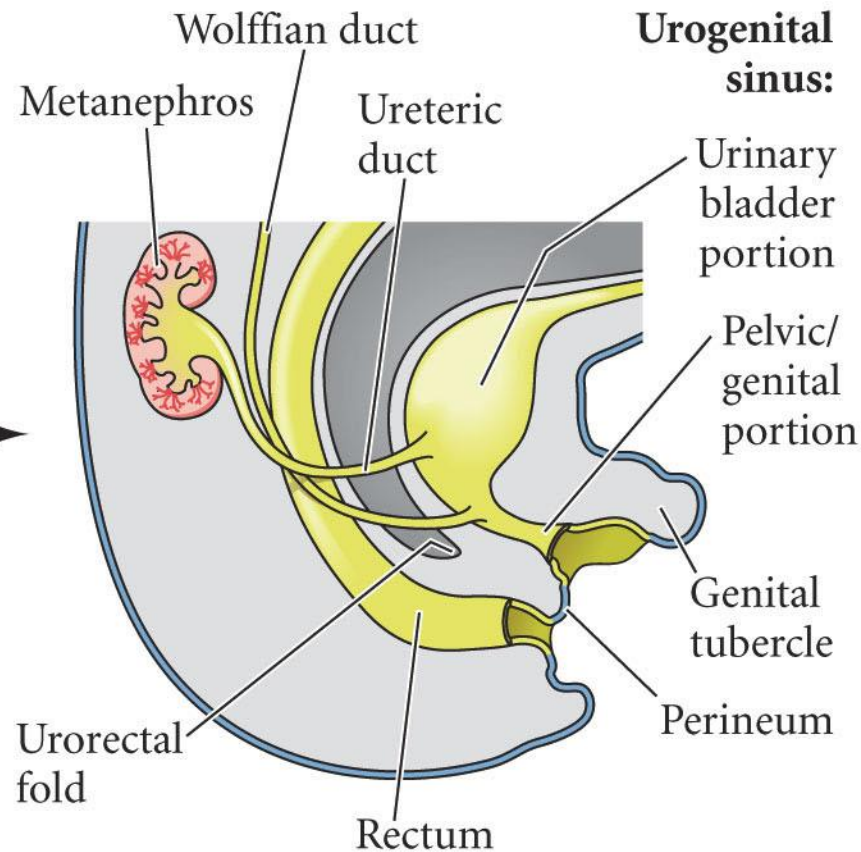
© 2015


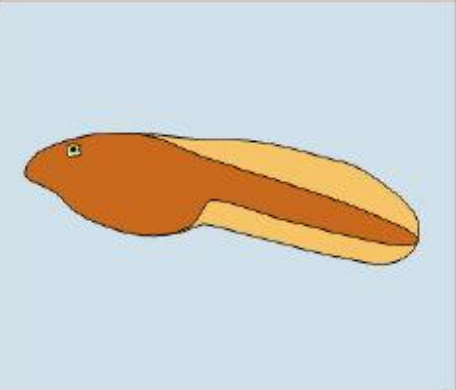


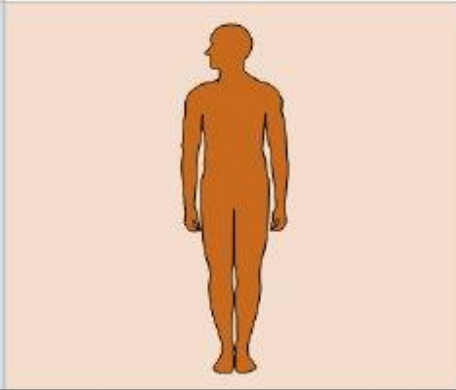


(A)

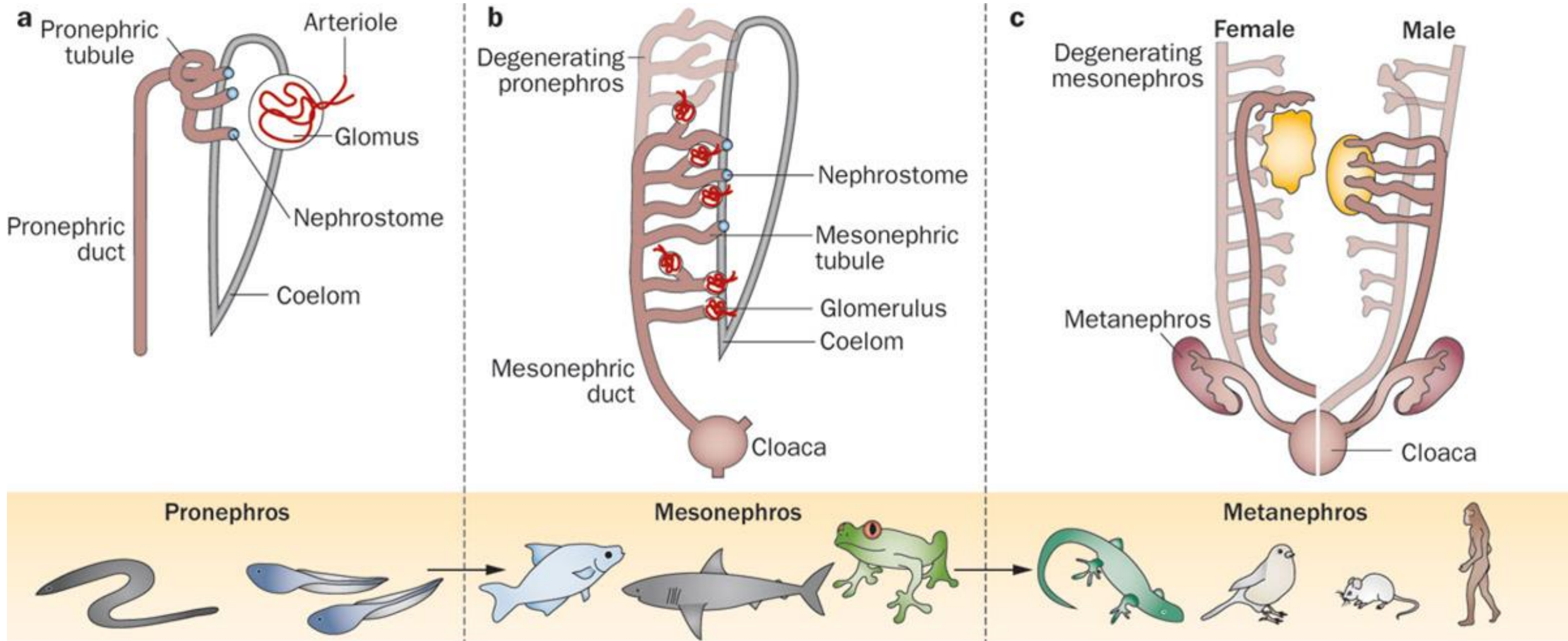


(B)

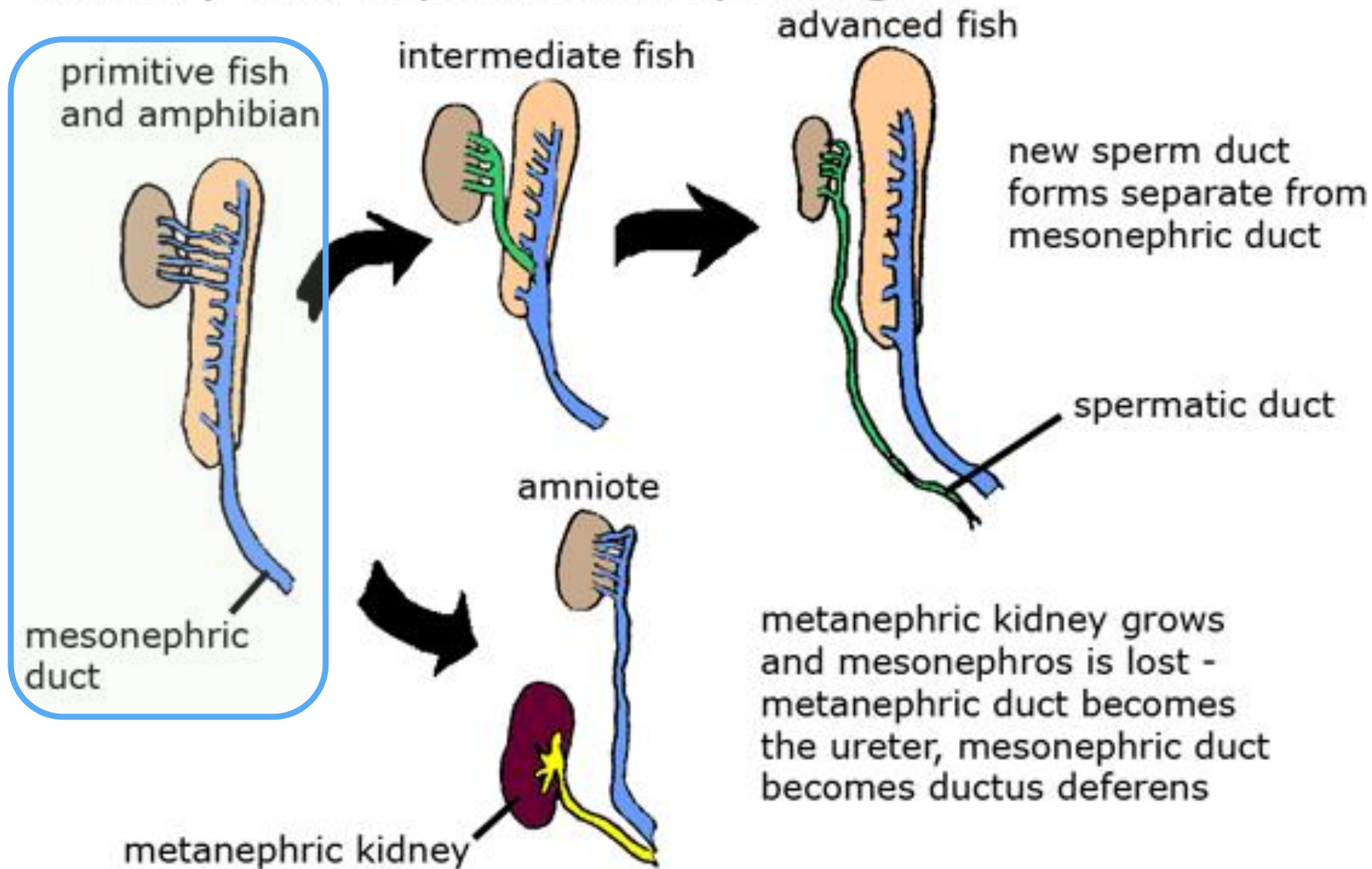


	Pronephros	Mesonephros	Metanephros
Jawless fish			
Teleosts & Anamniotes			
Amniotes			



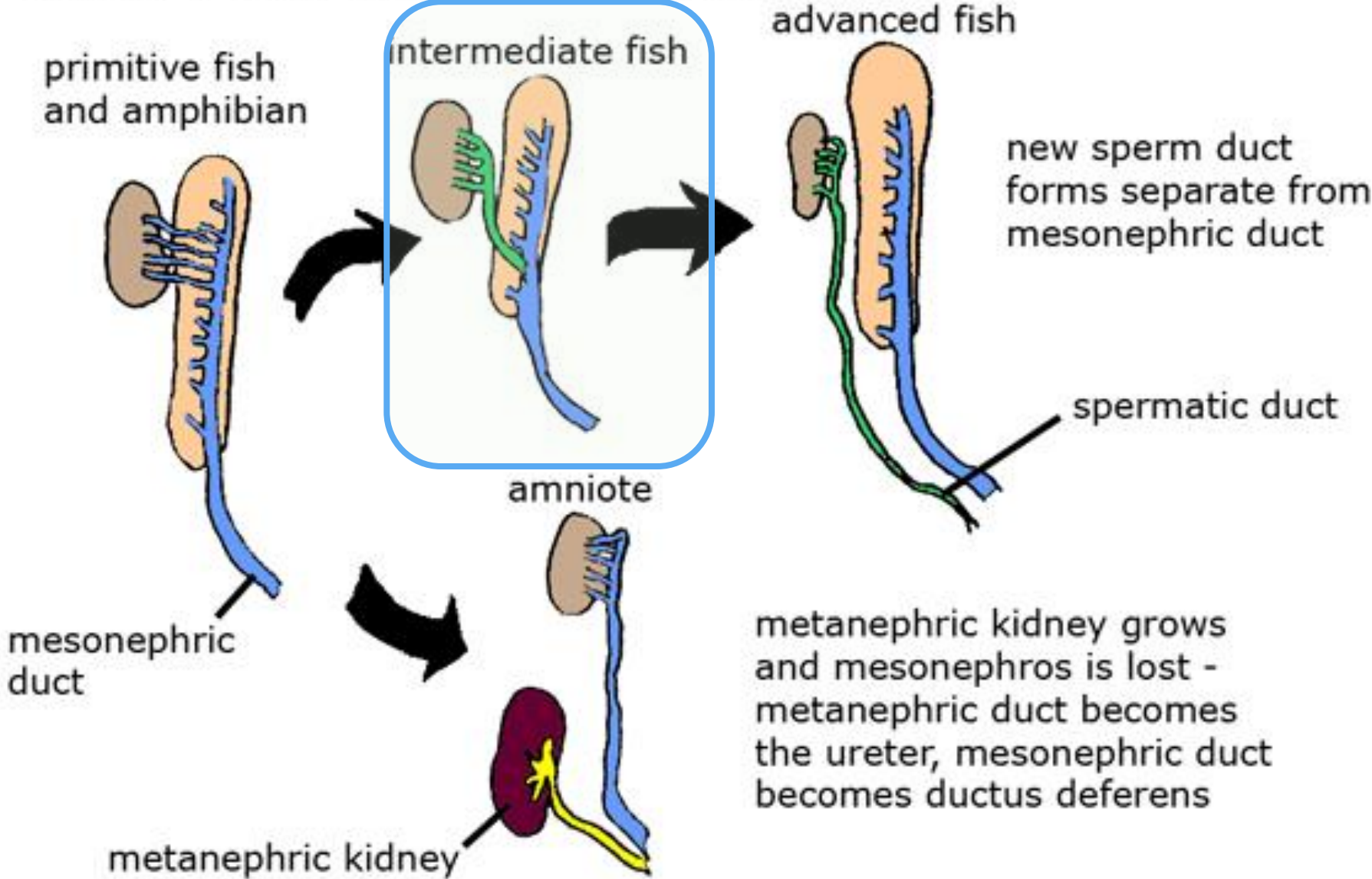


# Phylogenetic trends in the separation of the male urinary and reproductive passages

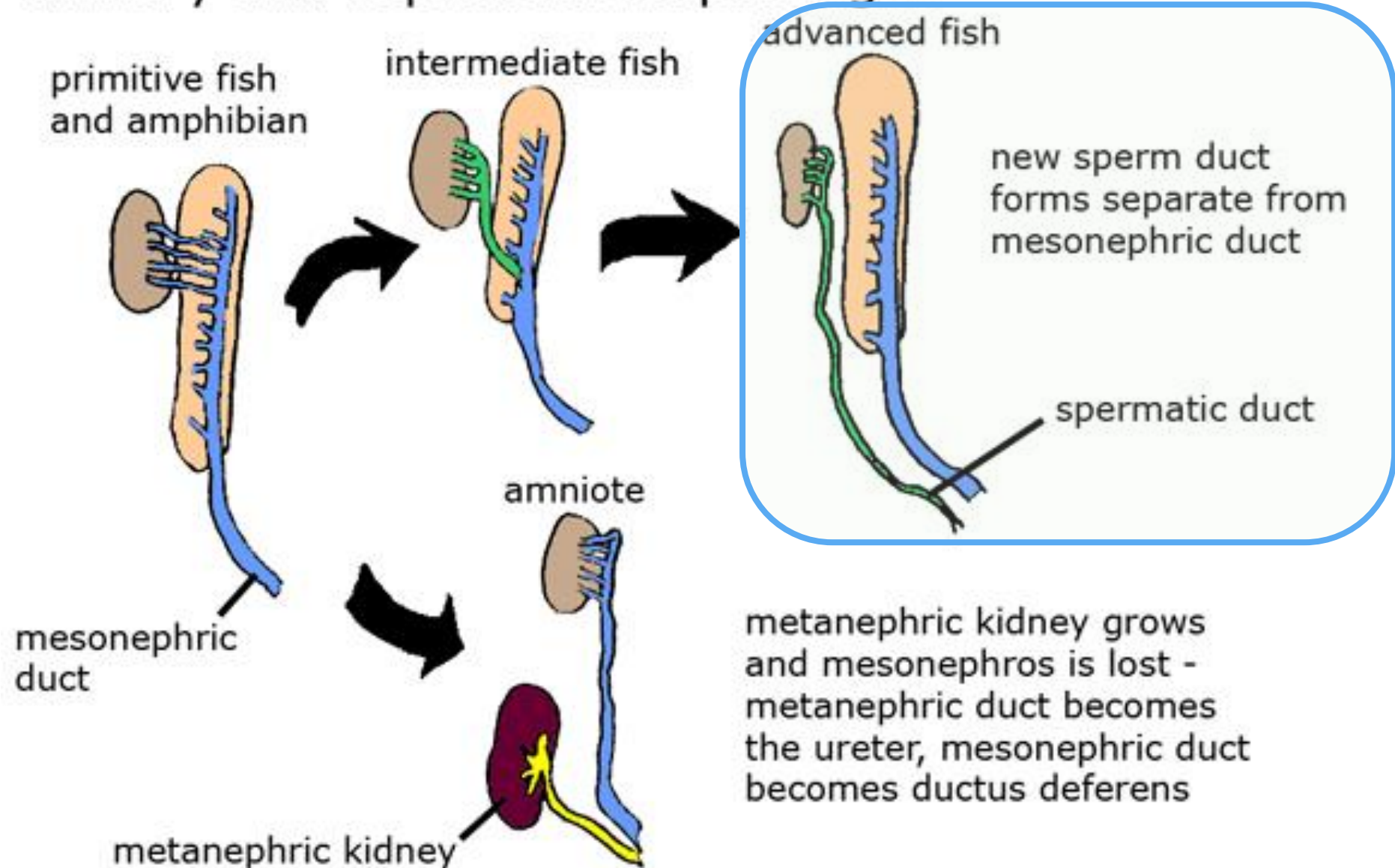




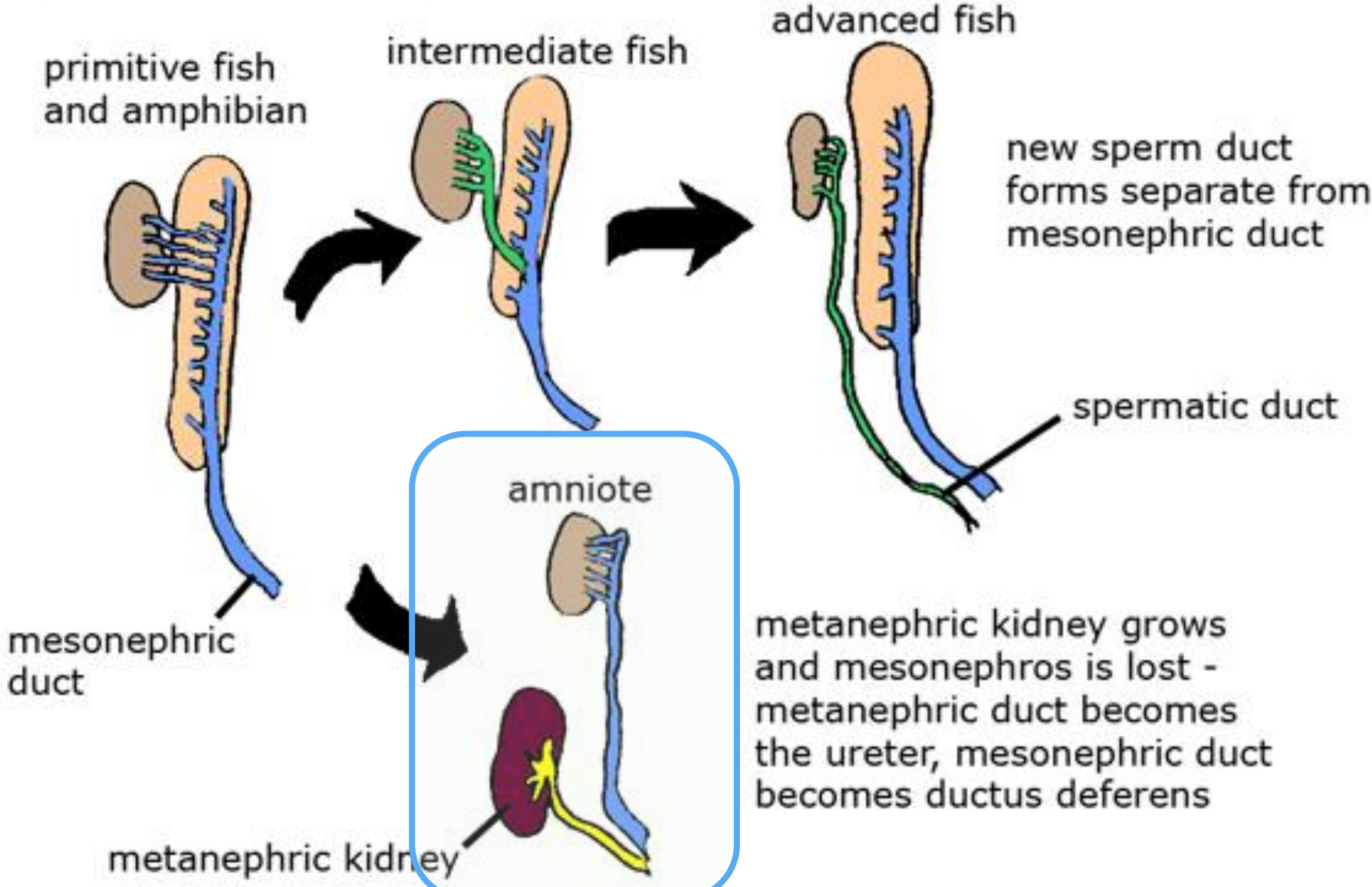
# Phylogenetic trends in the separation of the male urinary and reproductive passages



# Phylogenetic trends in the separation of the male urinary and reproductive passages

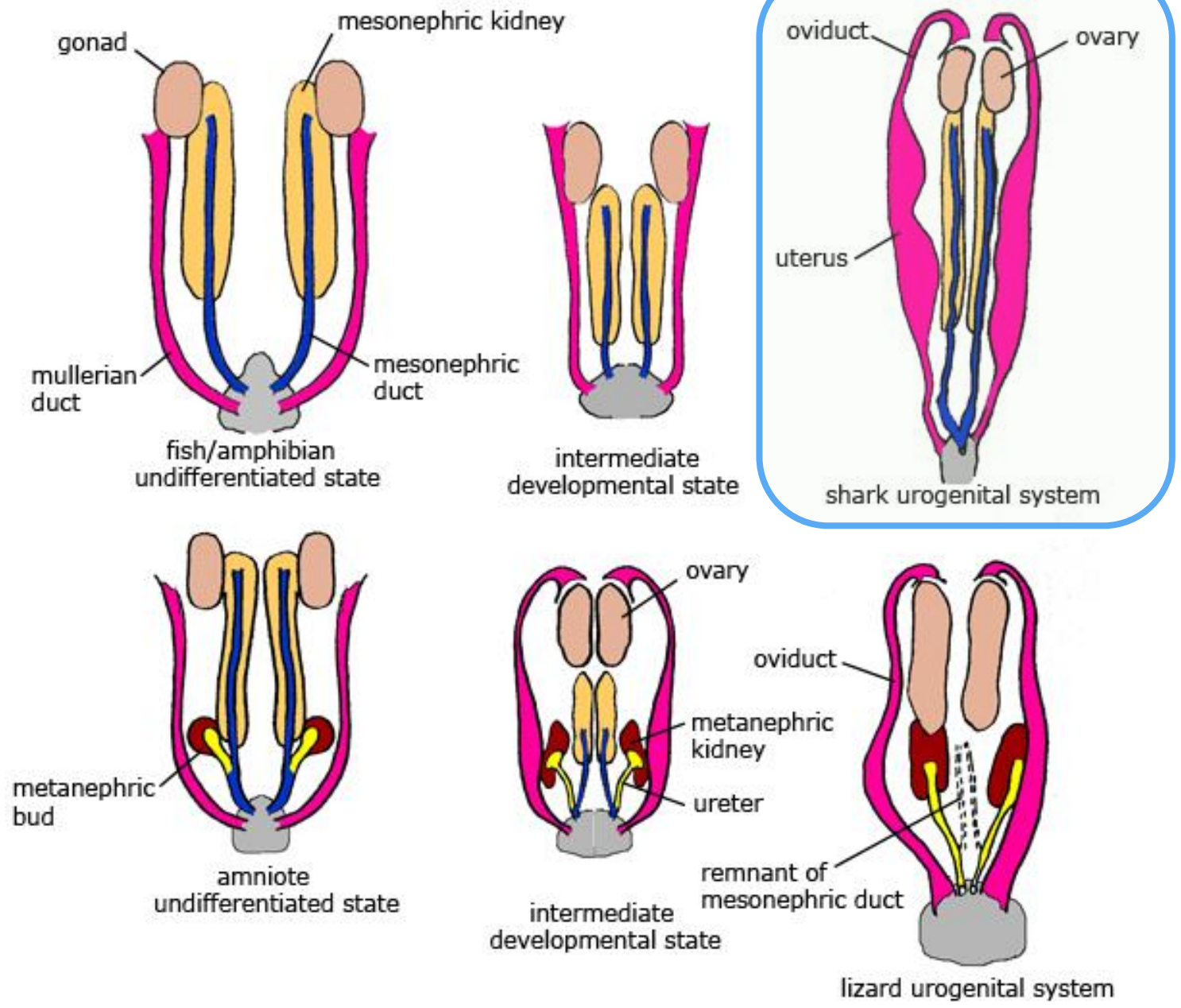


# Phylogenetic trends in the separation of the male urinary and reproductive passages



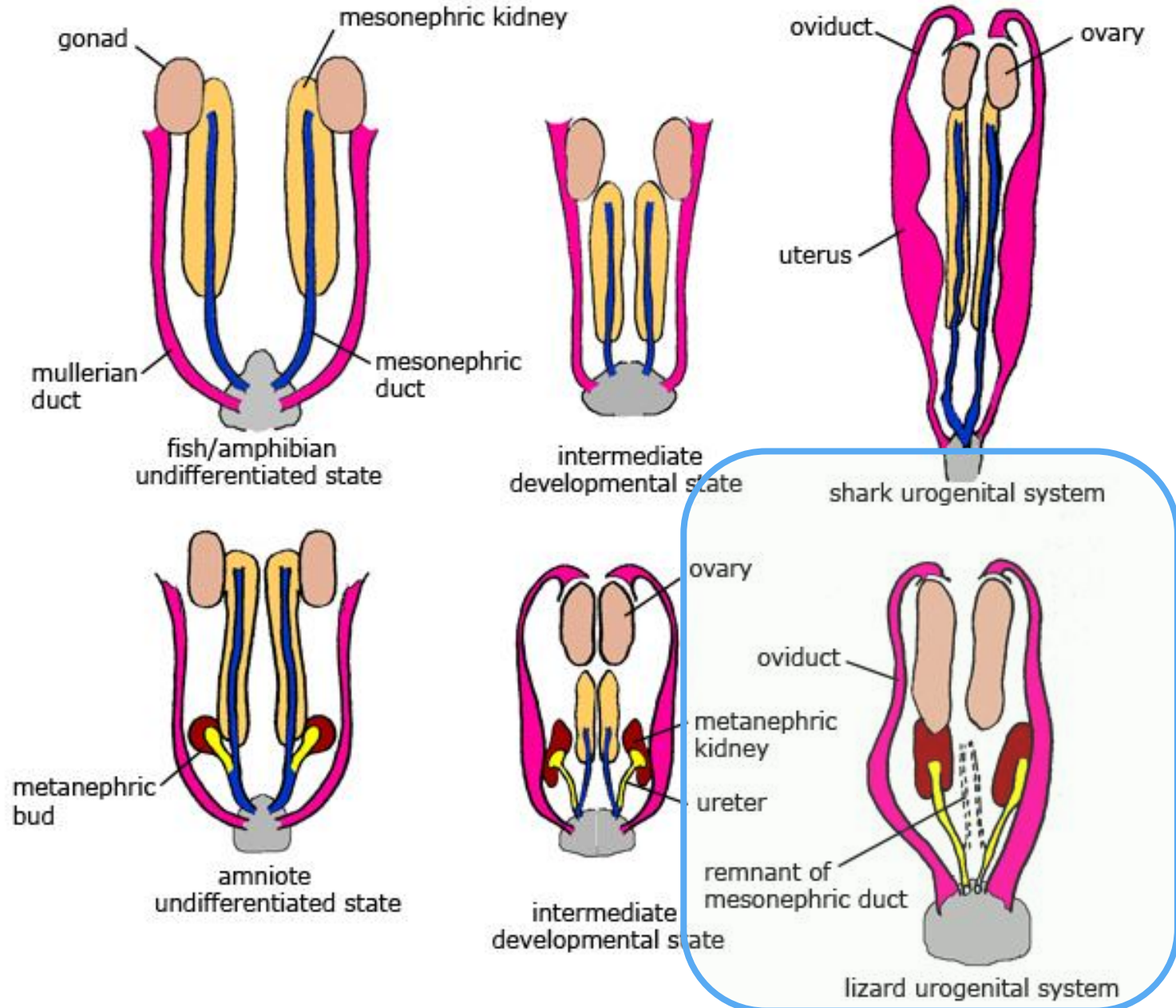
# Comparison of the development of urogenital organs in fish and amniote vertebrates

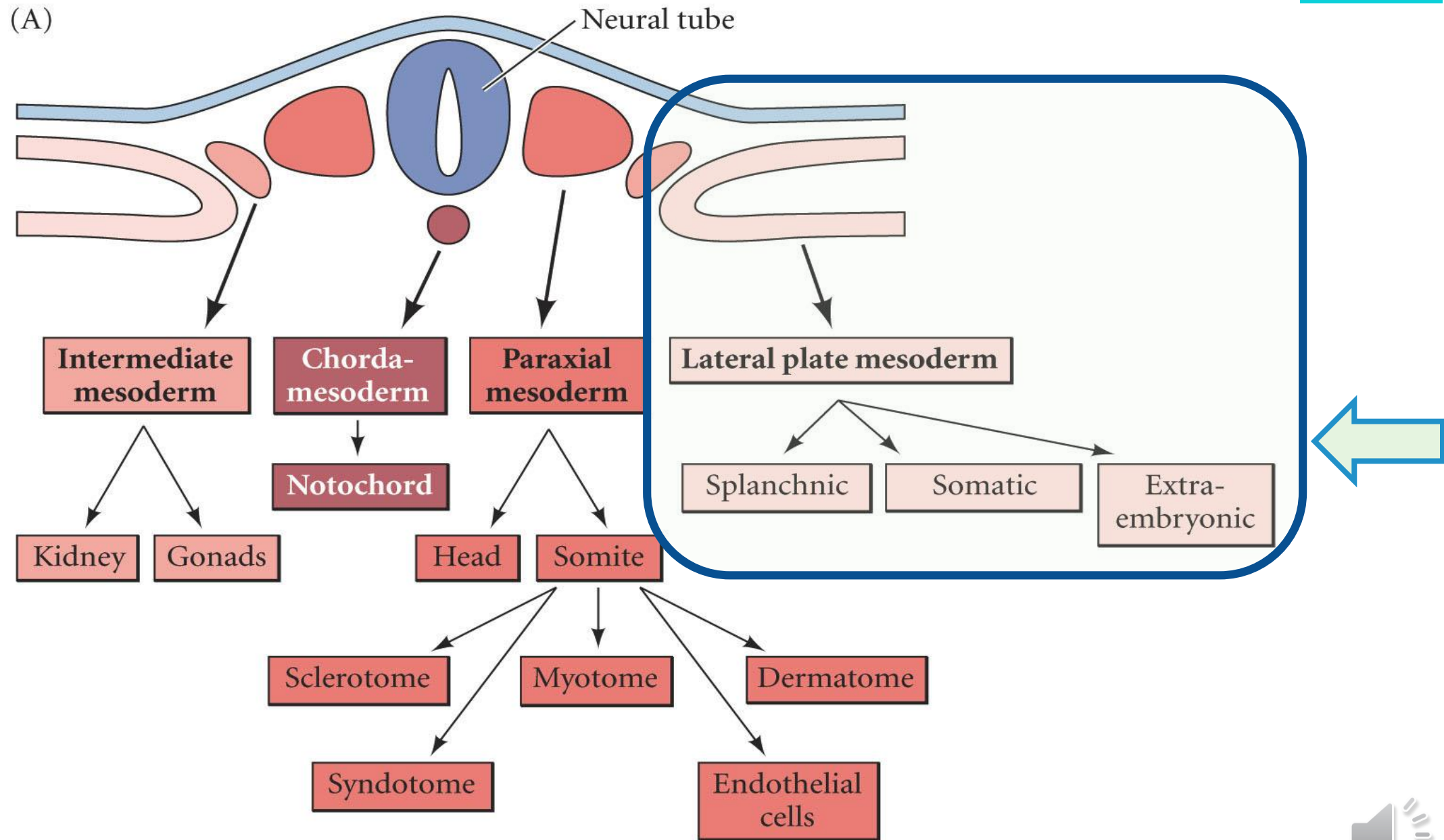
erenciación mesodérmica

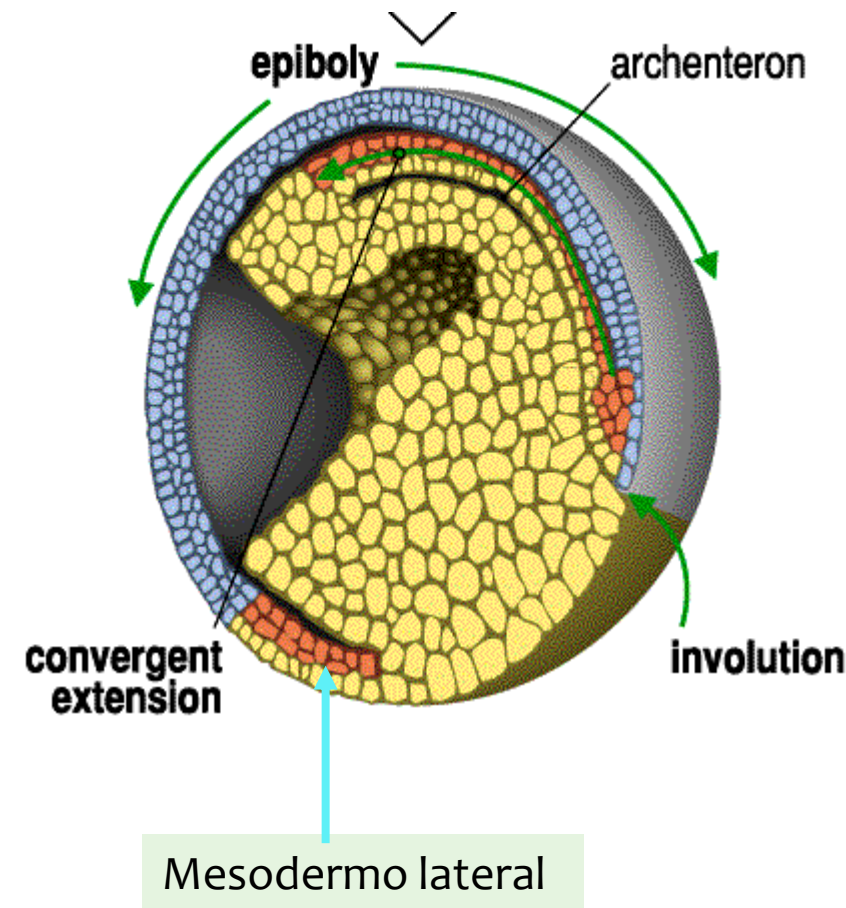
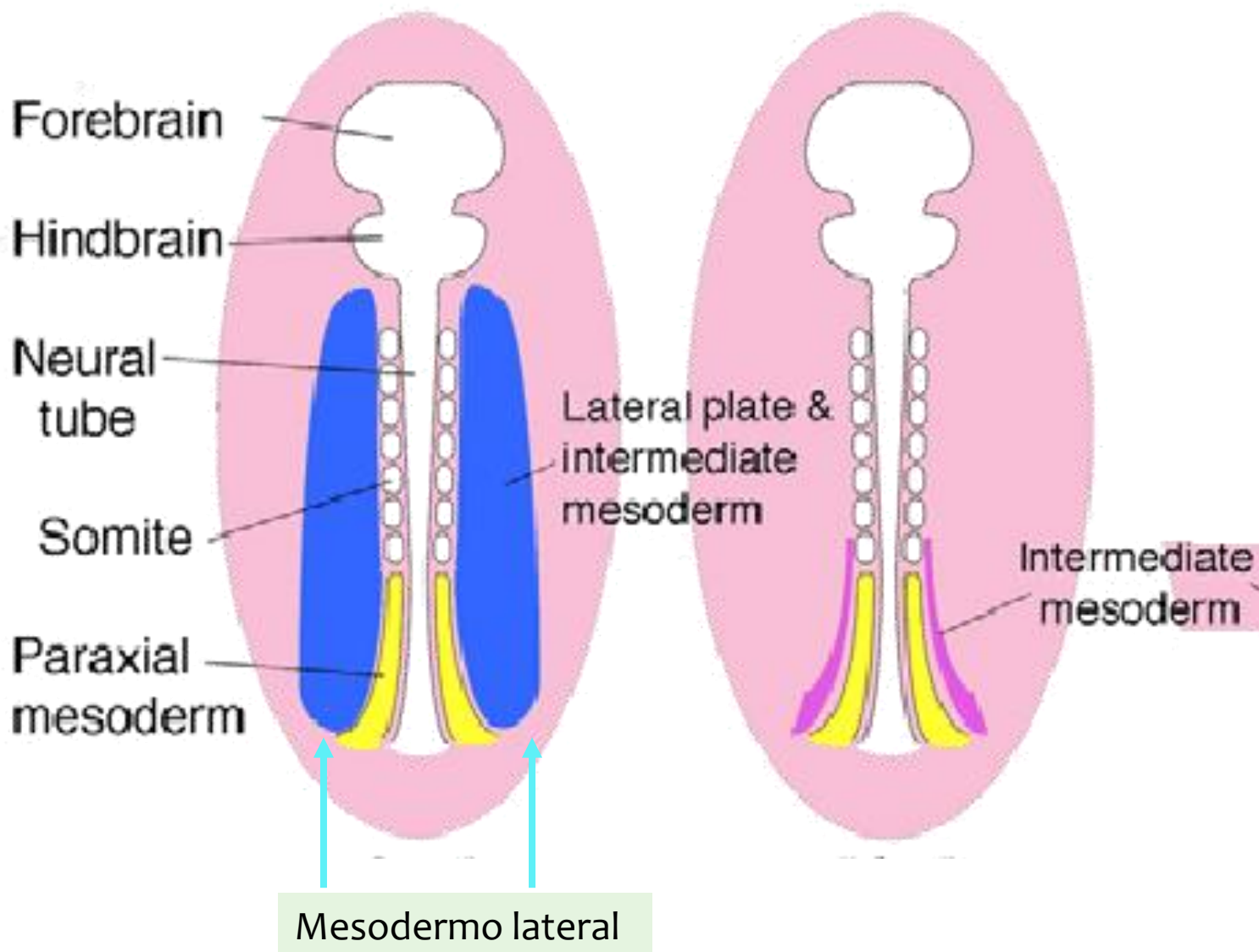


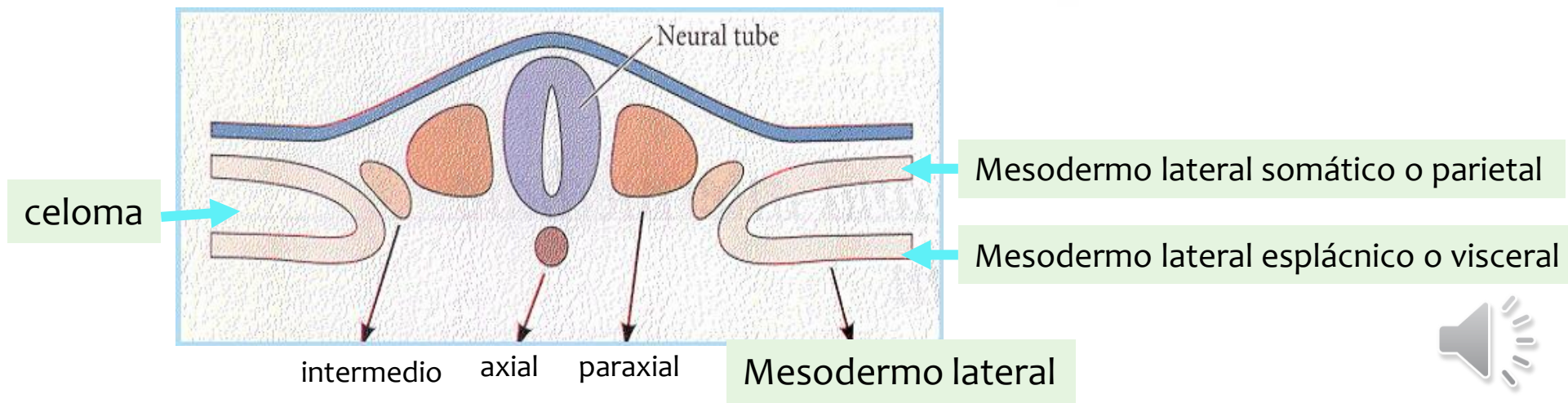
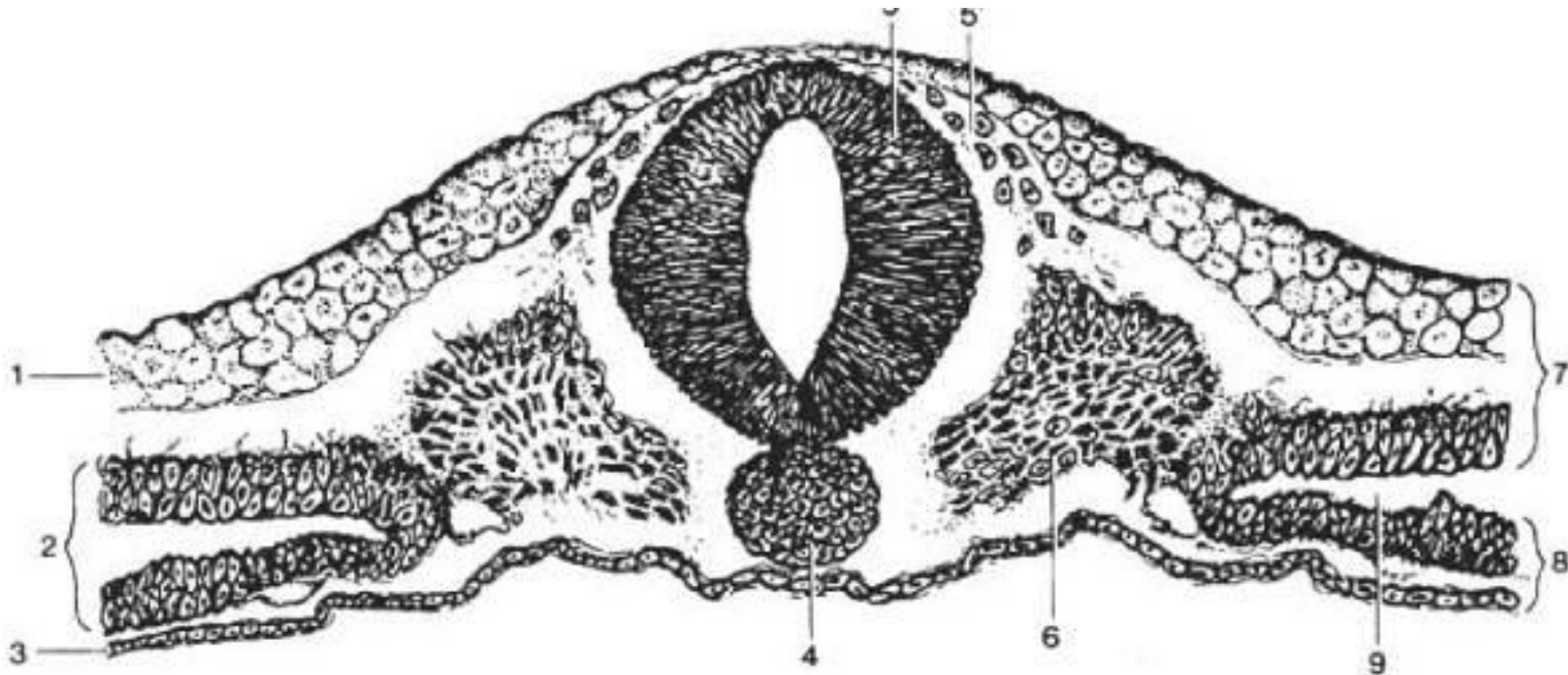
# Comparison of the development of urogenital organs in fish and amniote vertebrates

erenciación mesodérmica

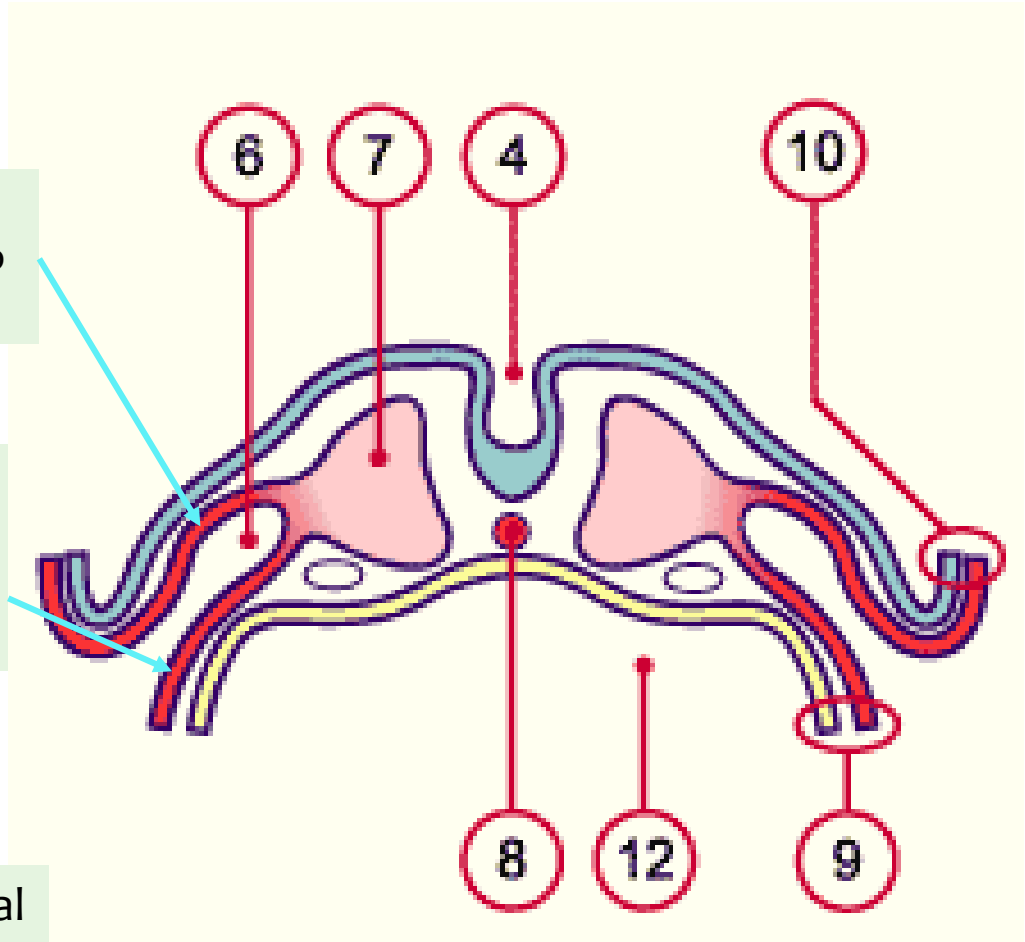
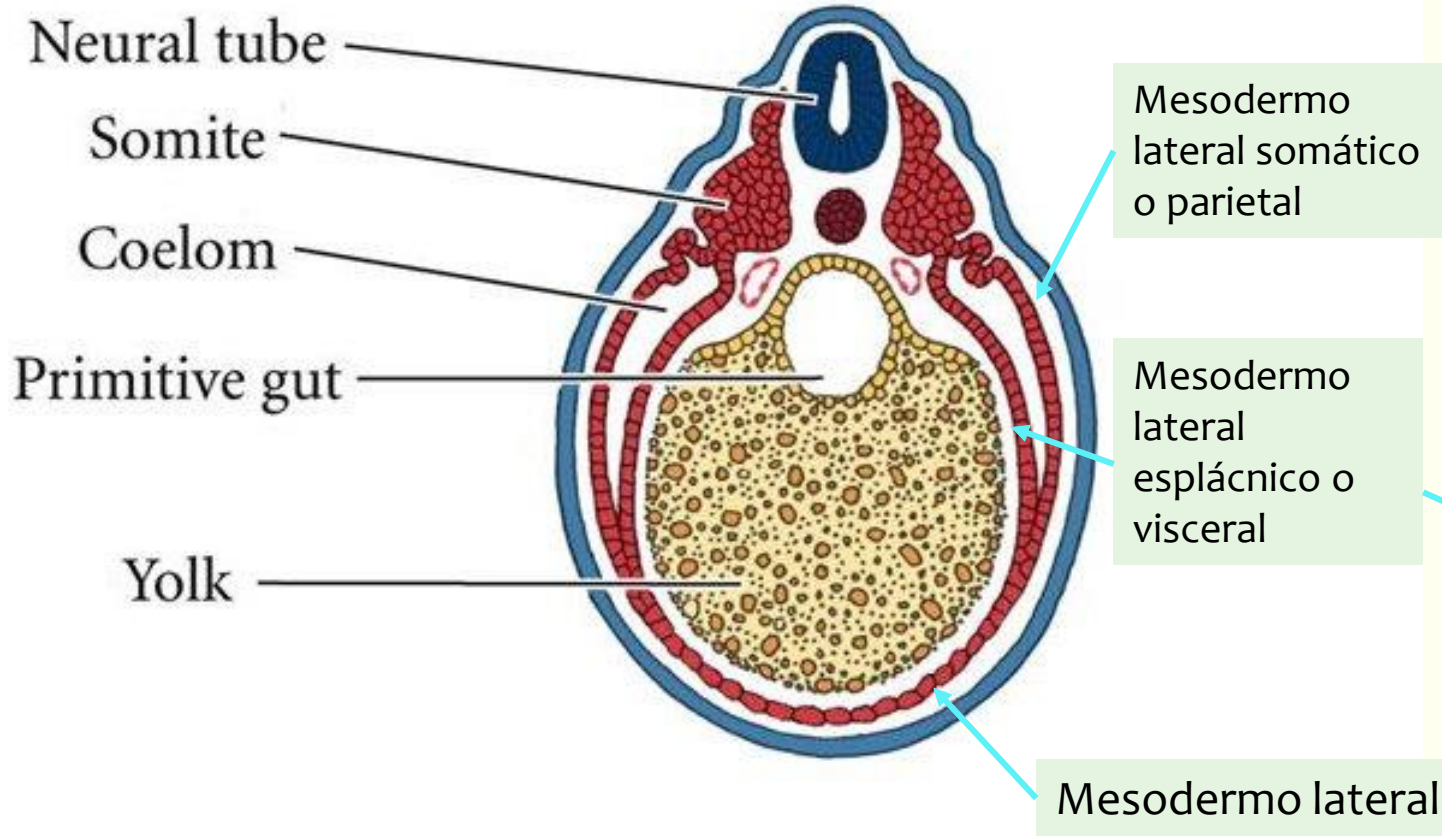








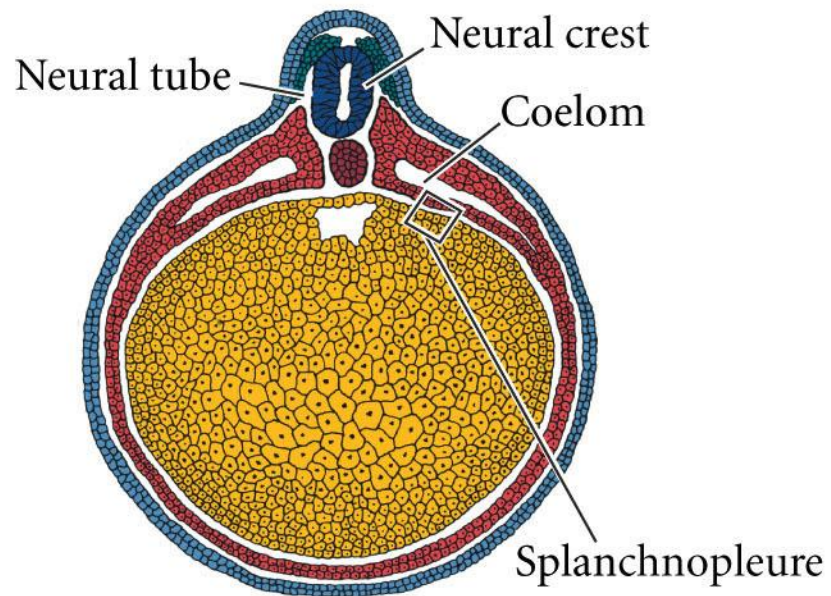
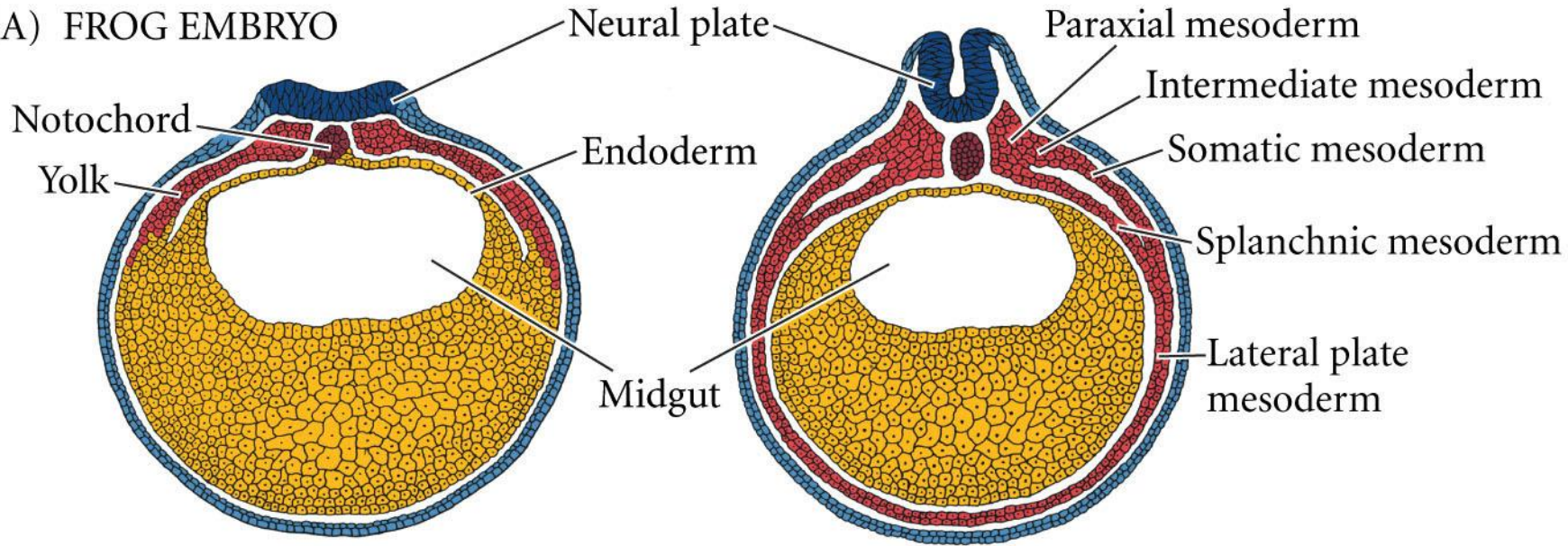




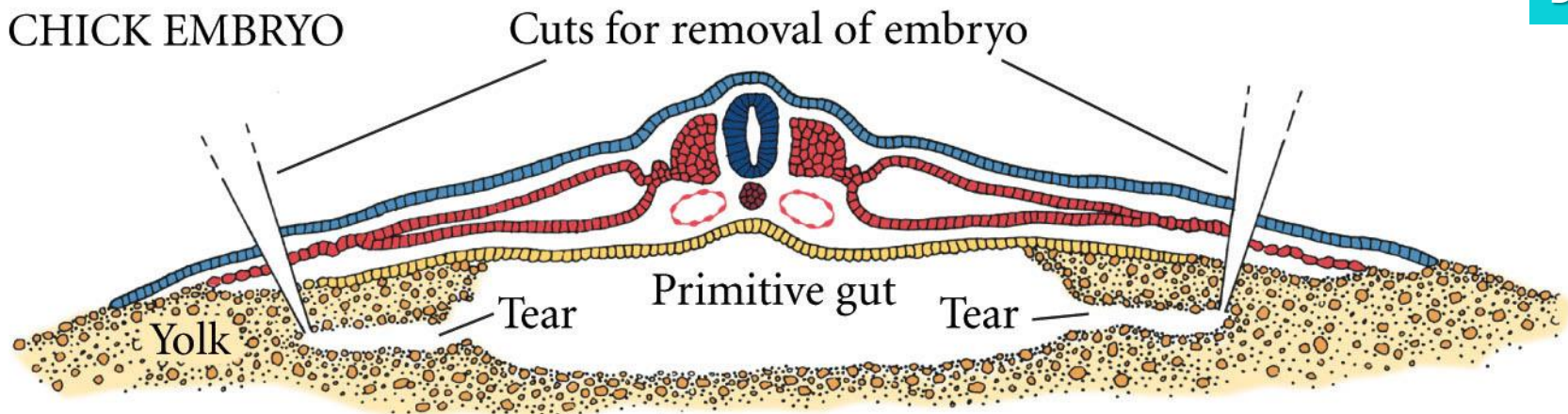
- 6. Celoma
- 7. Mesodermo paraxial
- 8. Notocorda
- 12. Intestino primitivo
- 4. Surco neural
- 9. Esplacnopleura
- 10. Somatopleura



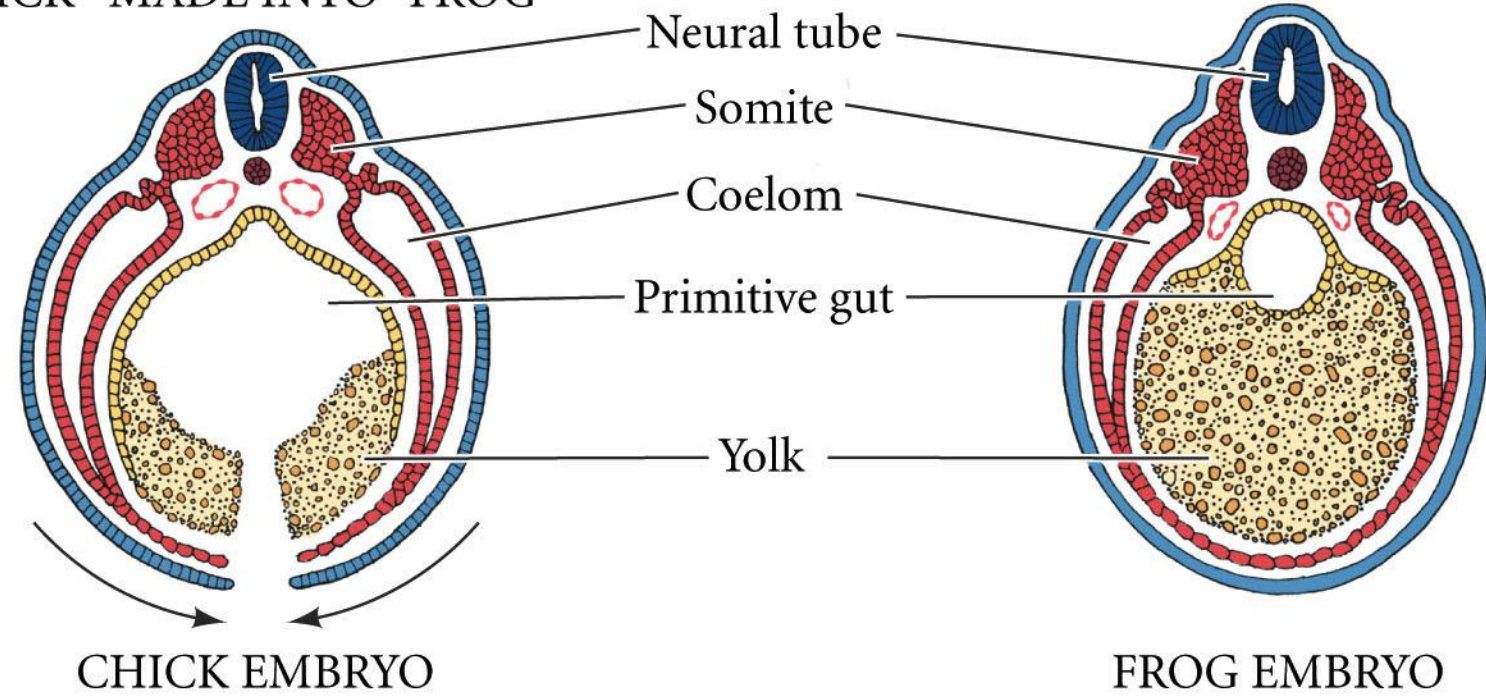
(A) FROG EMBRYO



(B) CHICK EMBRYO



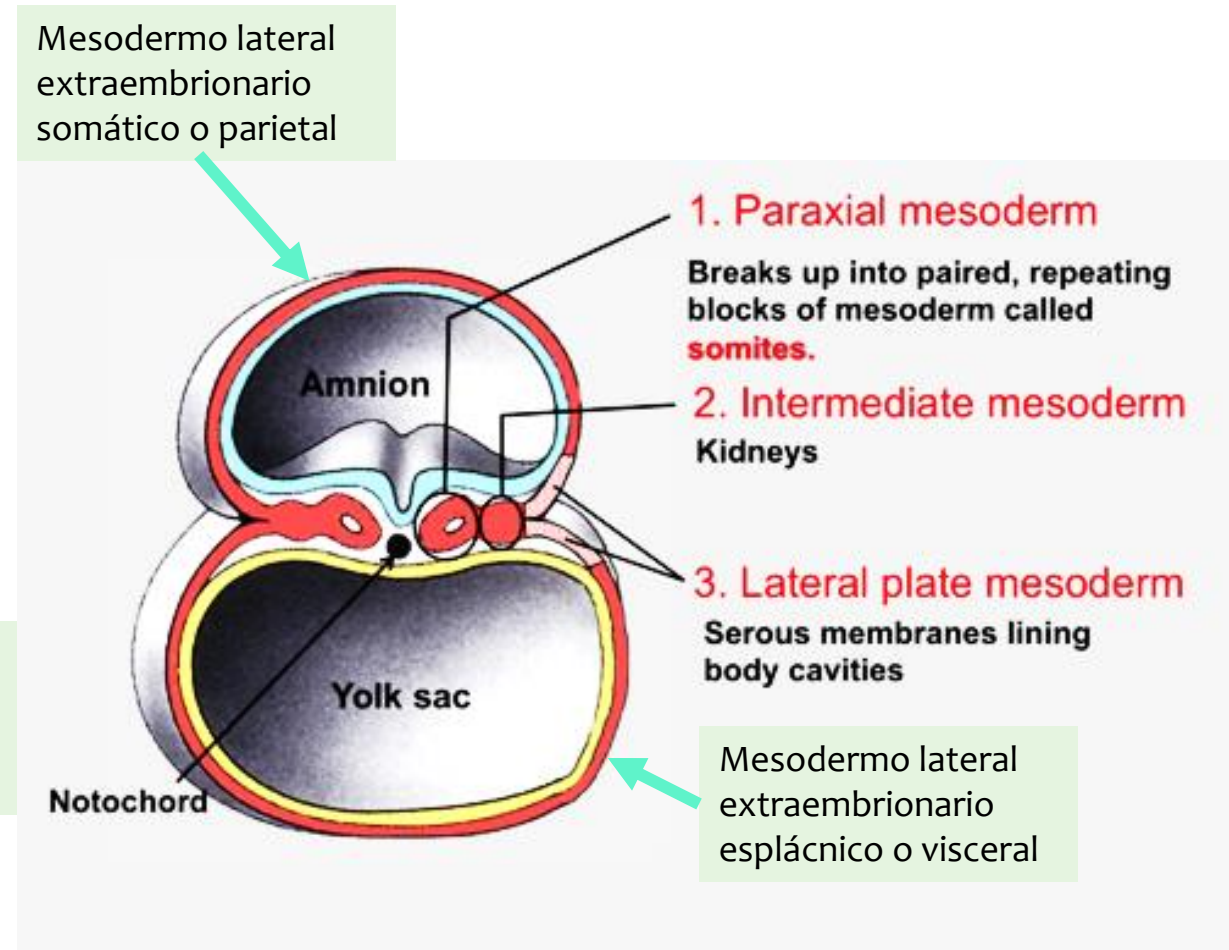
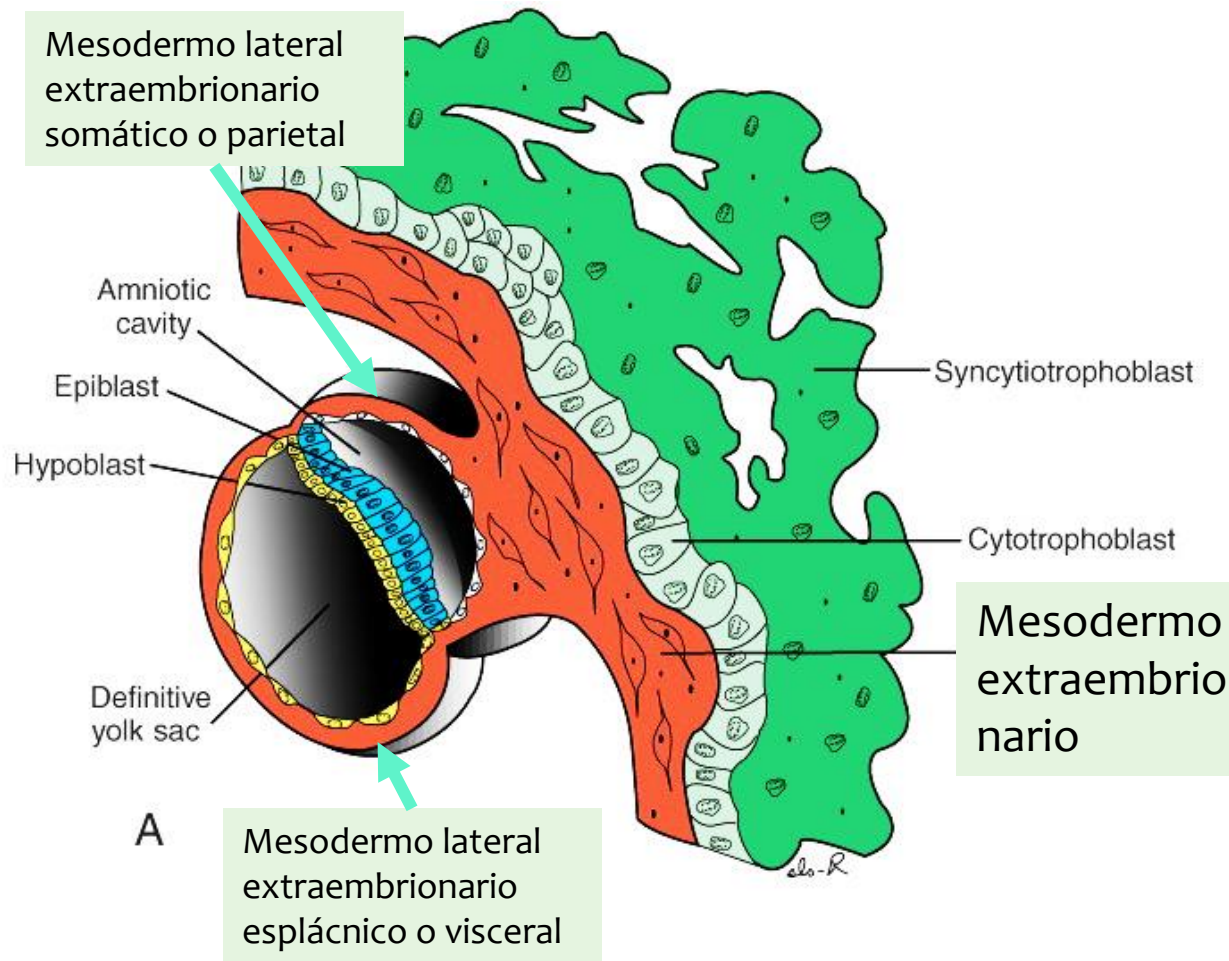
(C) CHICK "MADE INTO" FROG

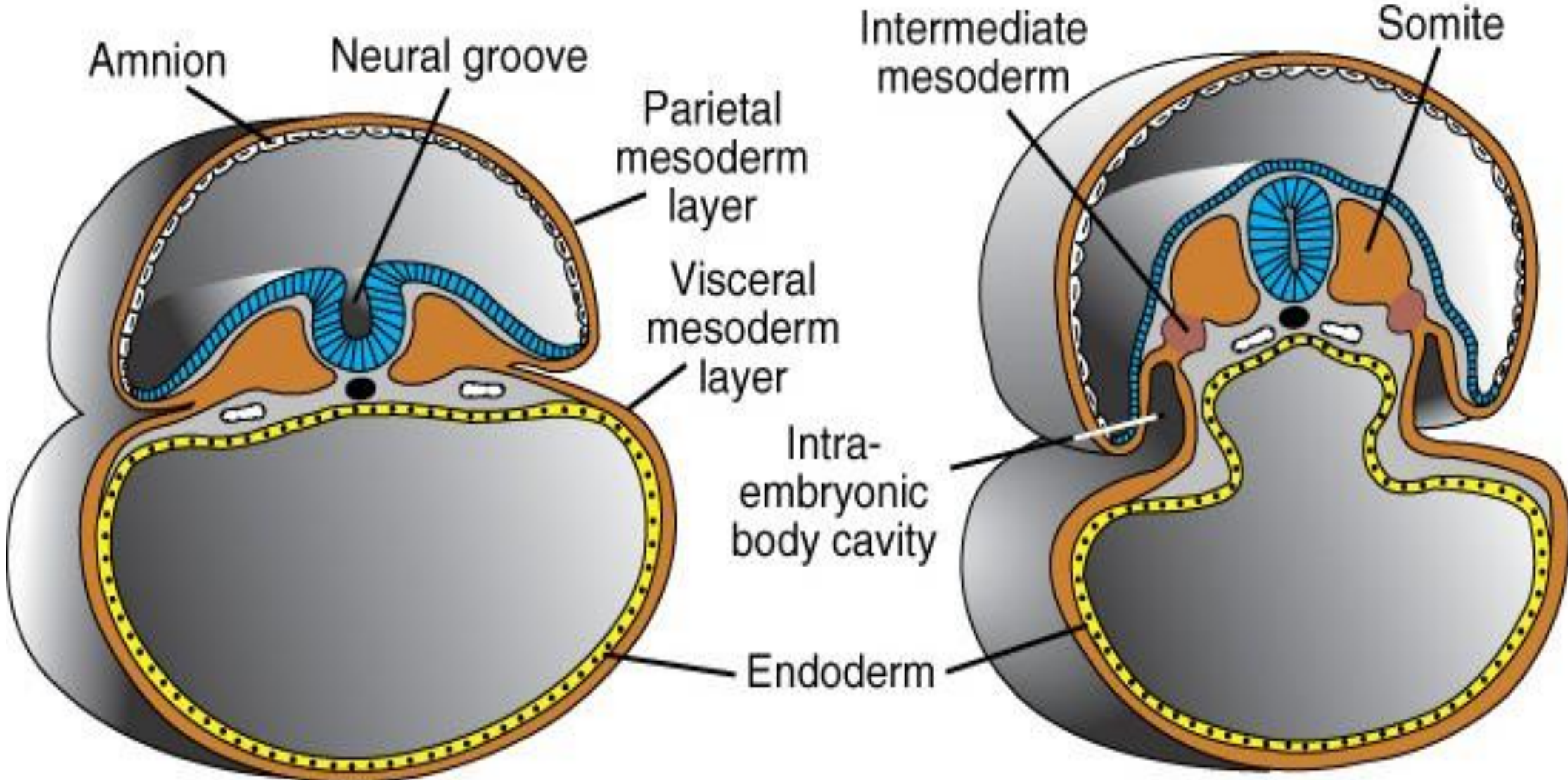


CHICK EMBRYO

FROG EMBRYO







## Esplácnico

- Tejido conjuntivo y muscular de todas las vísceras
- Cartílago de tráquea y árbol bronquial
- Hoja visceral de peritoneo, pleuras y pericardio
- Todo el sistema cardiovascular
- Órganos linfáticos y bazo

## Somático

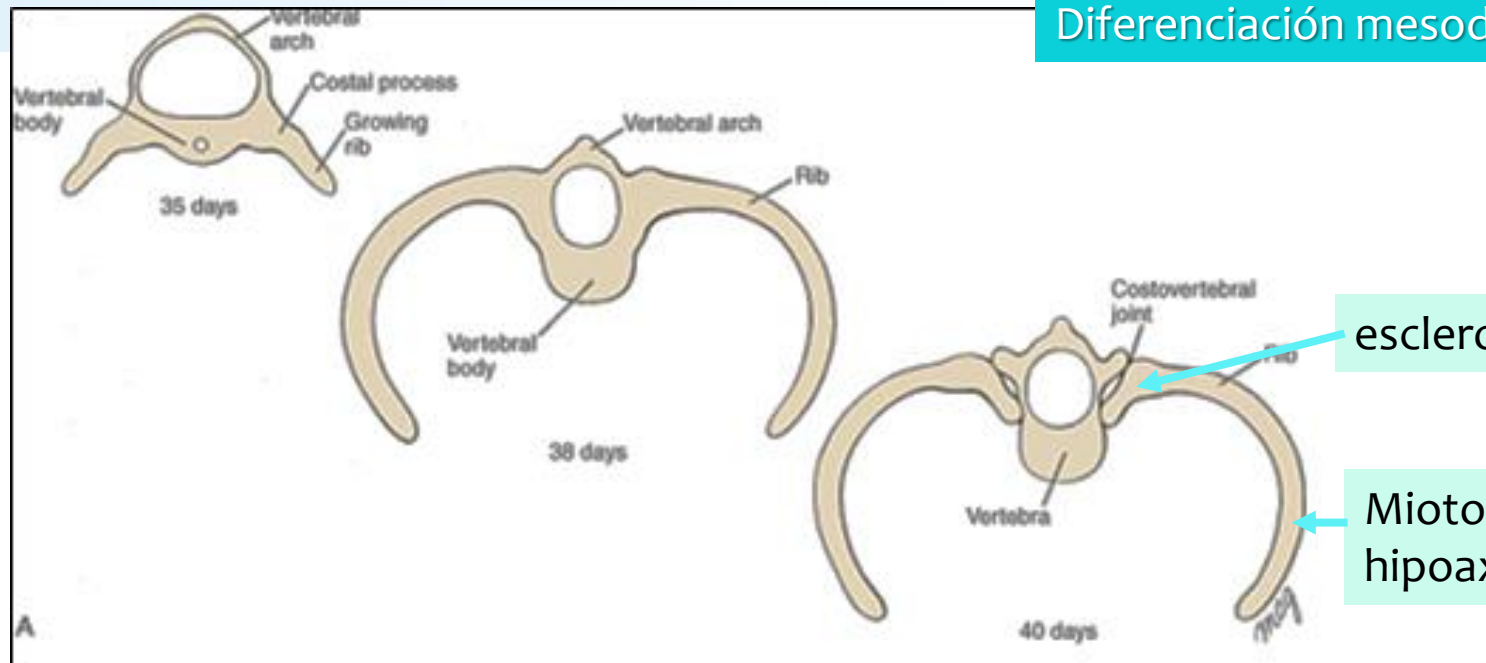
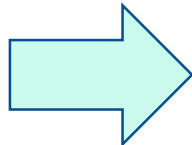
- Esternón
- Esqueleto de los miembros
- Hoja parietal de peritoneo, pleuras y pericardio



# Somático

Esternón

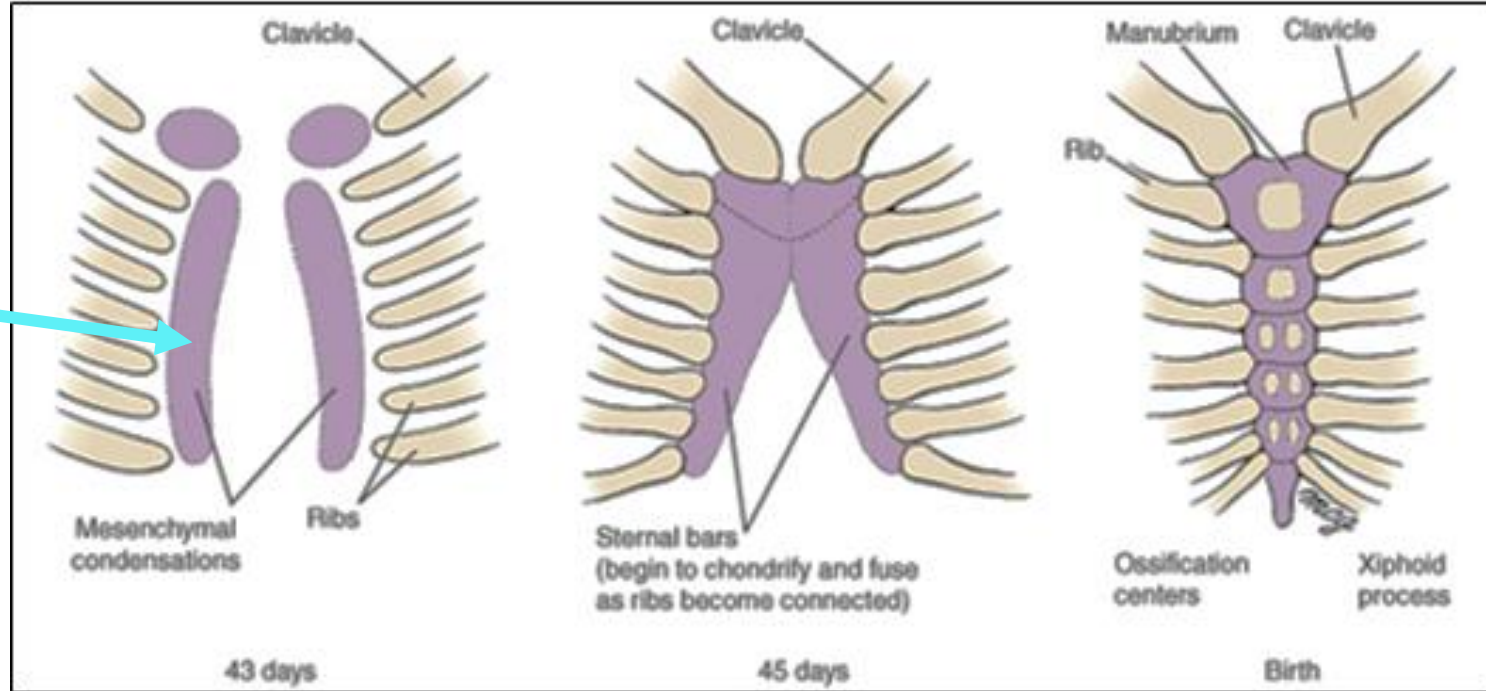
Esqueleto de los miembros



esclerotomo

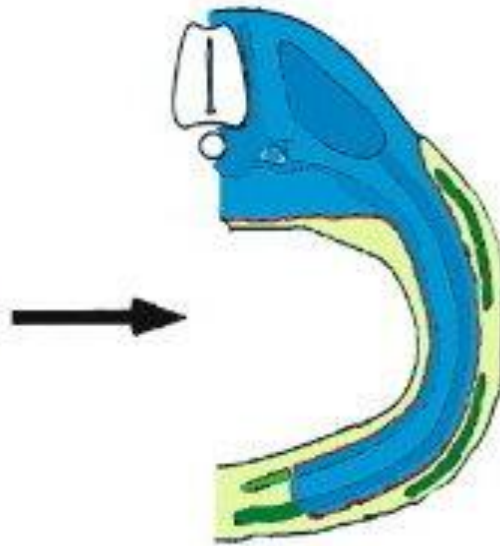
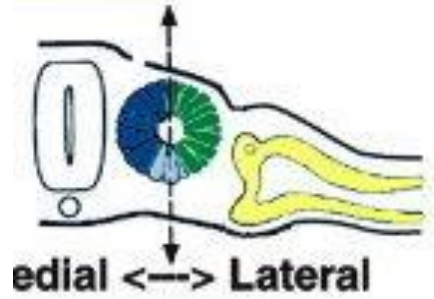
Miotomo, hipoaxial

Mesodermo lateral somático



### D amniote

 Somite  
Lateral Plate



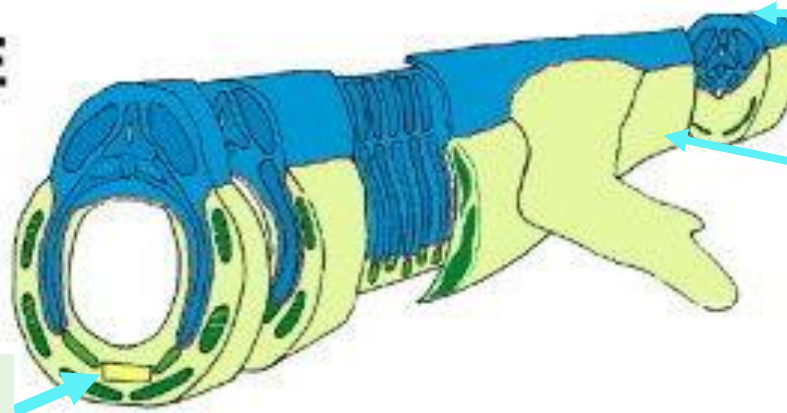
Primaxial

Abaxial

Somático

- Esternón
- Esqueleto de los miembros

### E



Mesodemo paraxial

Mesodemo lateral

esternón



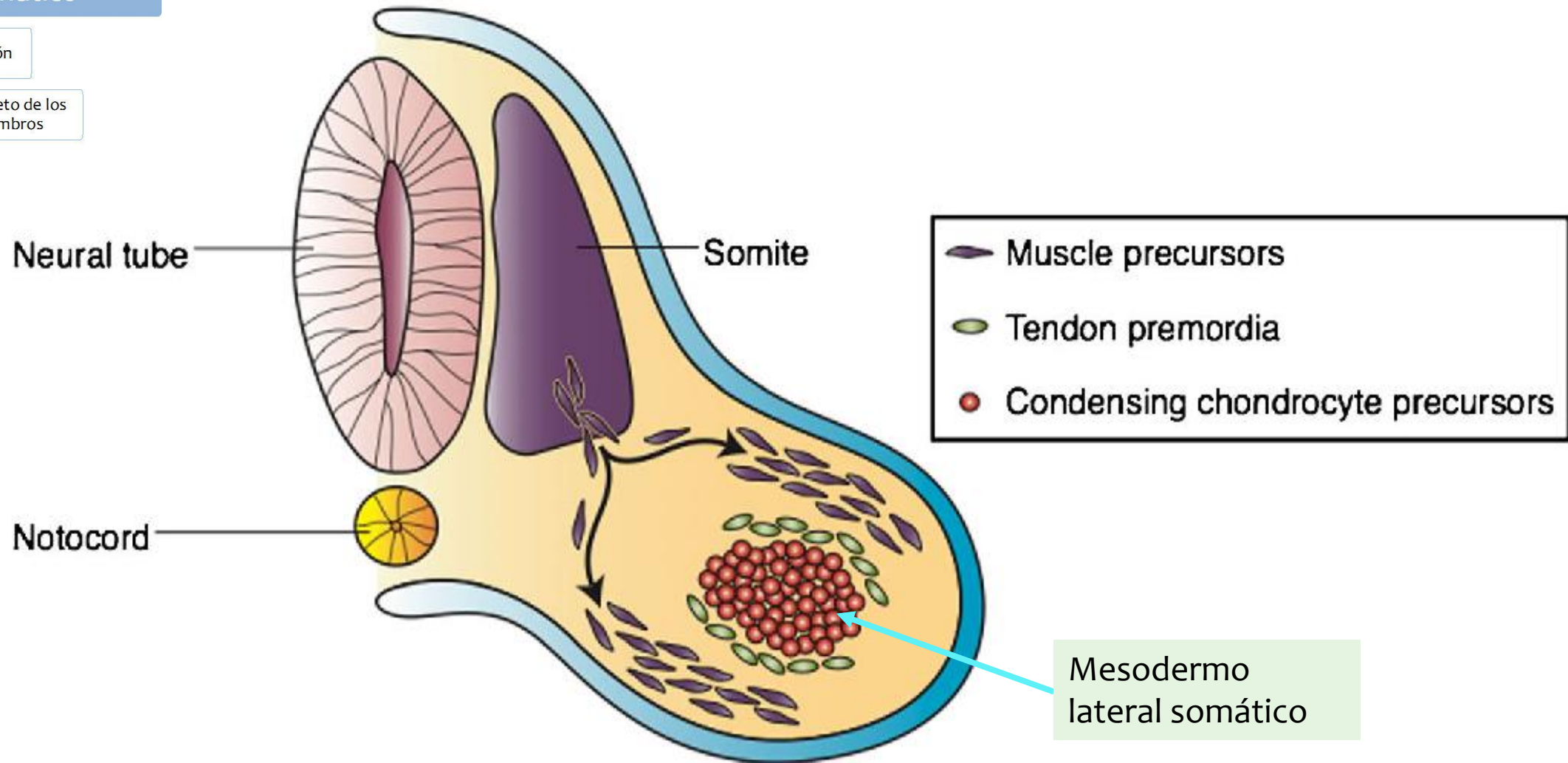
Lateral Somitic Frontier

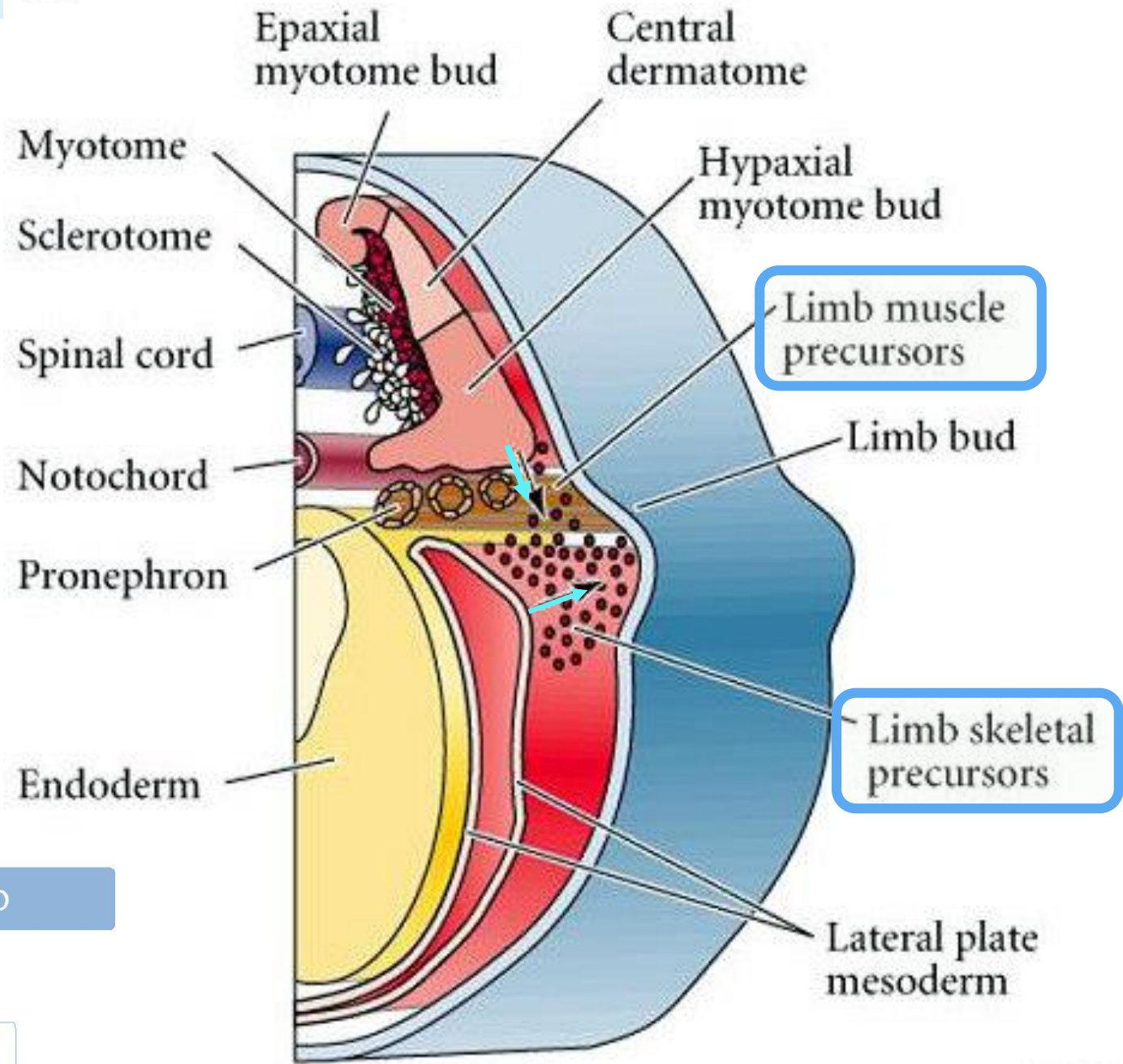




Somático

- Esternón
- Esqueleto de los miembros





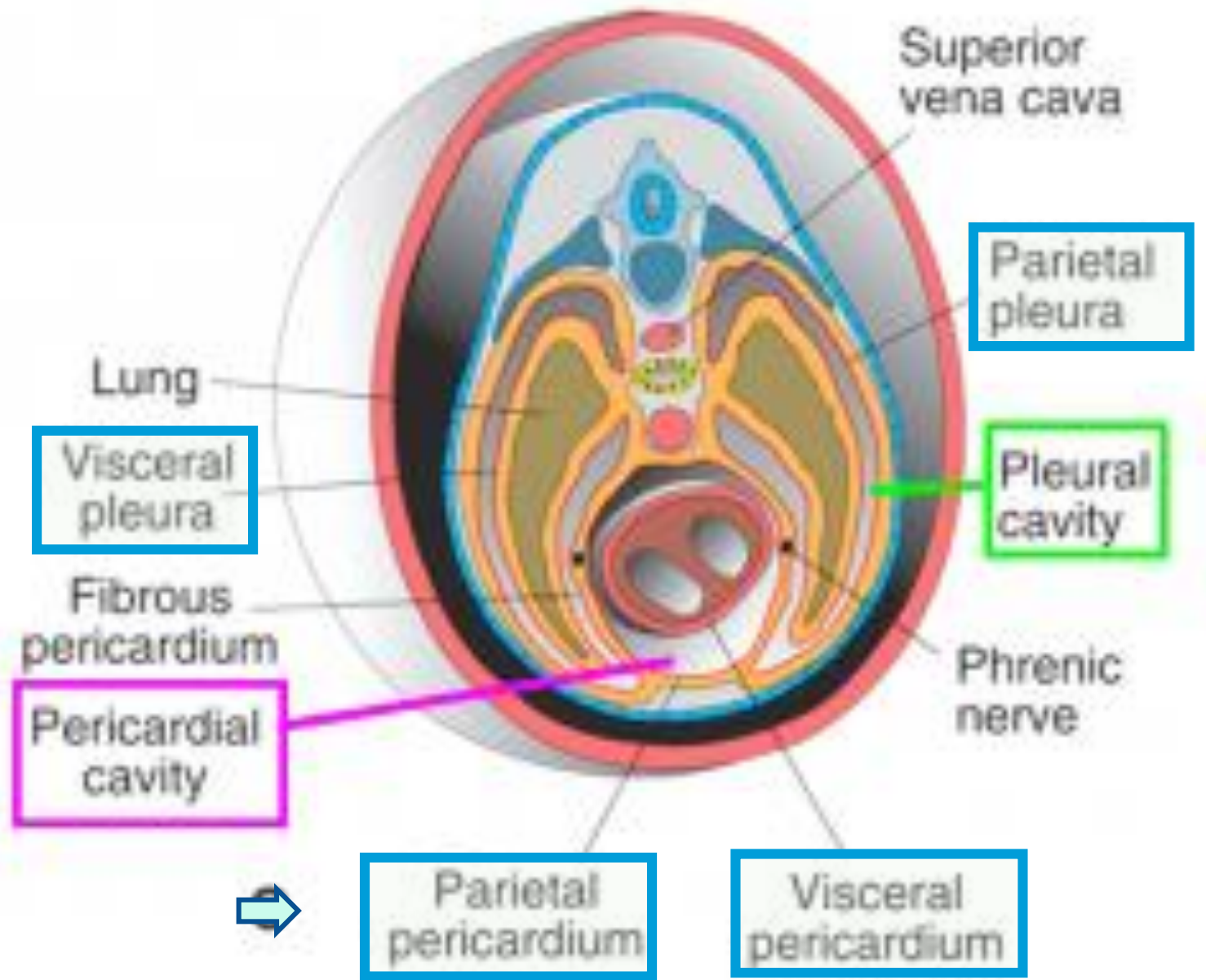
Dorsal mesoderm (somitic)  
Induces rFng Wnt 7a in dorsal Limb bud.

Ventral mesoderm (lat. Plate)  
Induces en-1 in ventral limb bud

Somático

- Esternón
- Esqueleto de los miembros

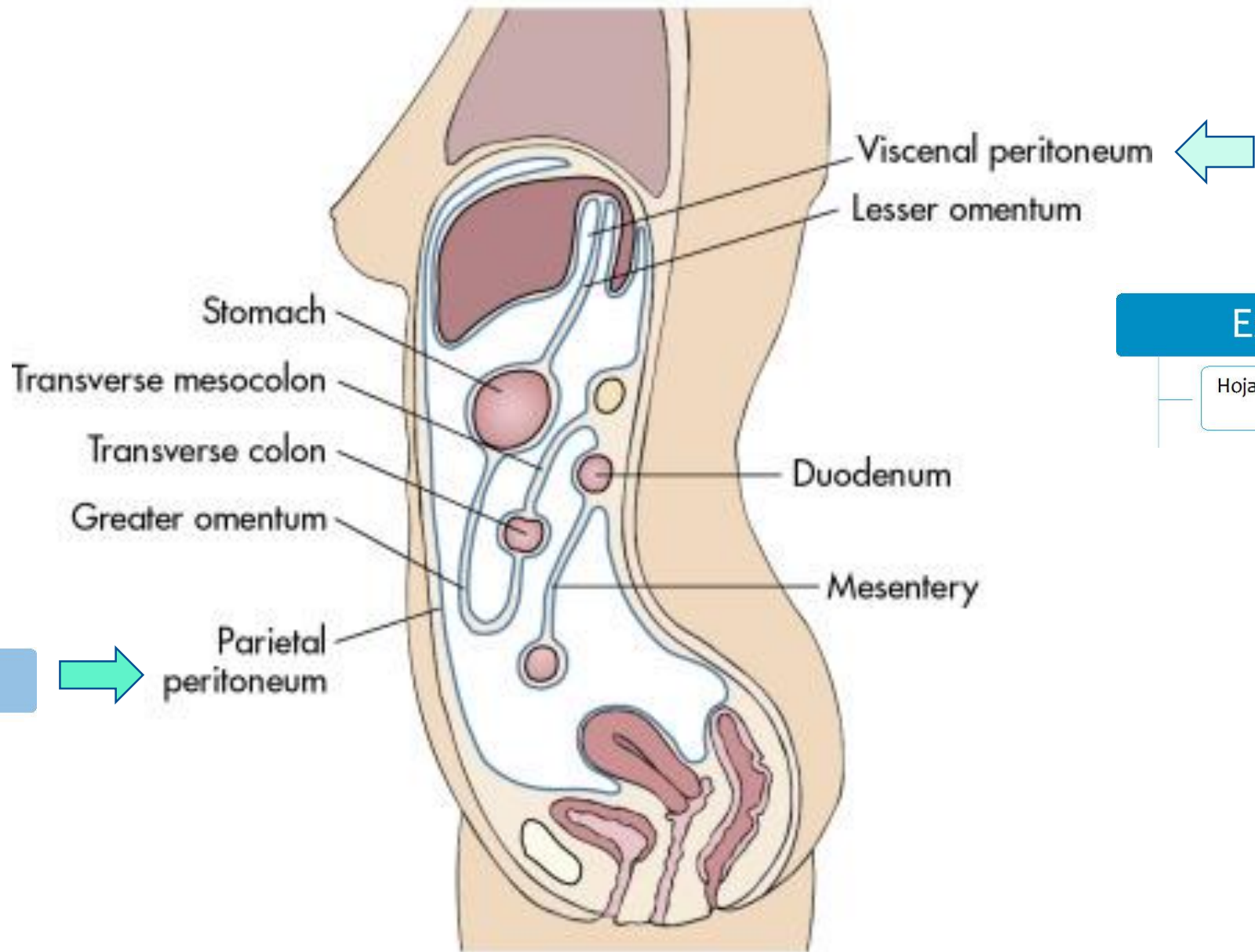




Somático

3-TC Body cavities: Pleural and pericardial





Somático

Esplácnico

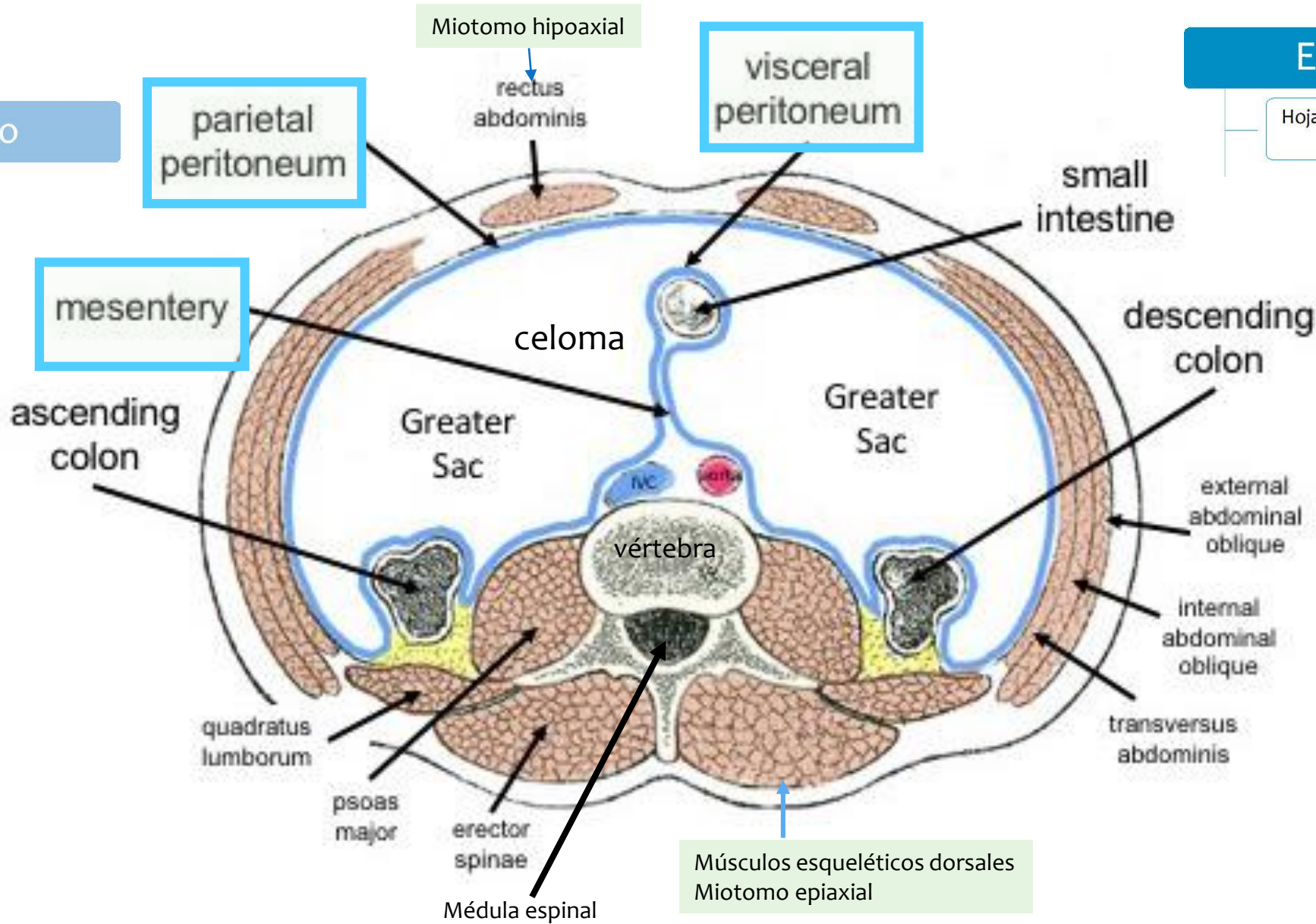
Hoja visceral de peritoneo, pleuras y pericardio



Somático

Esplácnico

Hoja visceral de peritoneo, pleuras y pericardio



Músculos esqueléticos abdominales Miotomo hipoaxial

Músculos esqueléticos dorsales Miotomo epiaxial

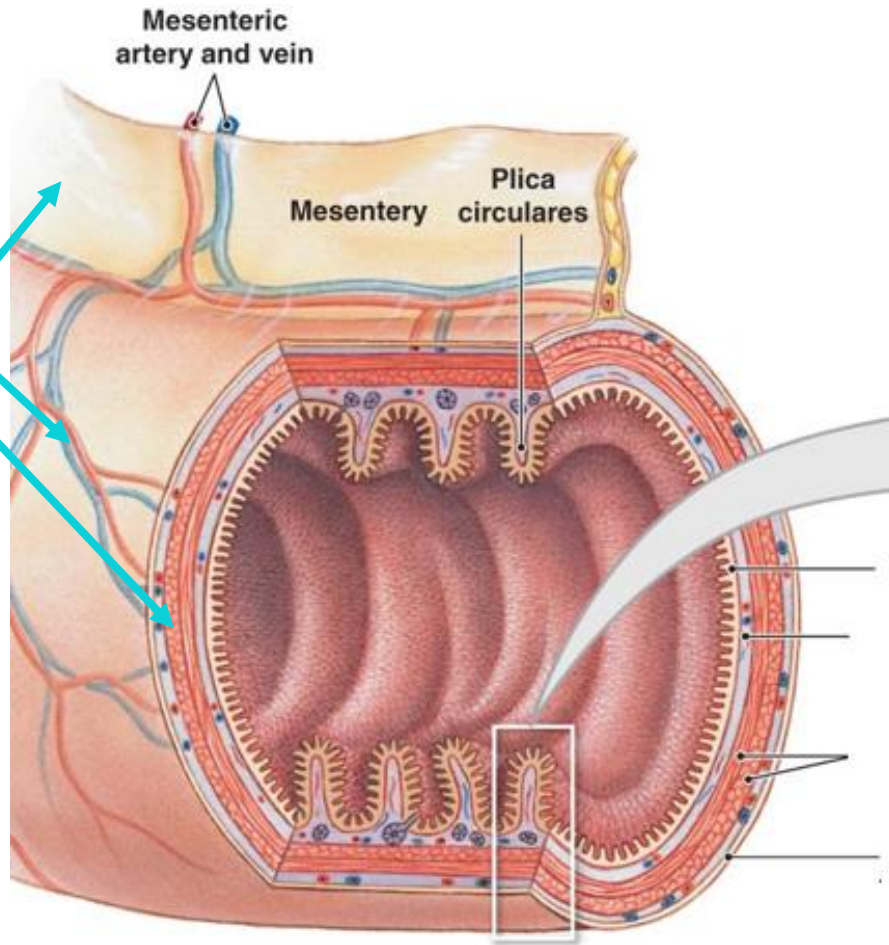


# Esplácnico

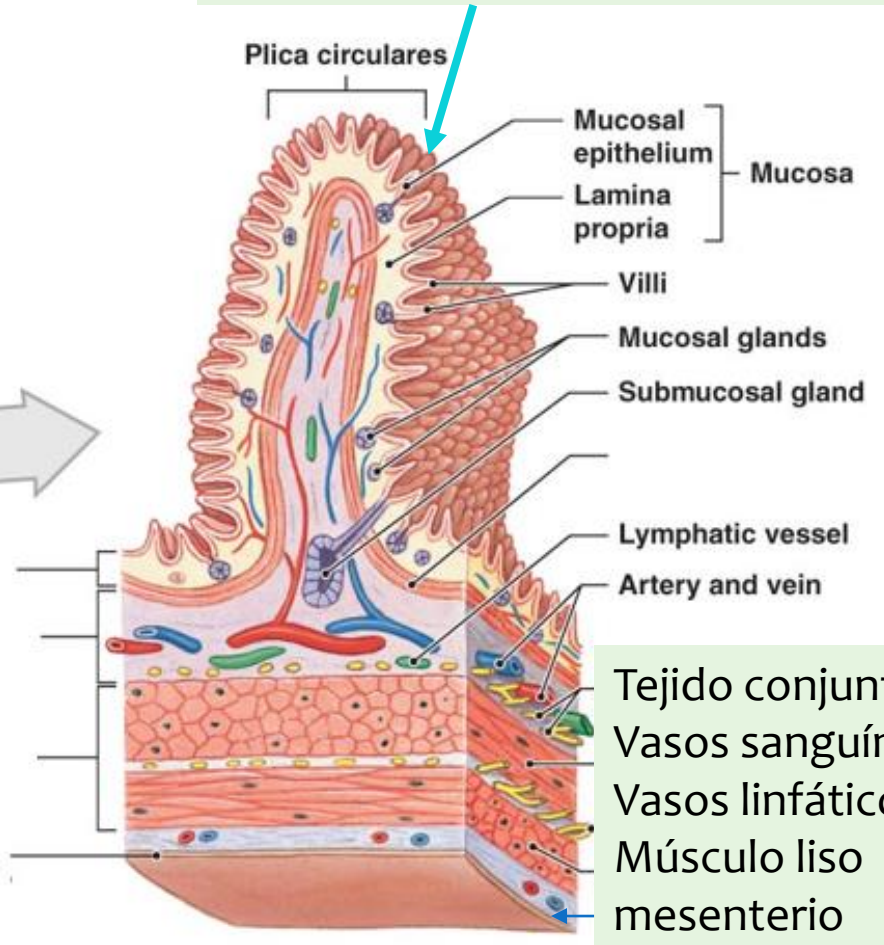
Tejido conjuntivo y muscular de todas las vísceras

Representación gráfica de una porción del intestino

Mesodermo lateral esplácnico

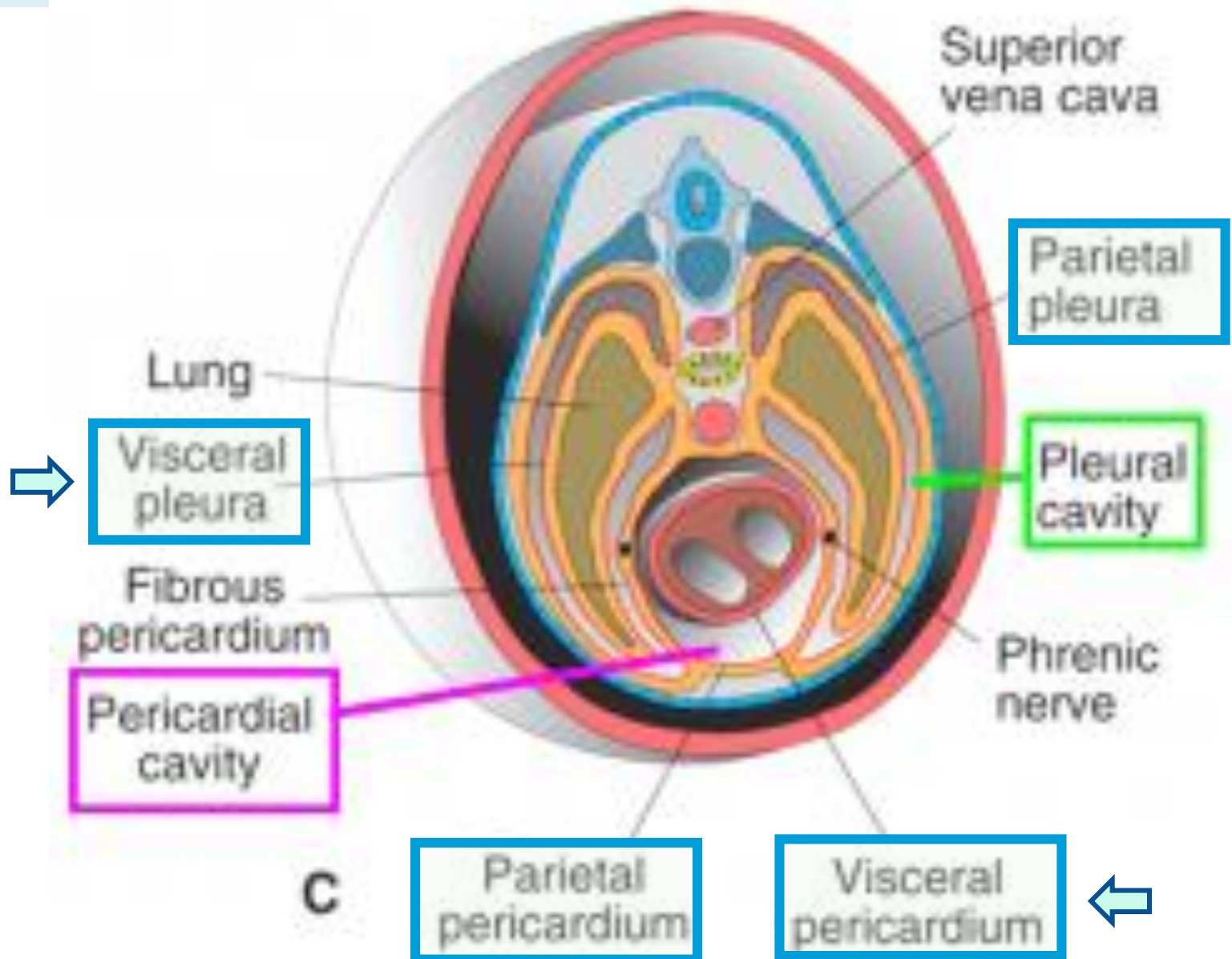


Epitelio del intestino: endodermo



Tejido conjuntivo  
 Vasos sanguíneos  
 Vasos linfáticos  
 Músculo liso  
 mesenterio



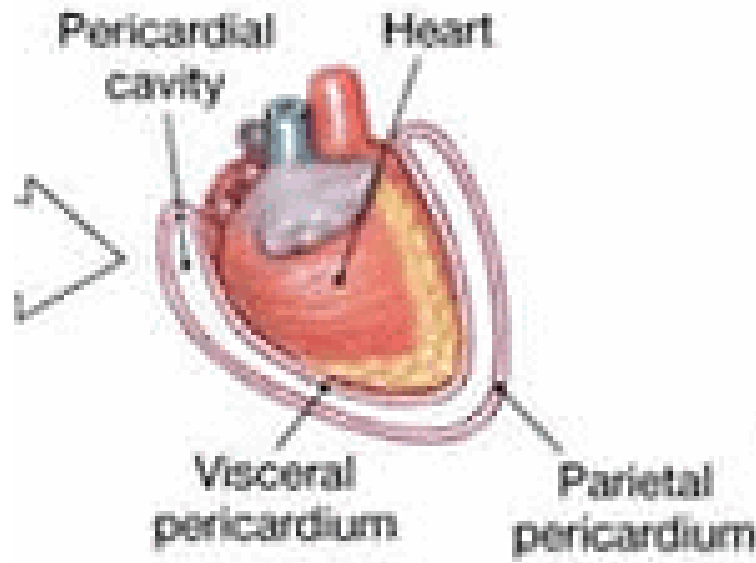
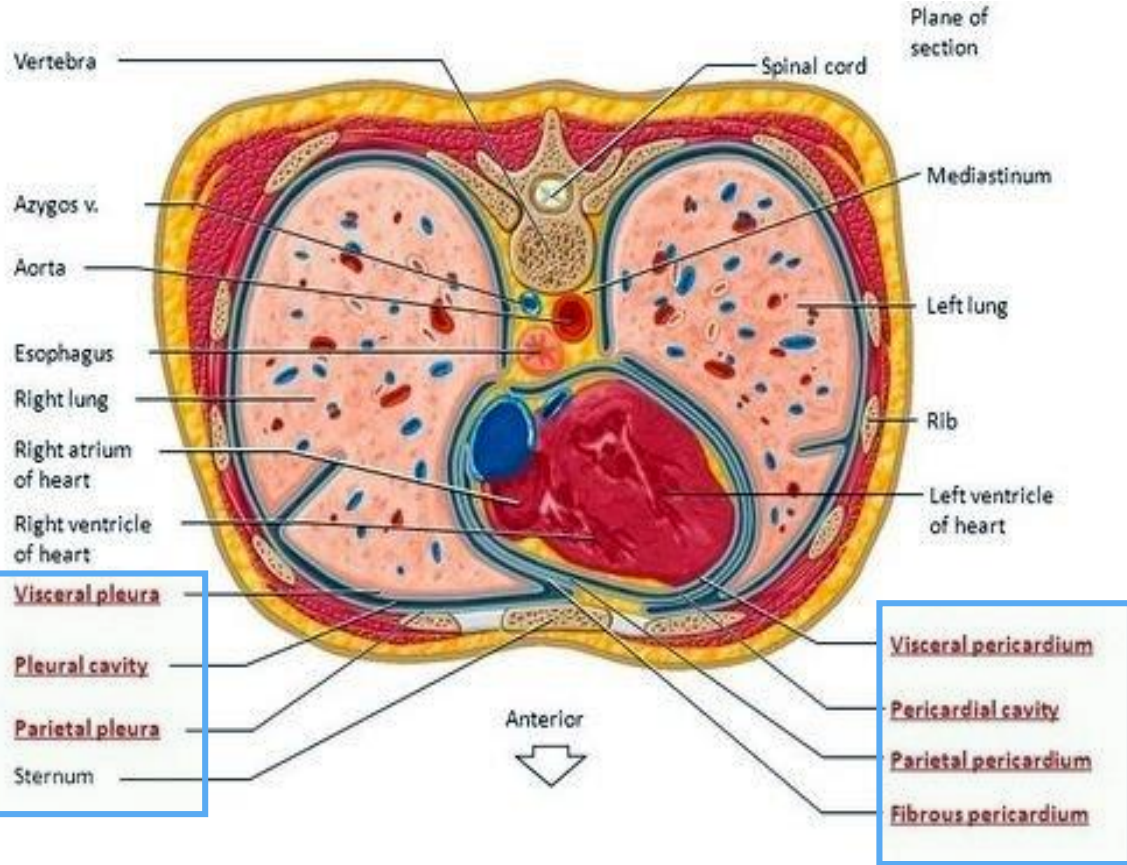
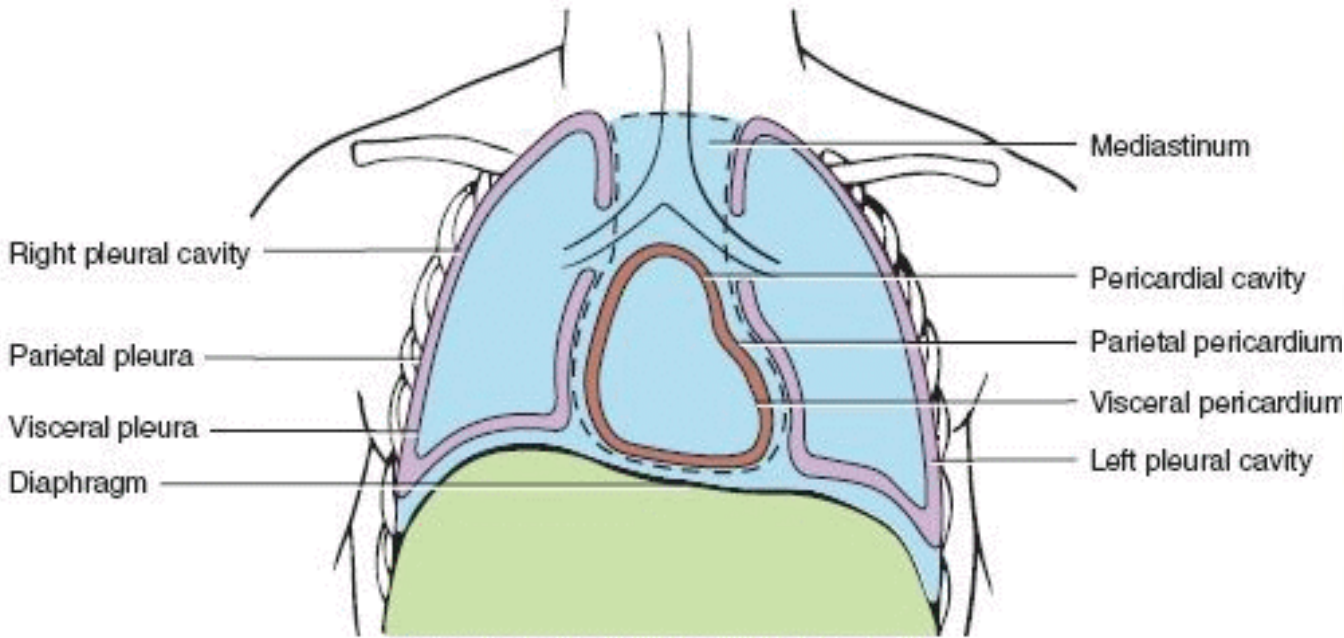


**Esplácnico**

Hoja visceral de peritoneo, pleuras y pericardio

3-TC Body cavities: Pleural and pericardial





Somático

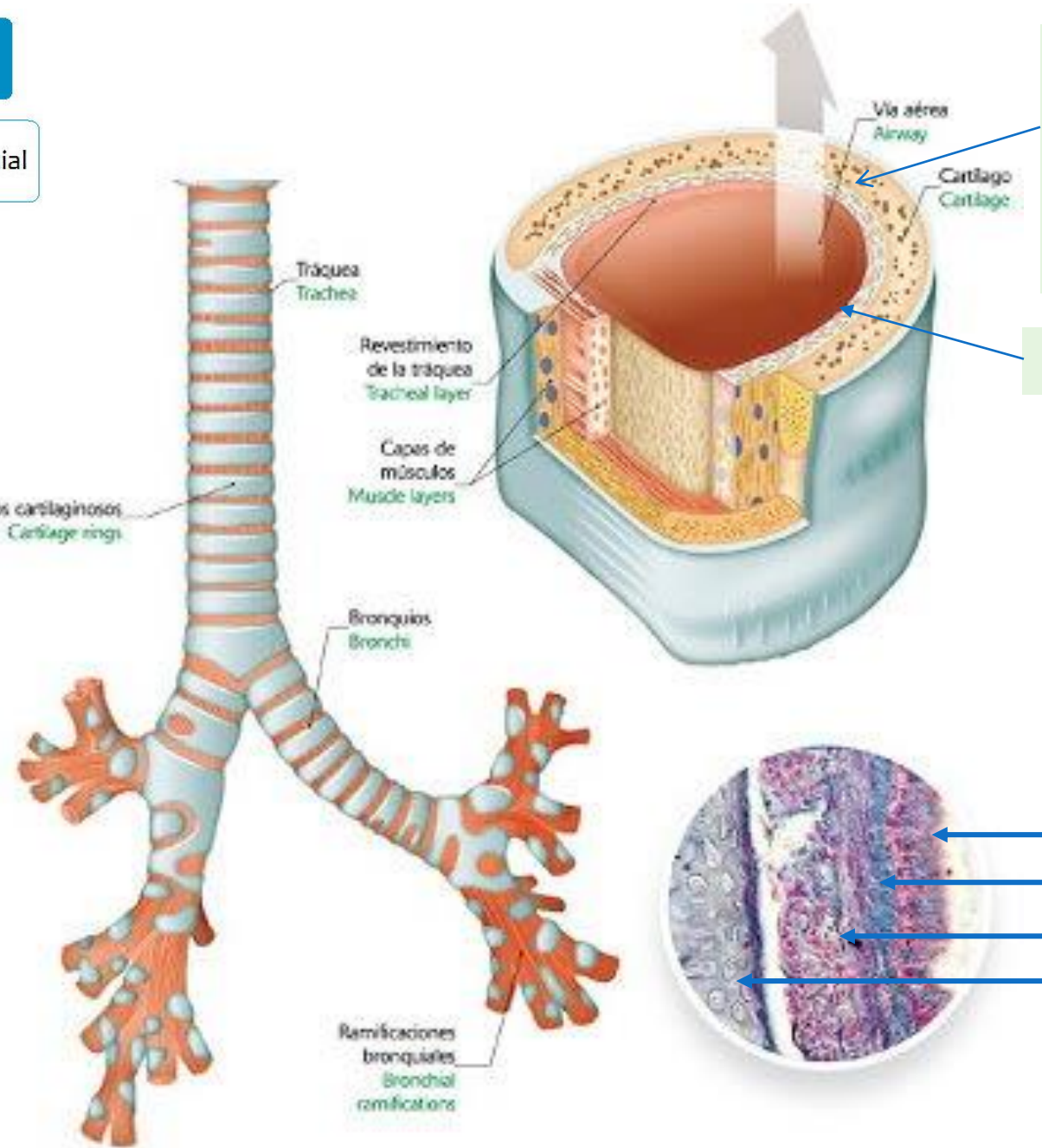
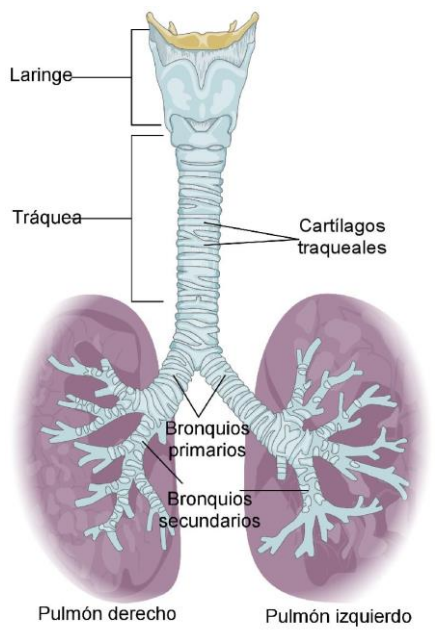
Esplácnico

Hoja visceral de peritoneo, pleuras y pericardio



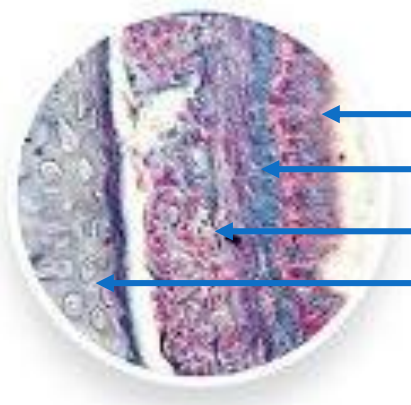
# Esplácnico

Cartílago de tráquea y árbol bronquial



Tejido conjuntivo, muscular, cartilaginoso  
Mesodermo lateral esplácnico

Epitelio: endodermo



Epitelio

Tejido conjuntivo

Músculo liso

Cartílago

Mesodermo lateral esplácnico



# Esplácnico

Todo el sistema cardiovascular

(A)

Head mesenchyme

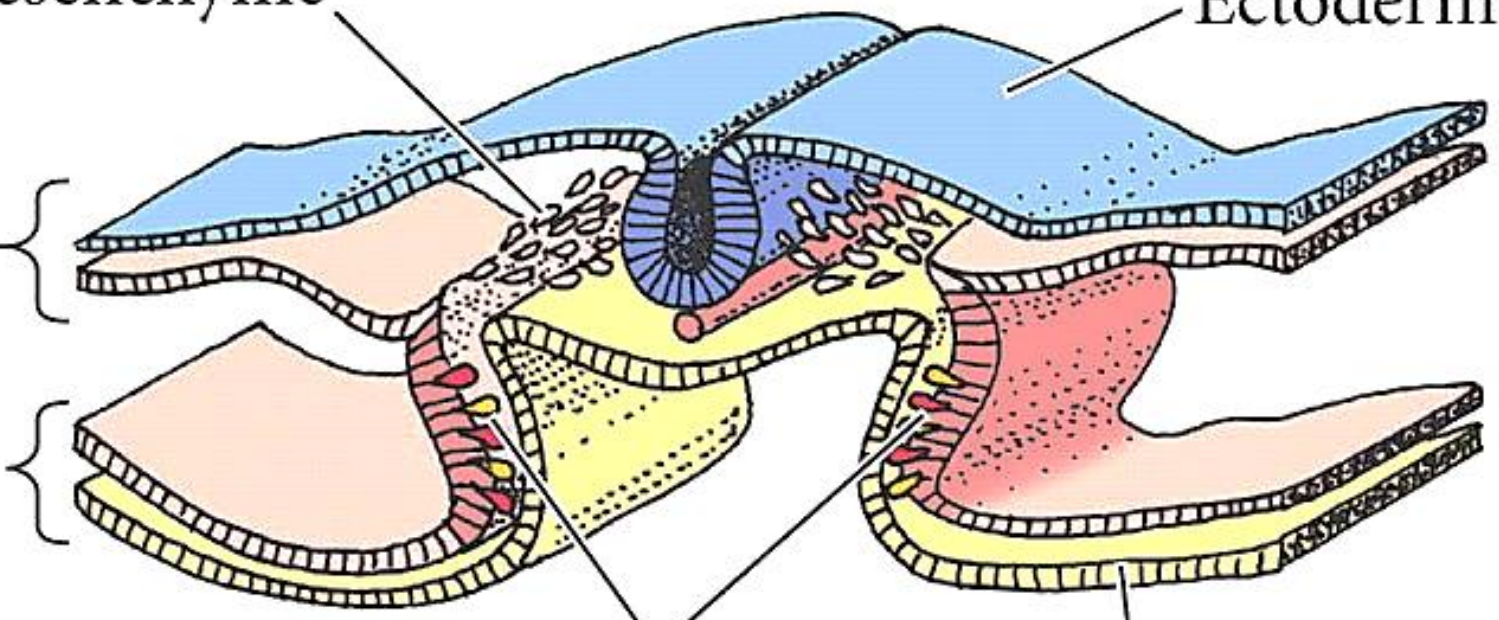
Ectoderm

Somatopleure

Splanchnopleure

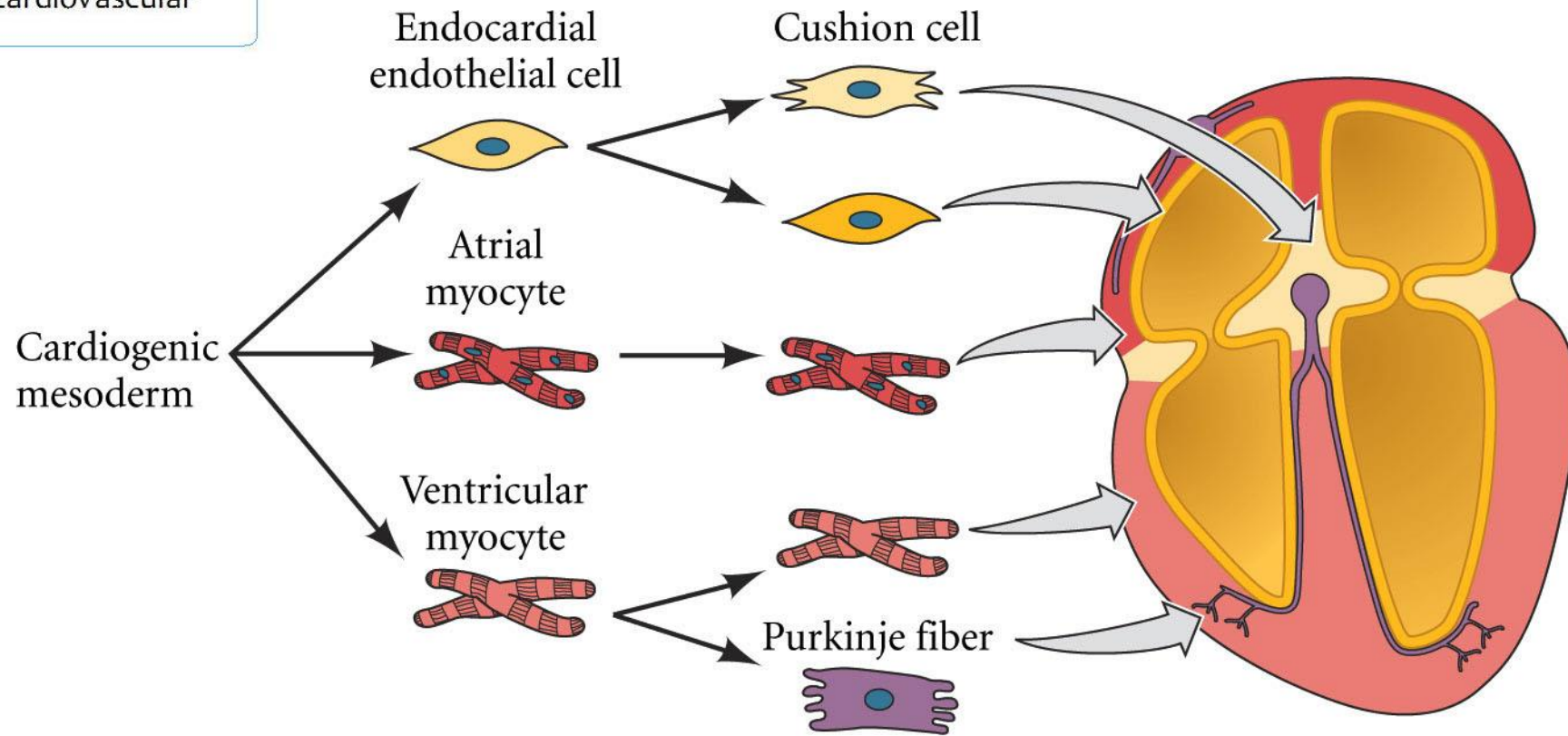
Cardiogenic mesoderm

Endoderm



# Esplácnico

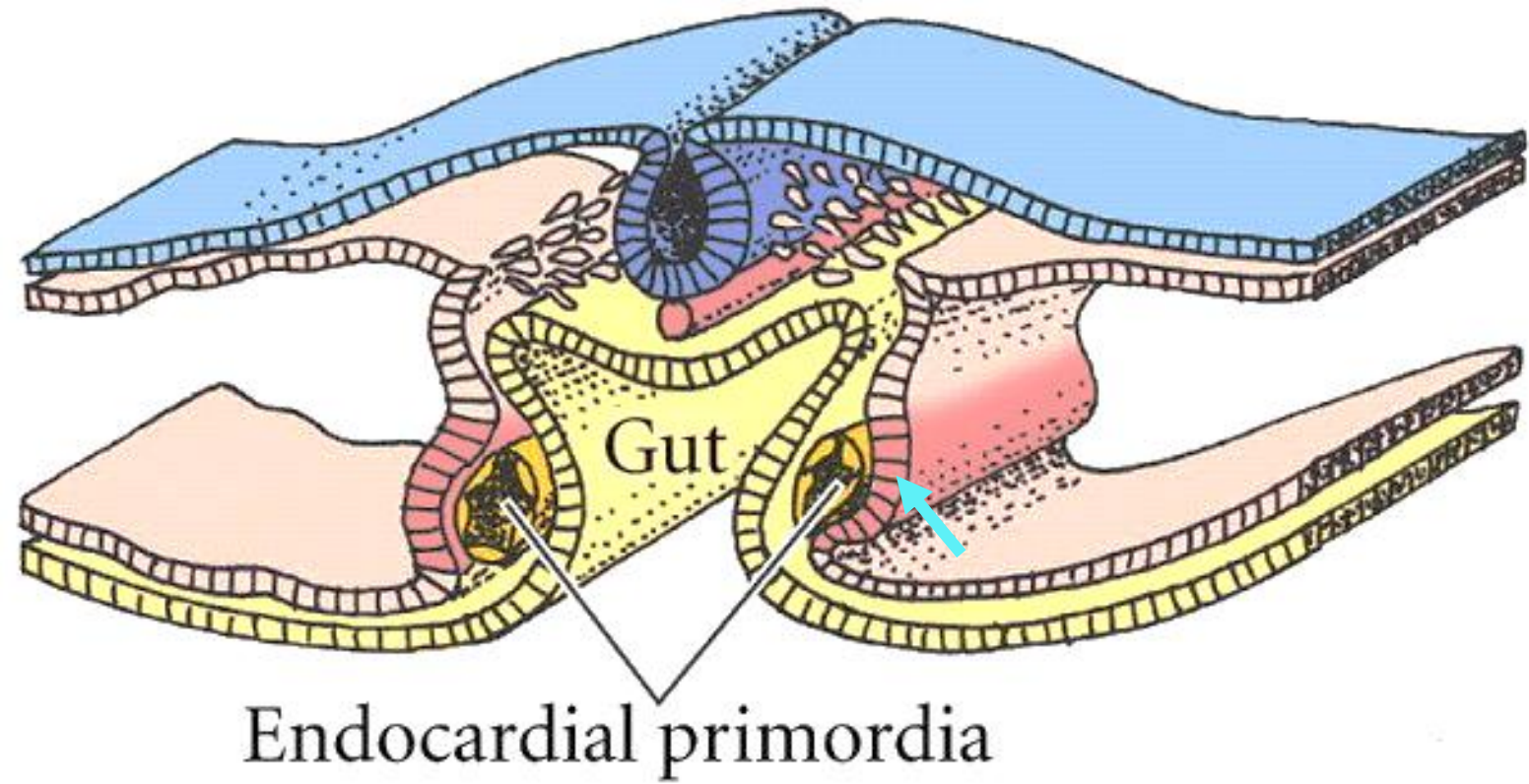
Todo el sistema cardiovascular



# Esplácnico

Todo el sistema cardiovascular

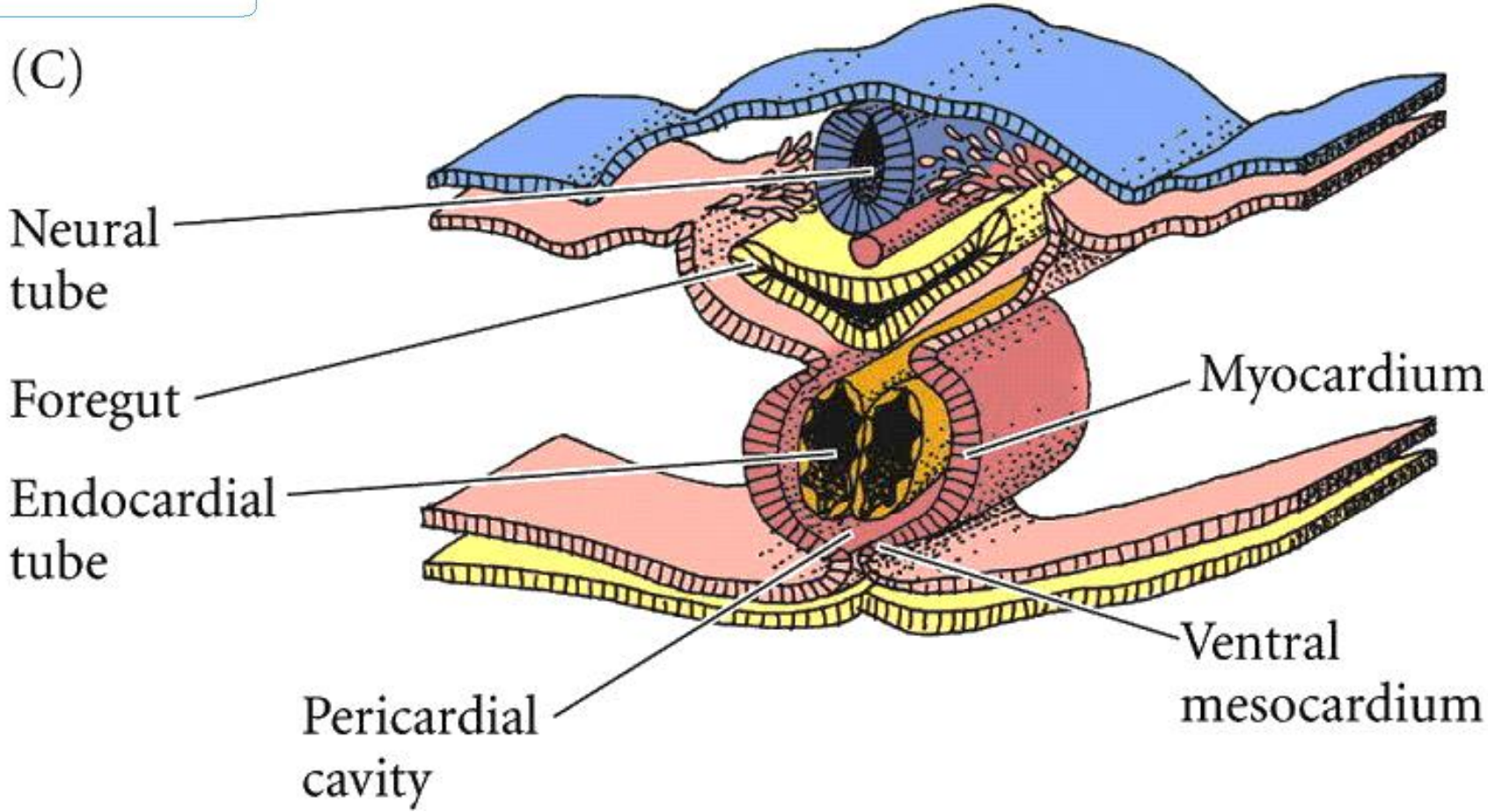
(B)



# Esplácnico

Todo el sistema cardiovascular

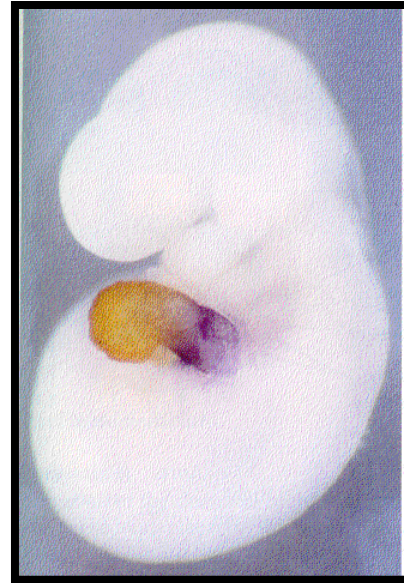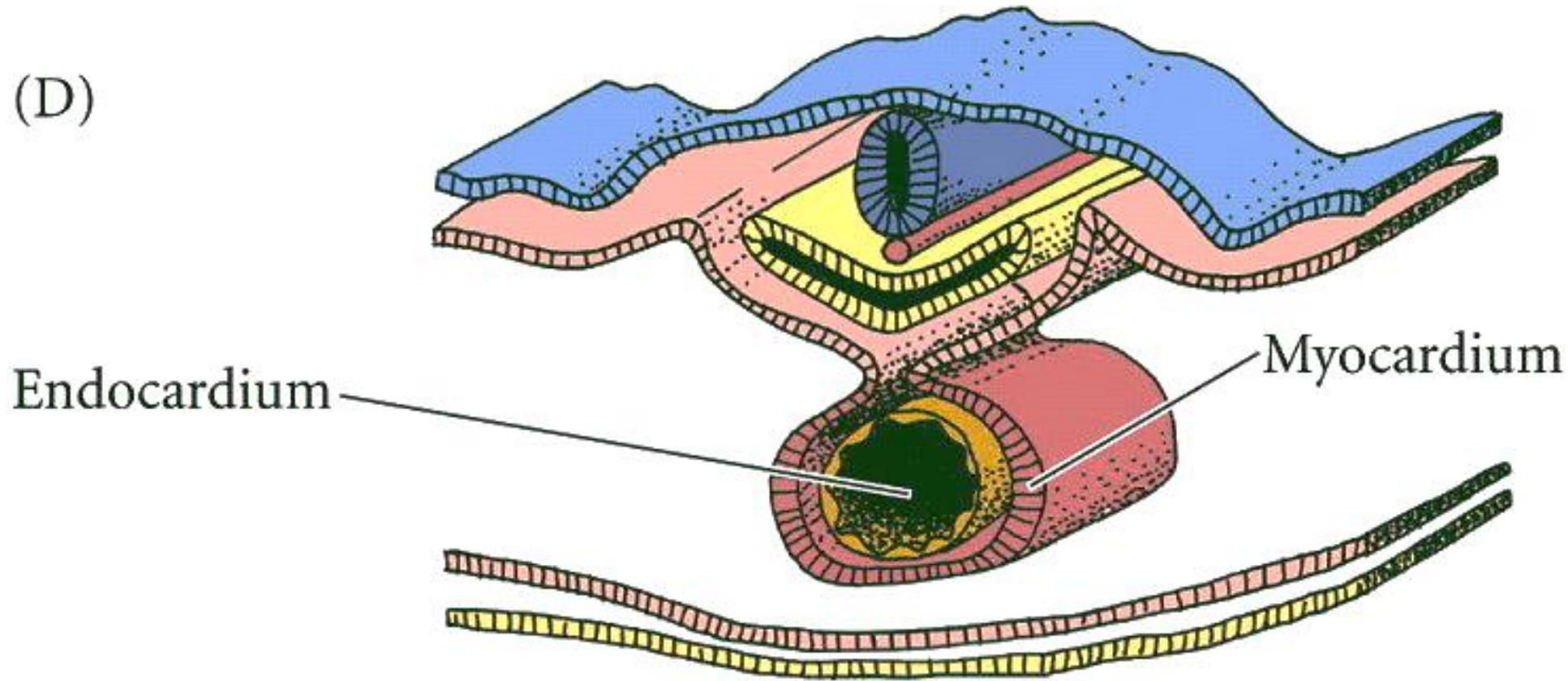
(C)



# Esplácnico

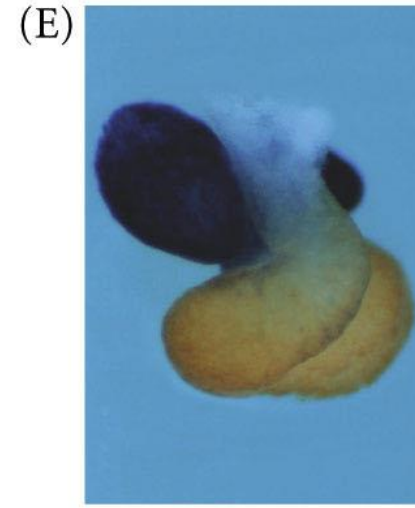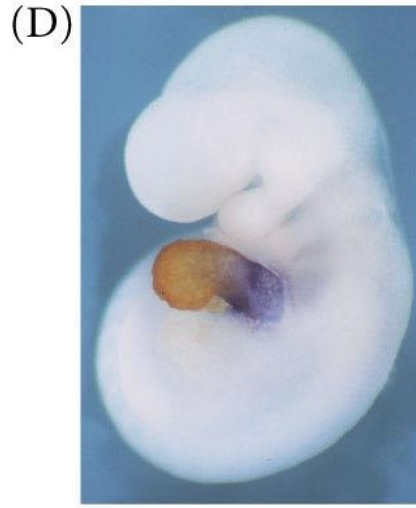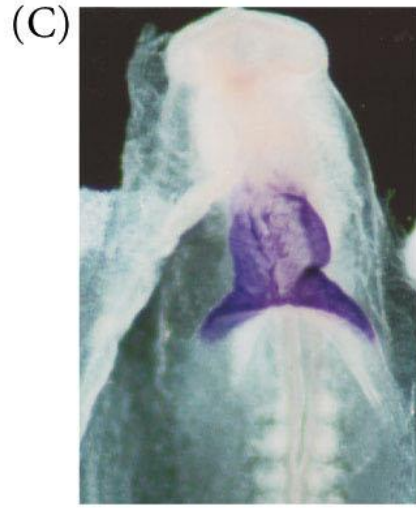
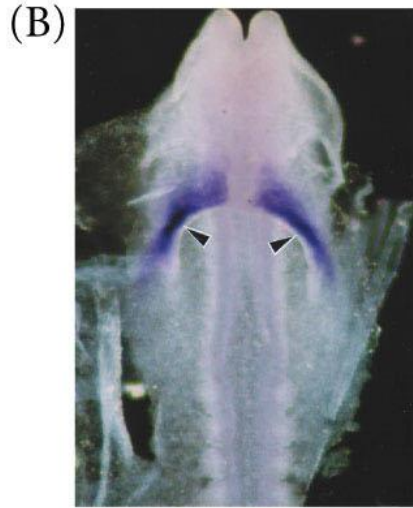
Todo el sistema cardiovascular

(D)



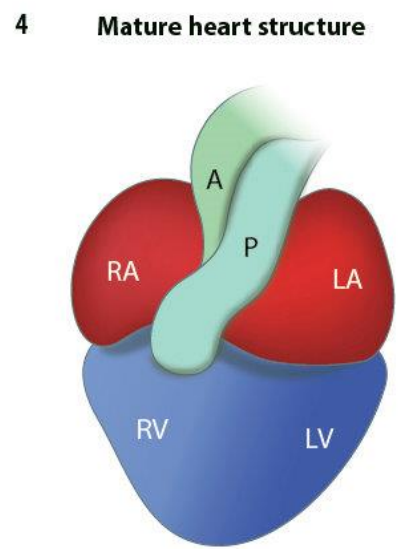
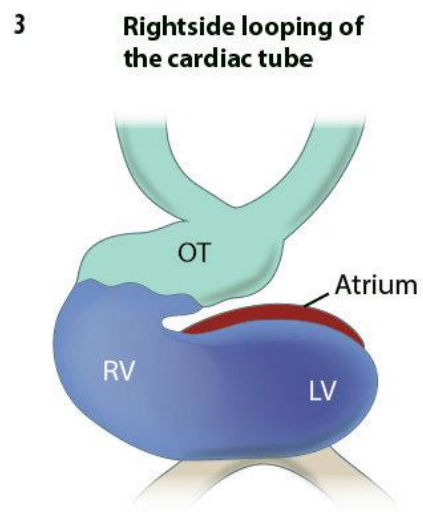
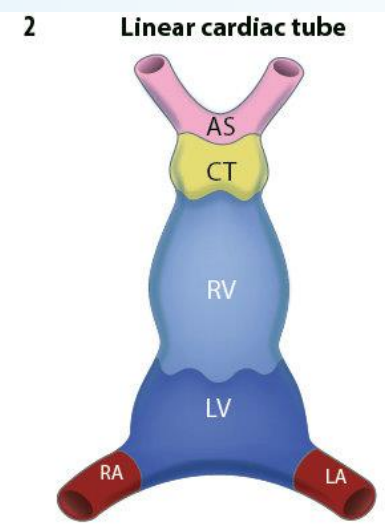
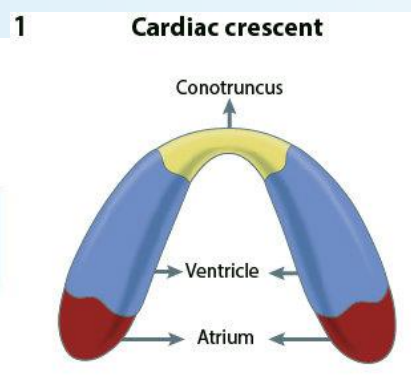
# Esplácnico

Todo el sistema cardiovascular

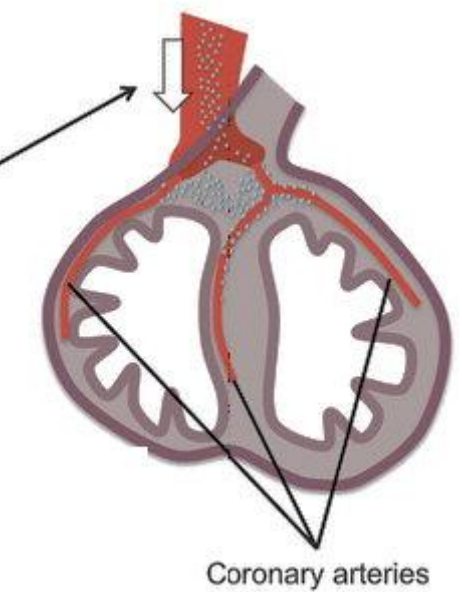


# Esplácnico

Todo el sistema cardiovascular



Ectodermo:  
cresta  
neural



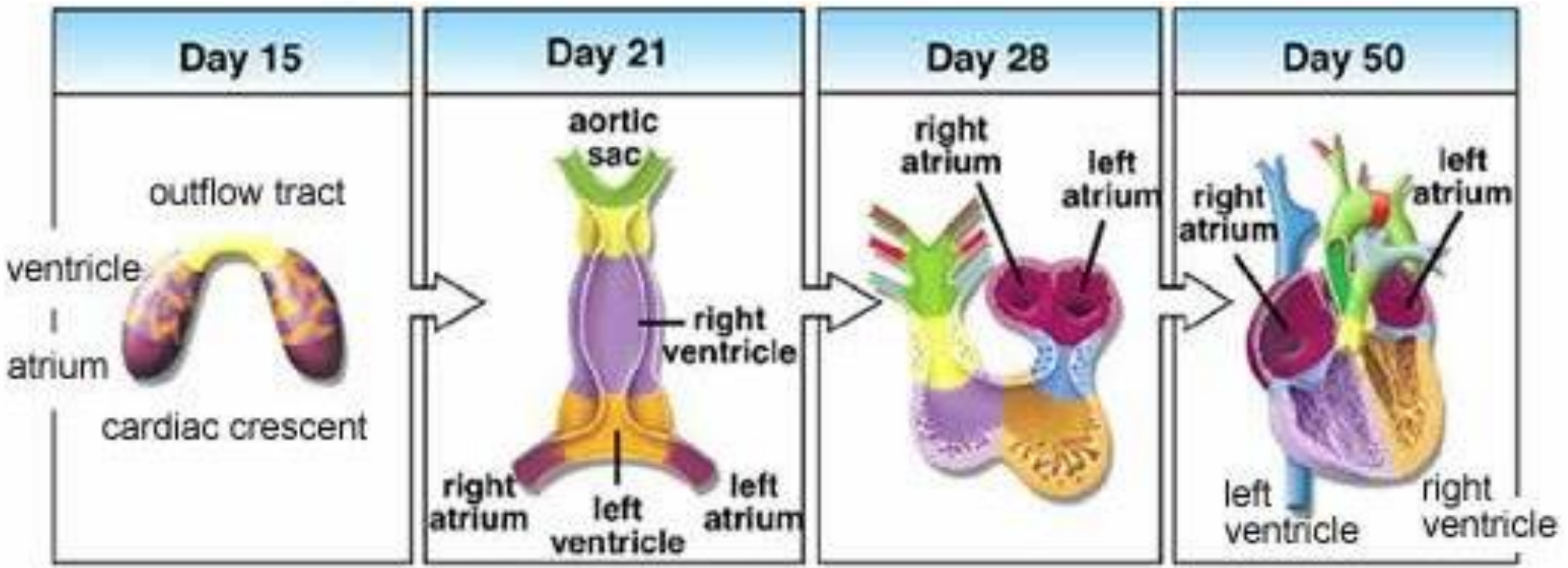
RA - Right atrium	RV - Right ventricle	CT - Conotruncus
LA - Left atrium	LV - Left ventricle	OT - Outflow tract
A - Aorta	P - Pulmonary artery	AS - Aortic sac





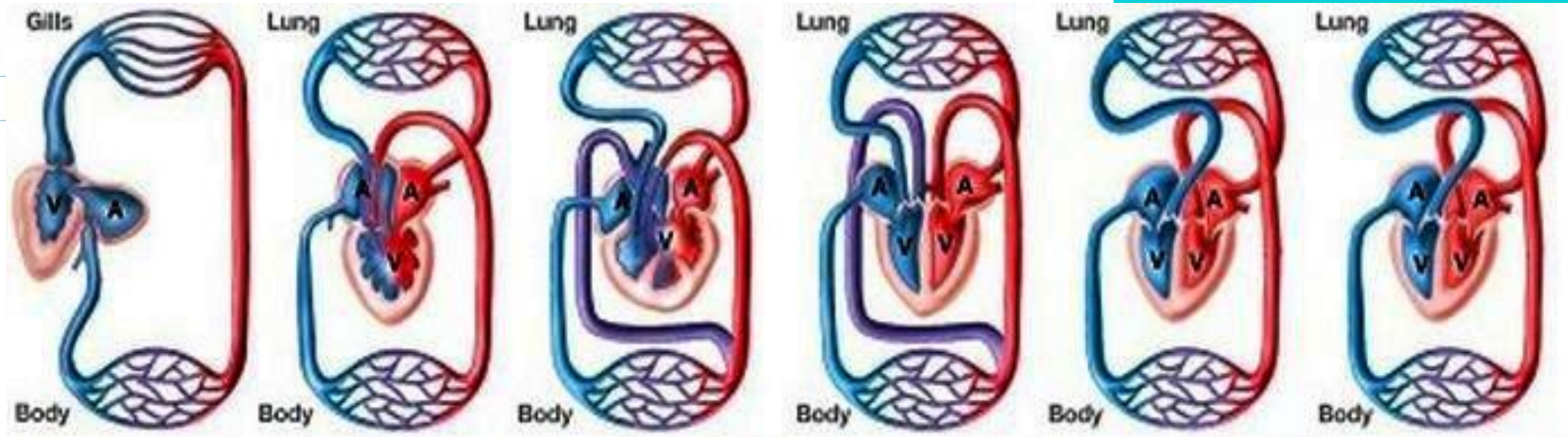
# Esplácnico

Todo el sistema cardiovascular



Esplácnico

Todo el sistema cardiovascular



1 circuit 2-chambered heart      2 circuits 3-chambered heart      2 circuits "5-chambered" heart      2 circuits 4-chambered heart      2 circuits 4-chambered heart      2 circuits 4-chambered heart

Fish      Frogs      Turtles, lizards      Crocodiles      Birds      Mammals

A = Atrium  
V = Ventricle

— Three-chambered heart  
— Two circulatory loops

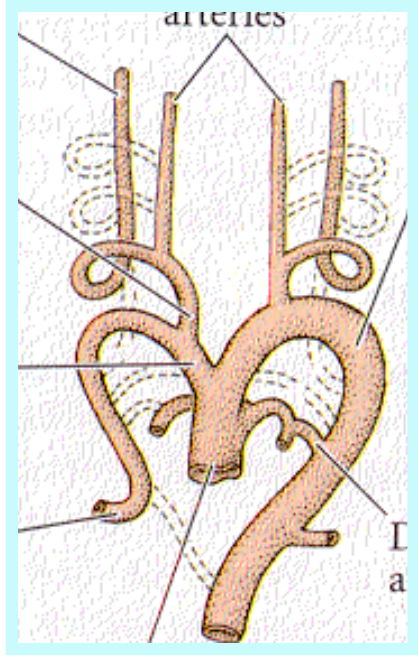
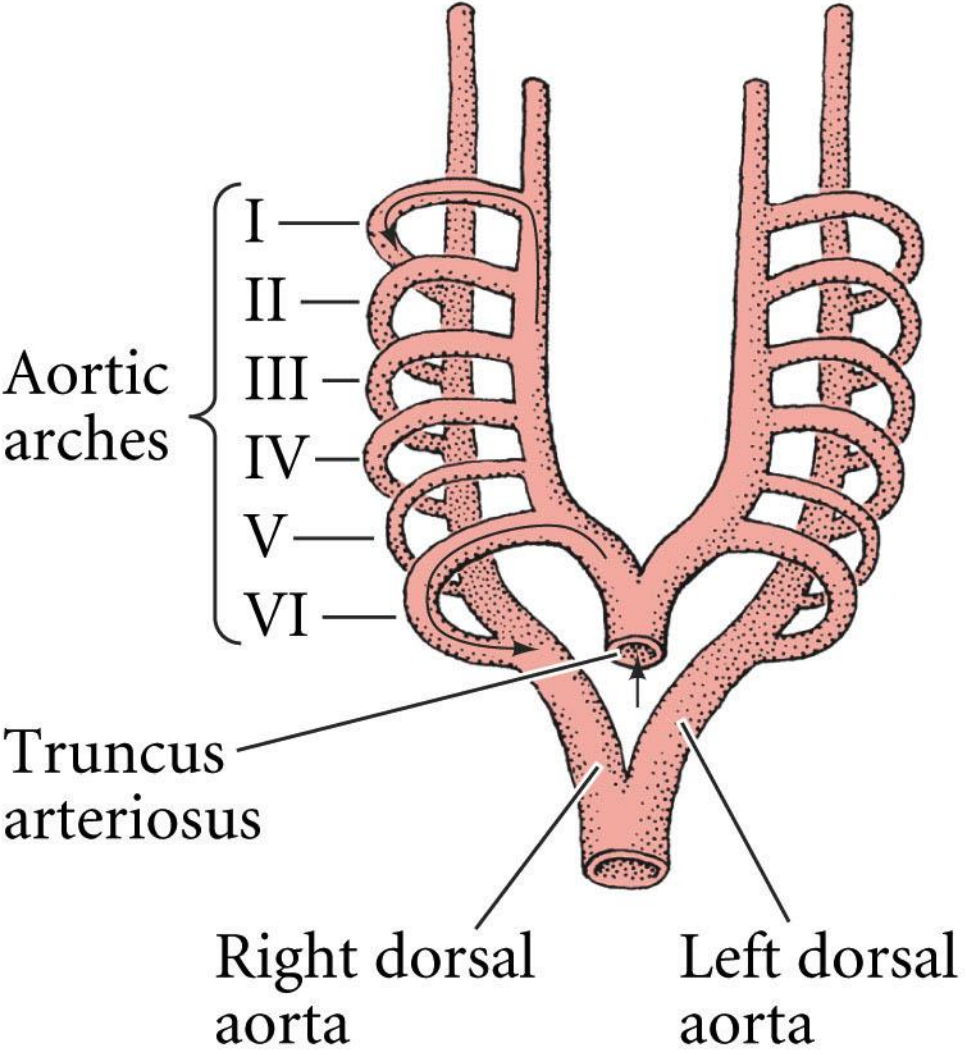
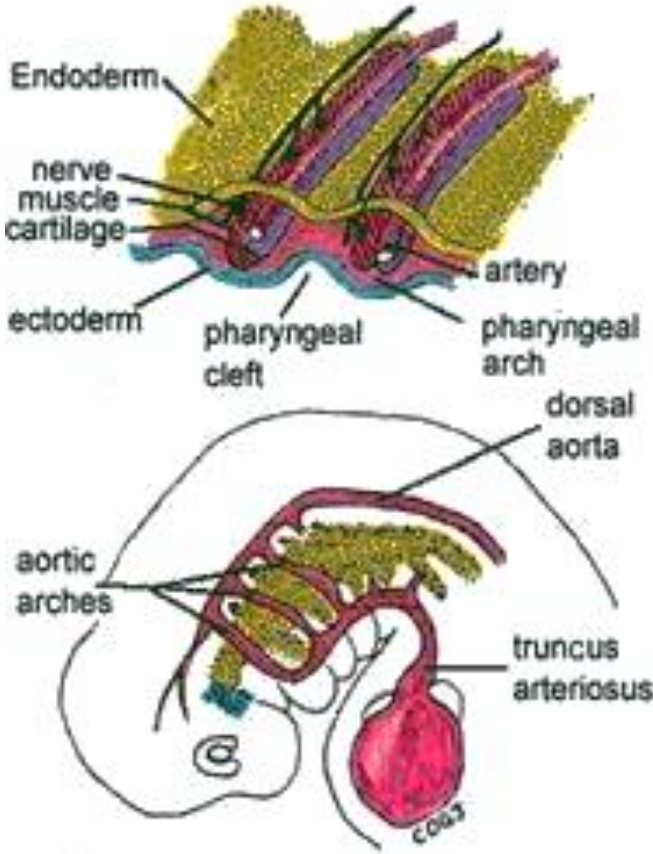
Ventricle divided into chambers (partially or completely)



# Esplácnico

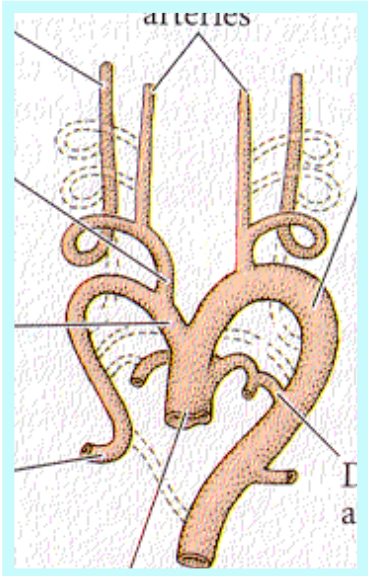
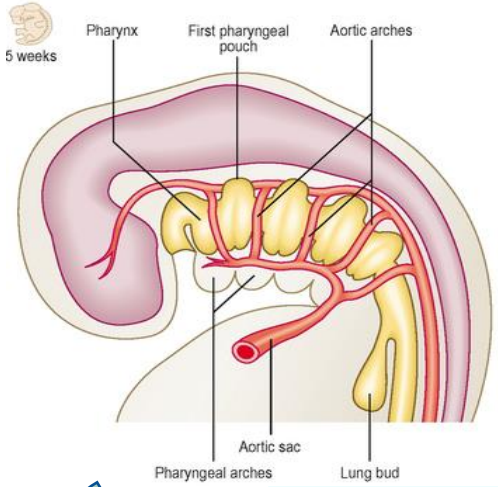
Todo el sistema cardiovascular

(A) 29 DAYS



# Esplácnico

Todo el sistema cardiovascular



**I**

Arteria maxilar

**II**

Arteria hioidea y estapedial

**III**

Arteria carótida común y parte de la carótida interna

**IV**

Parte del arco de la aorta

**V**

Regresa completamente, se pierde

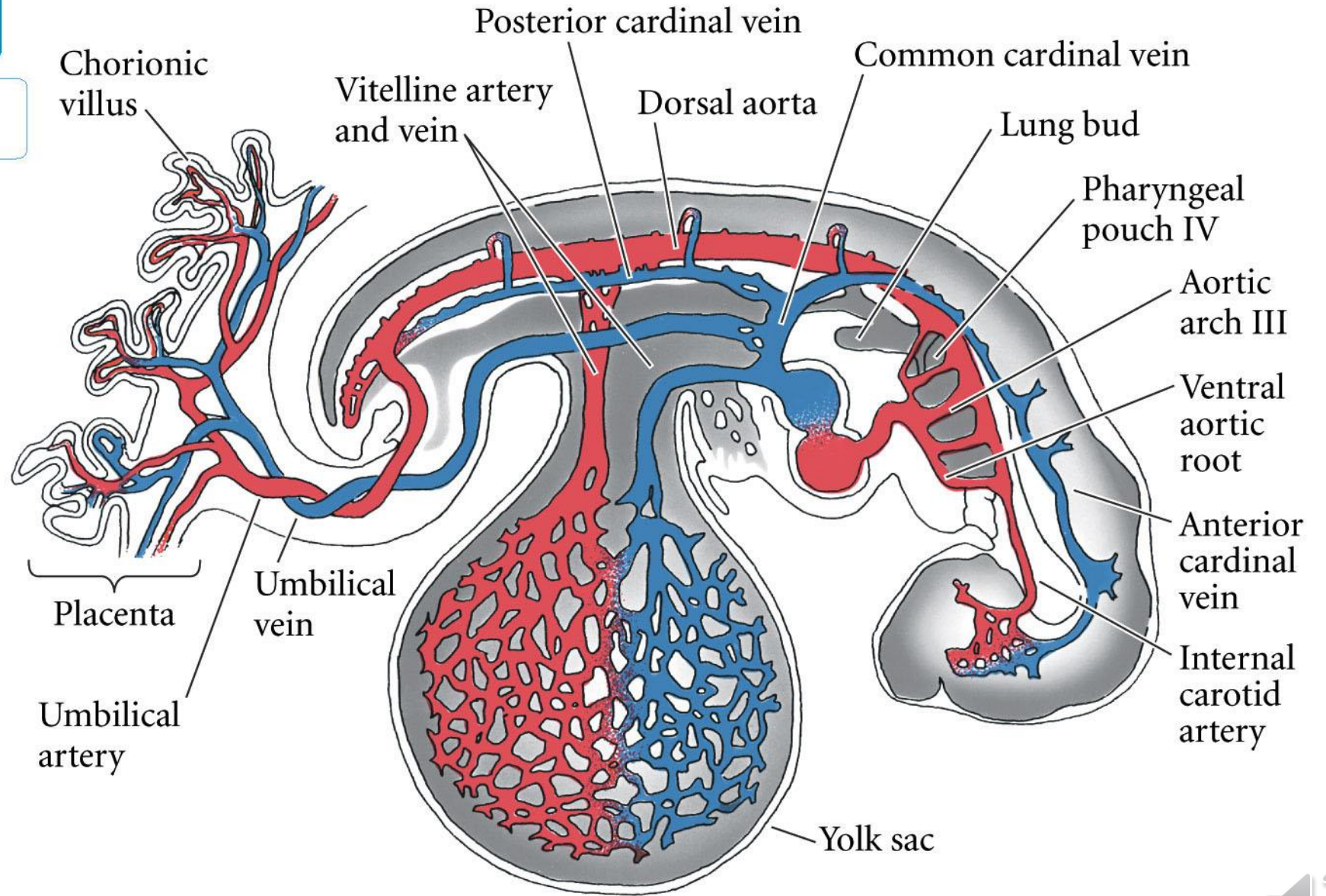
**VI**

Arterias pulmonares



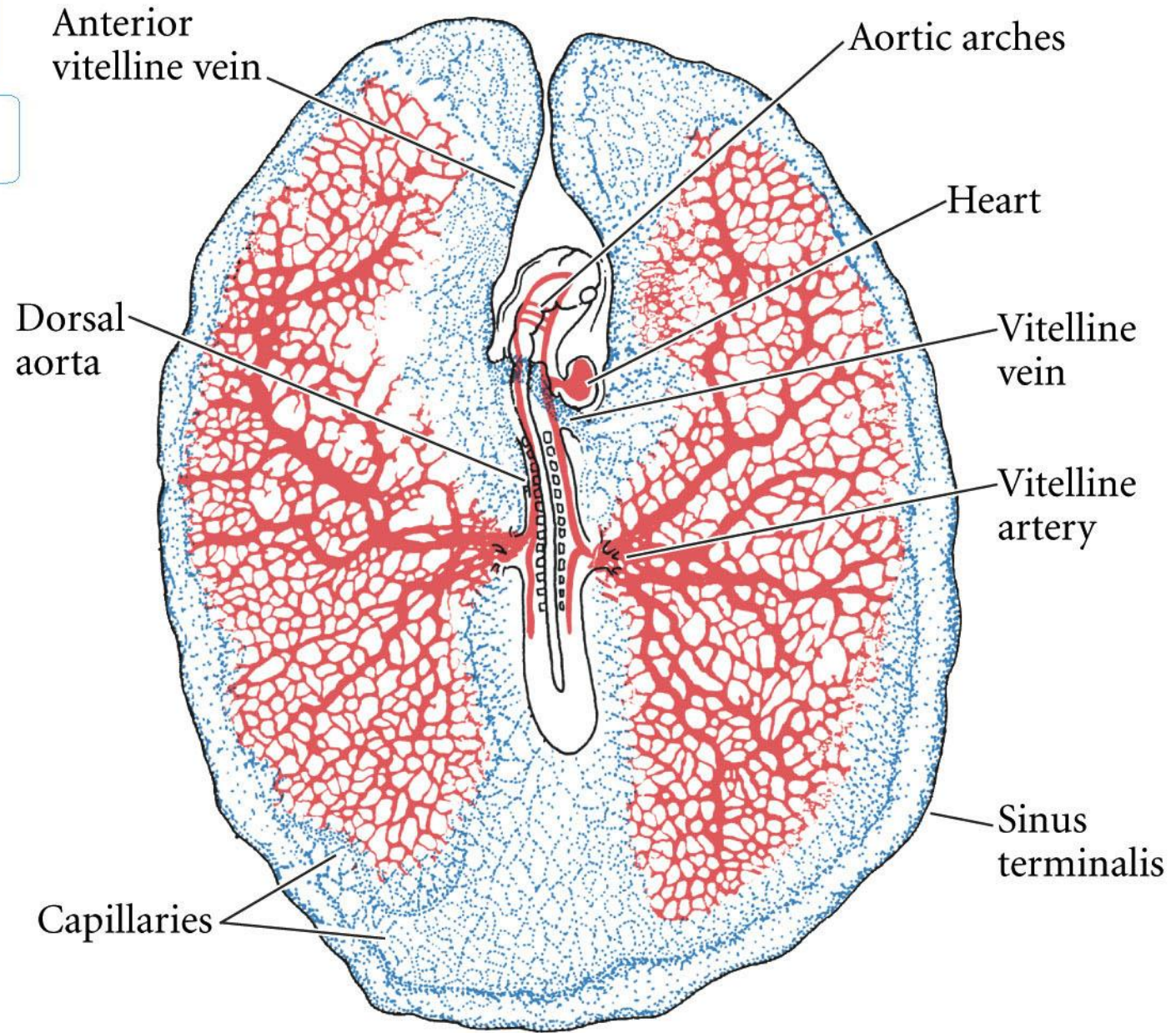
# Esplácnico

Todo el sistema cardiovascular



# Esplácnico

Todo el sistema cardiovascular



# Esplácnico

Todo el sistema cardiovascular

Lt. Vitelline vein

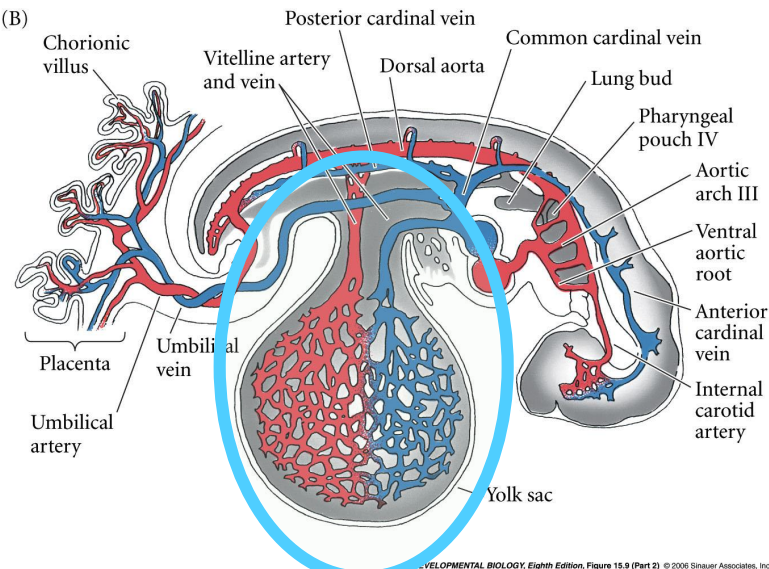
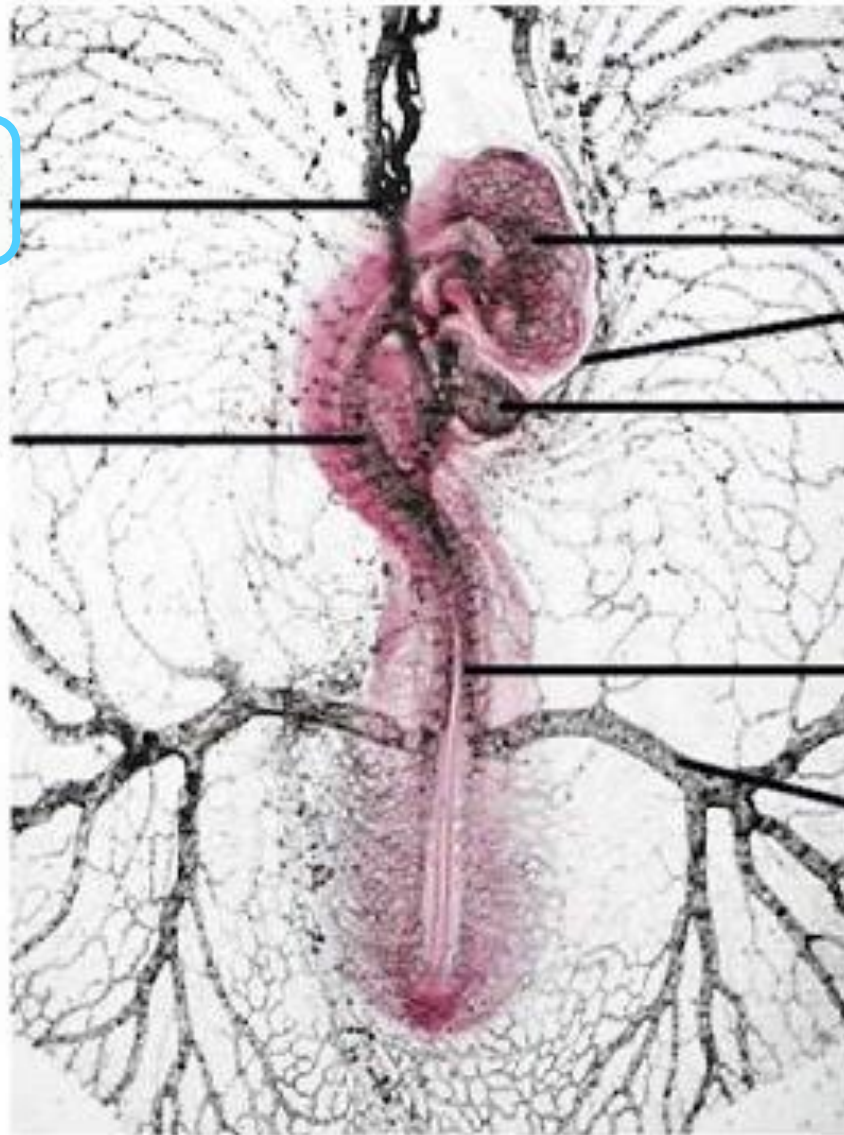
Descending Aorta

Head Plexus  
Rt. Vitelline Vein

Ventricle

Rt. Dorsal Aorta

Rt. Vitelline Artery

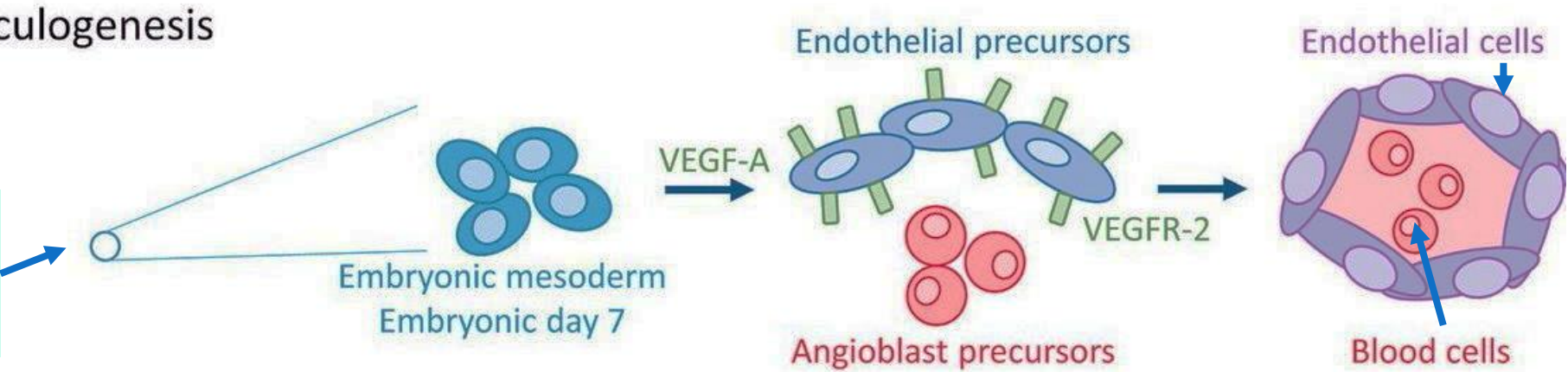


# Esplácnico

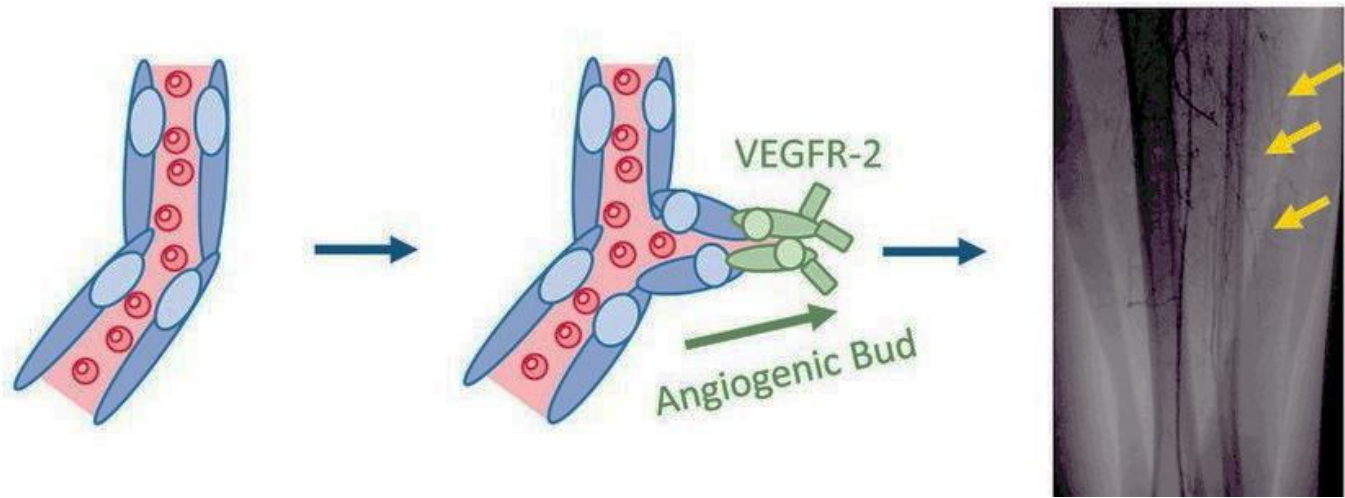
Todo el sistema cardiovascular

## Vasculogenesis

Mesodermo lateral esplácnico



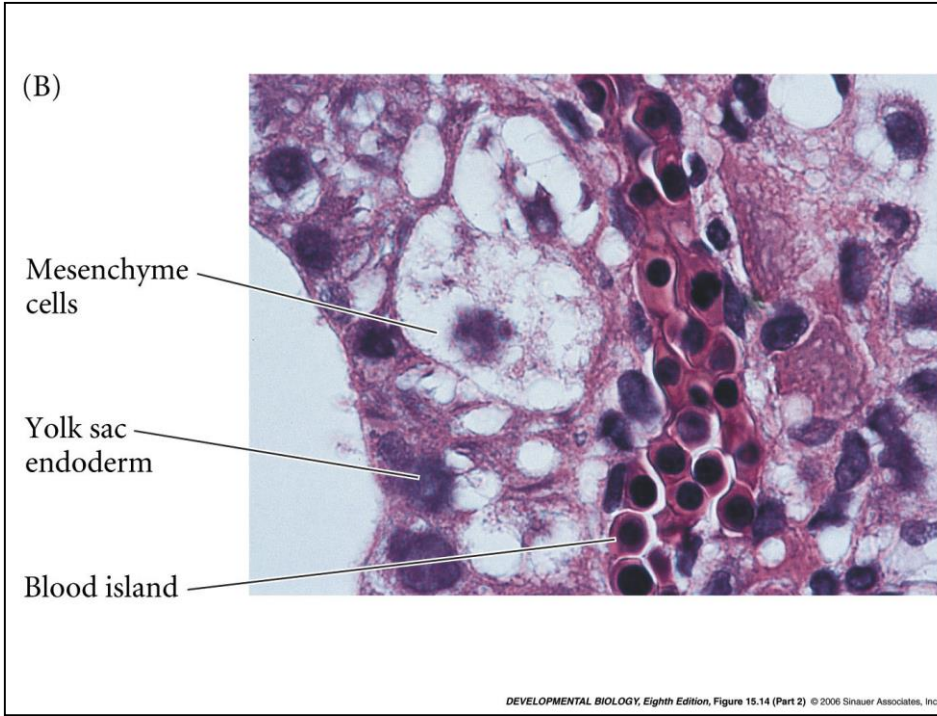
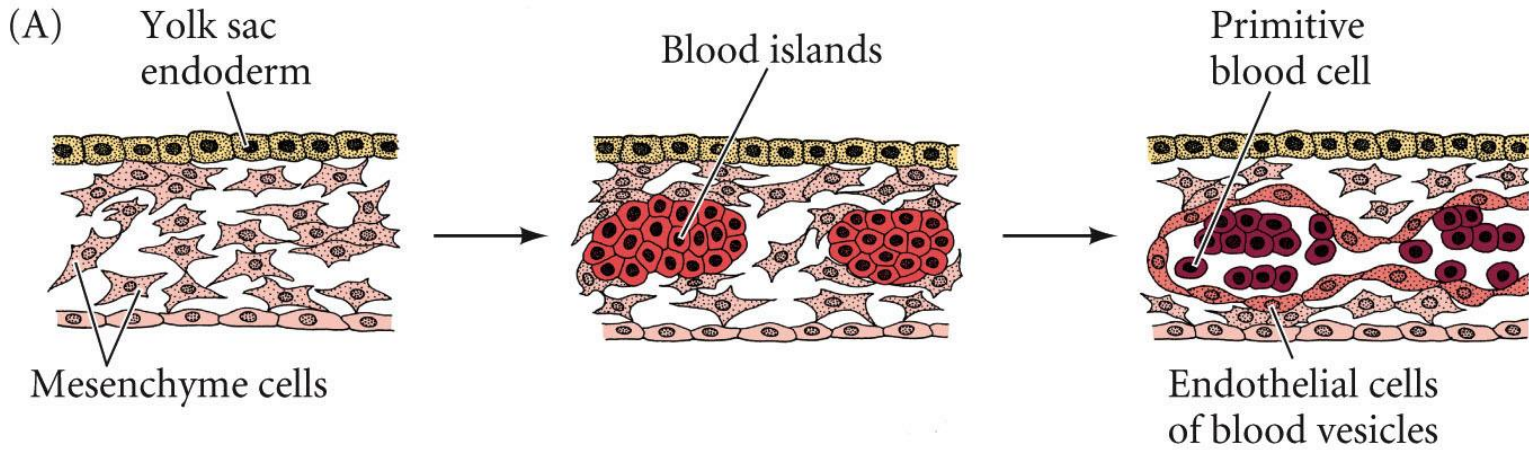
## Angiogenesis





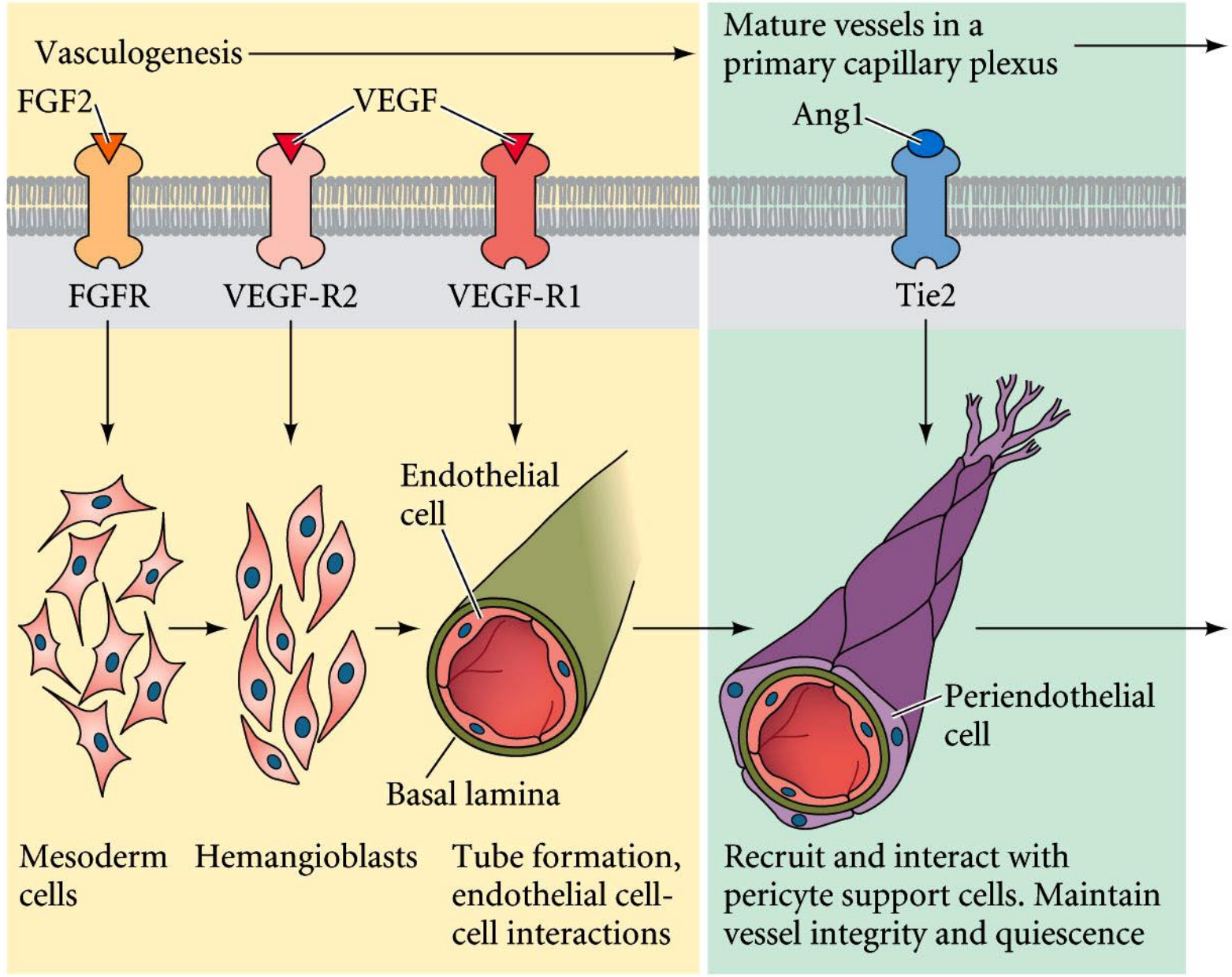
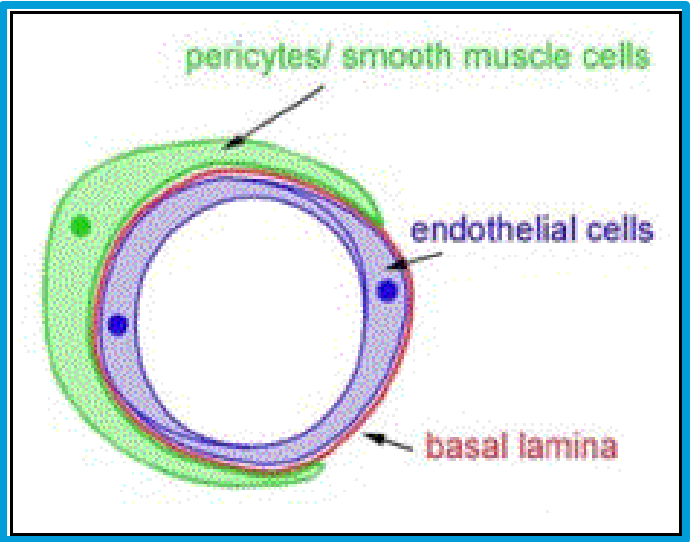
# Esplácnico

Todo el sistema cardiovascular



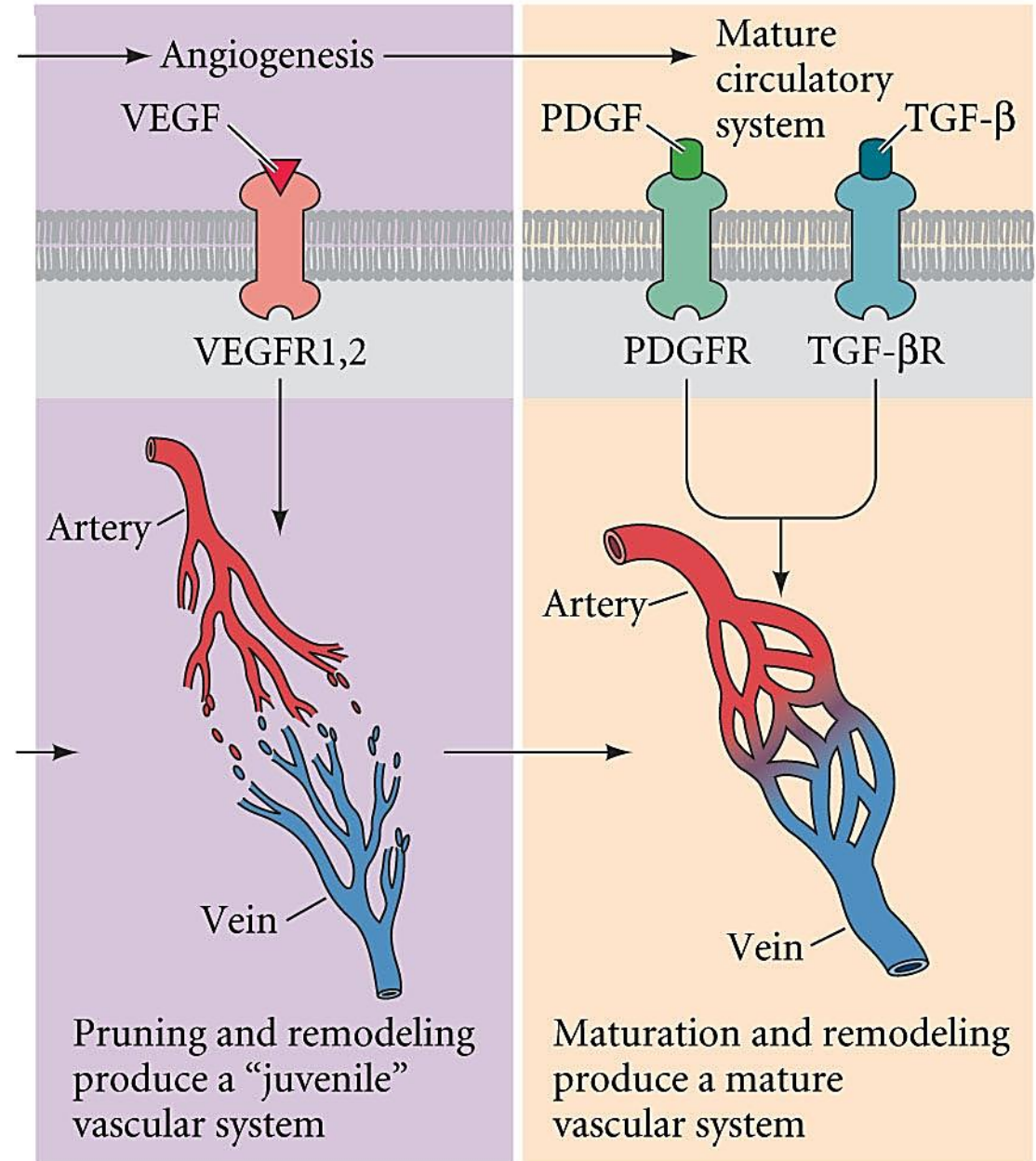
# Esplácnico

Todo el sistema cardiovascular



# Esplácnico

Todo el sistema cardiovascular

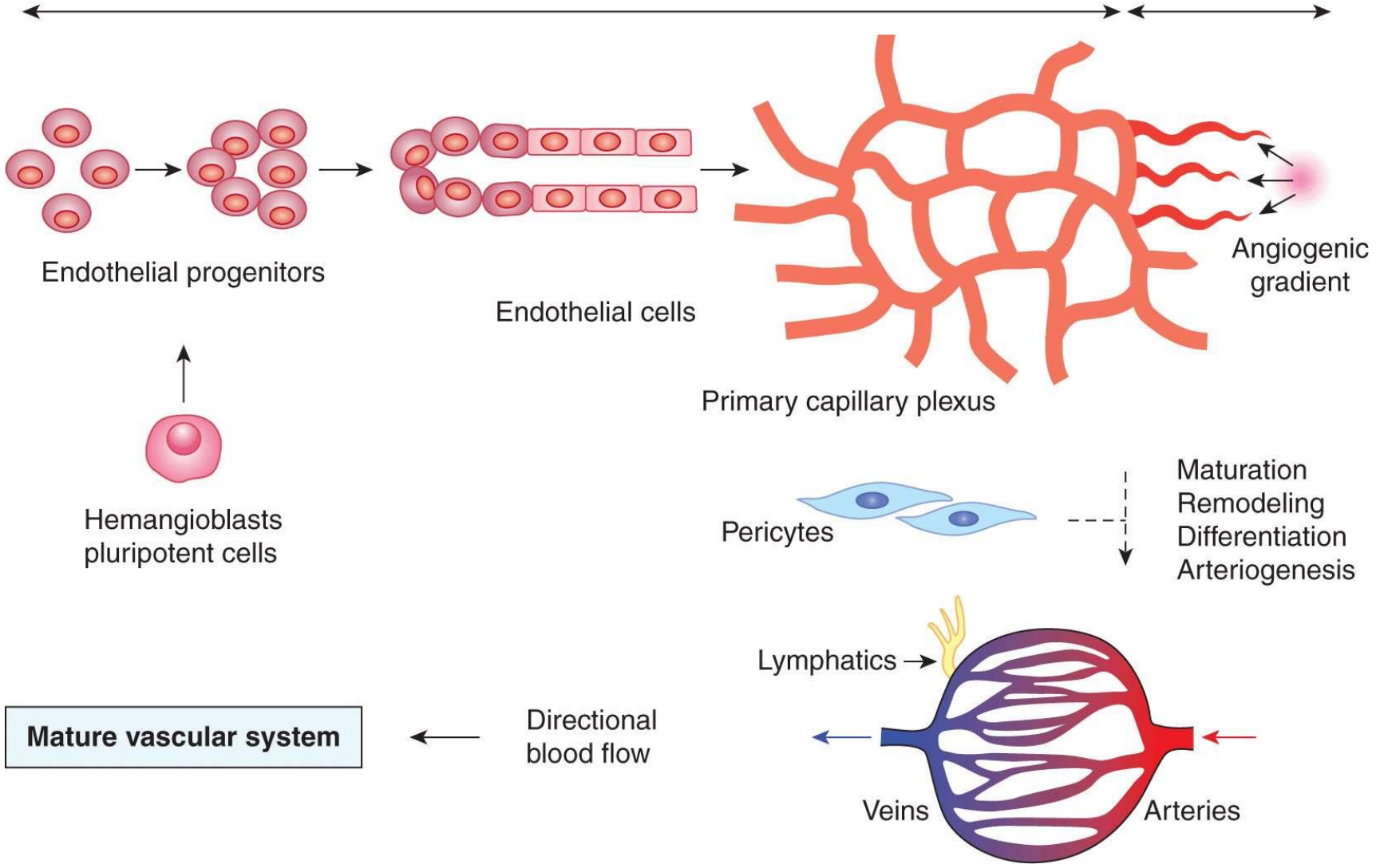


# Esplácnico

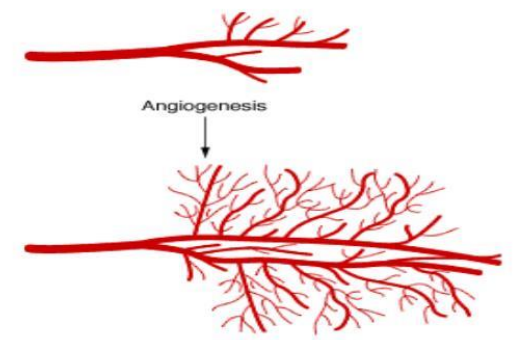
Todo el sistema cardiovascular

Vasculogenesis

Angiogenesis

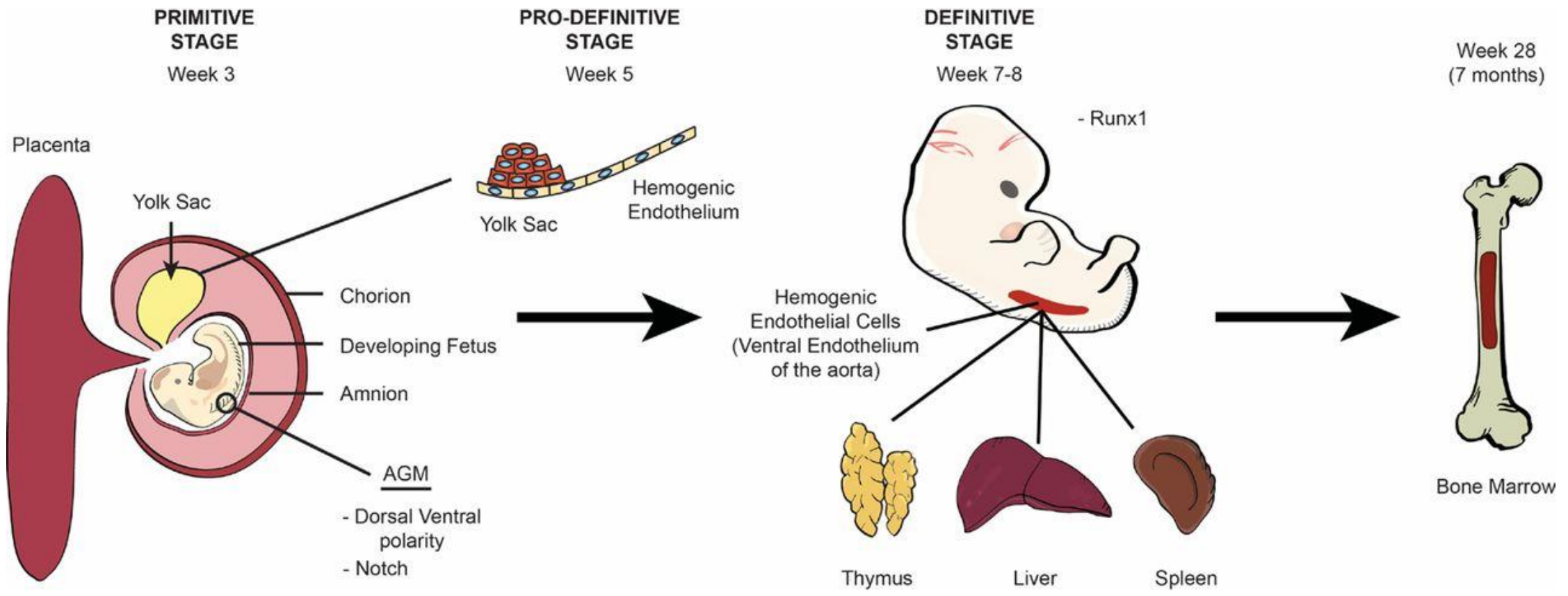


## Angiogenesis



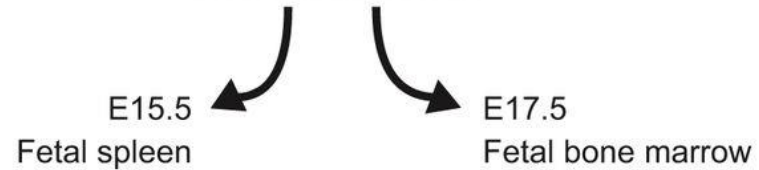
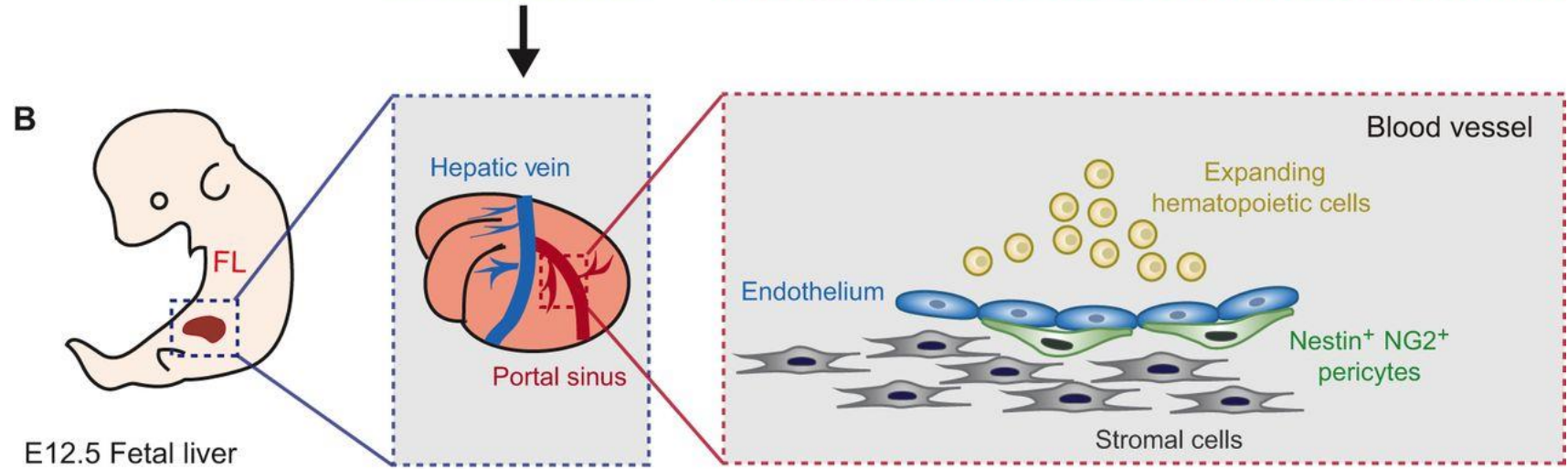
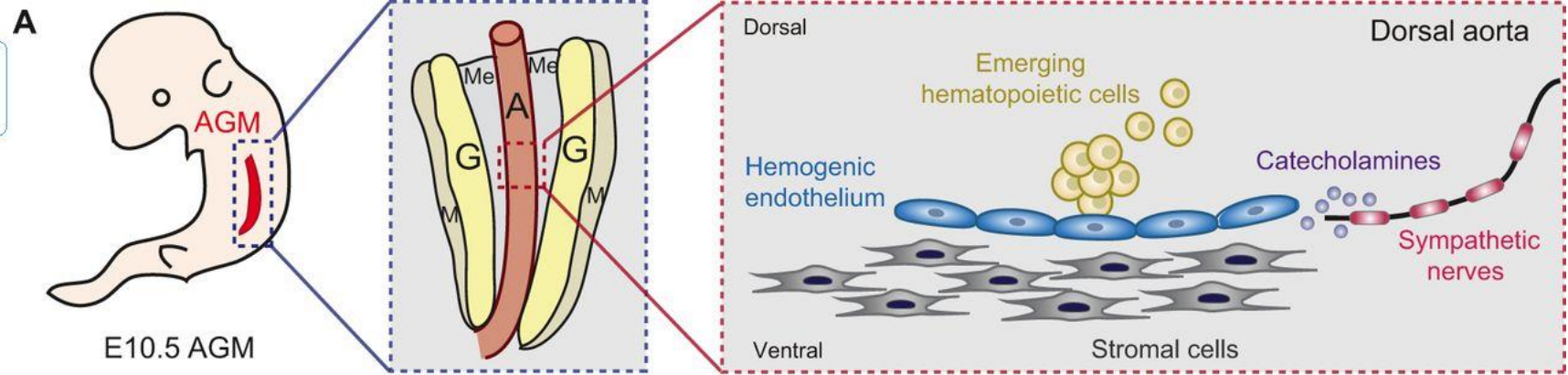
# Esplácnico

Todo el sistema cardiovascular



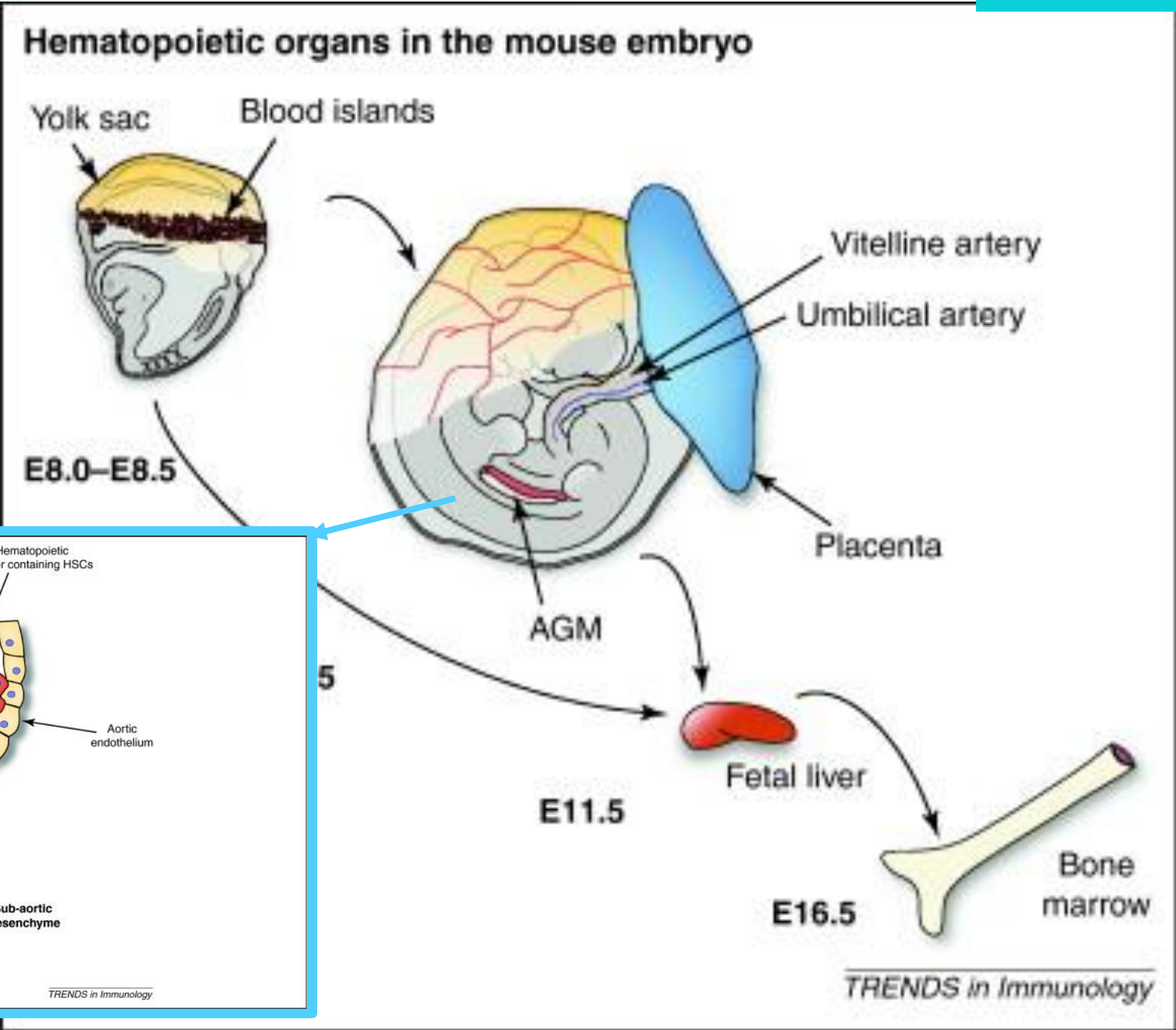
# Esplácnico

Todo el sistema cardiovascular



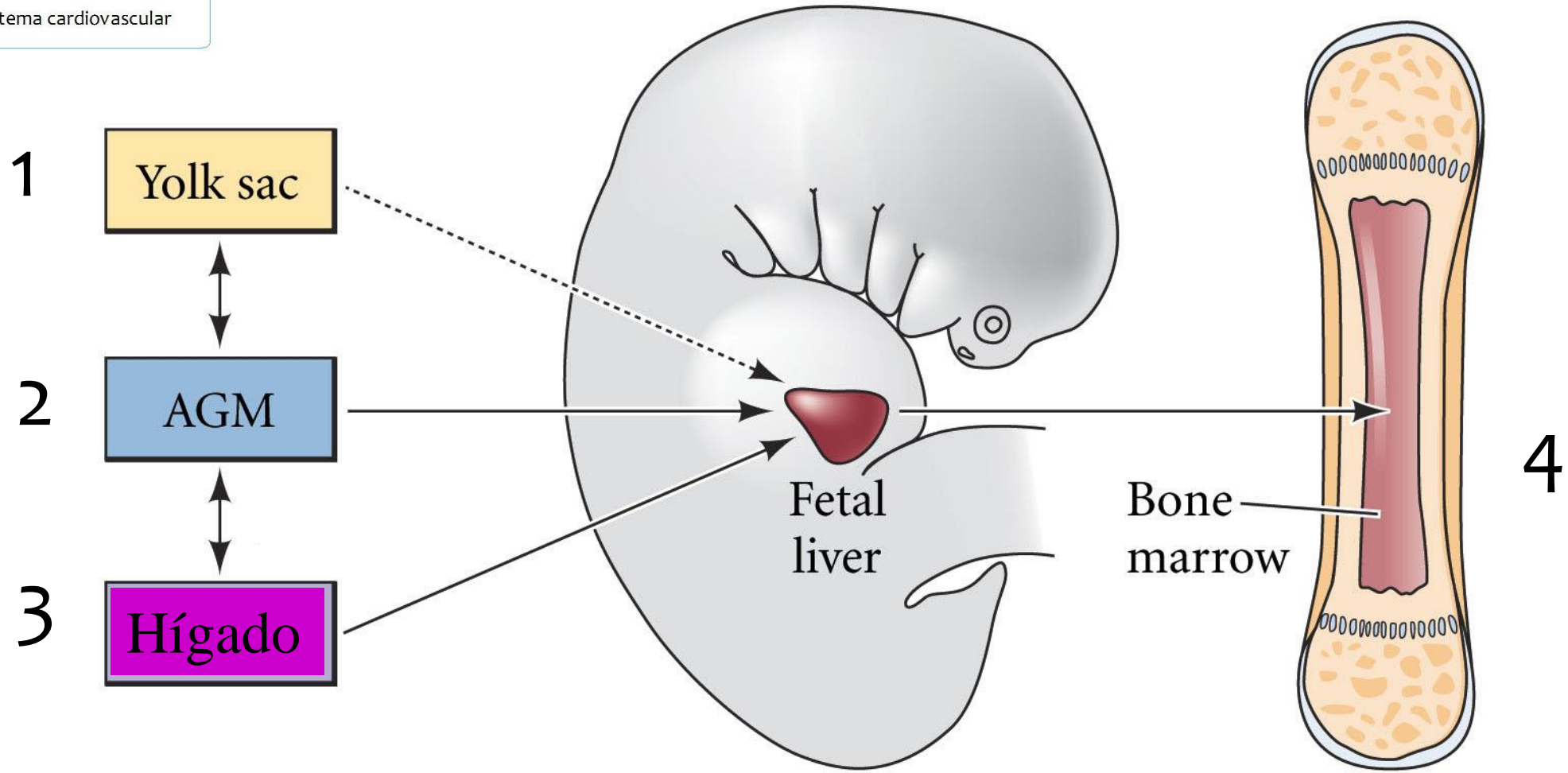
# Esplácnico

Todo el sistema cardiovascular

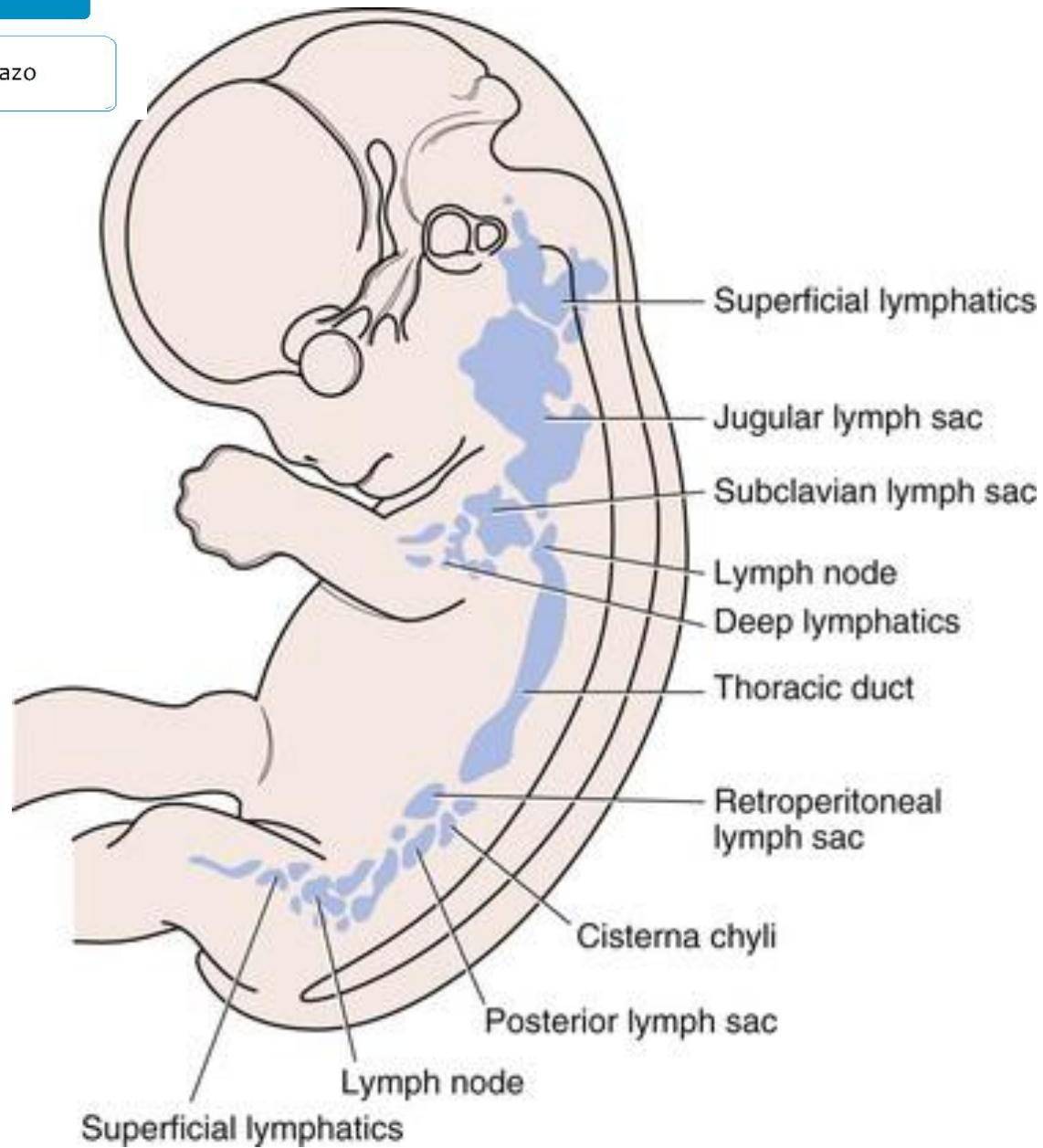


# Esplácnico

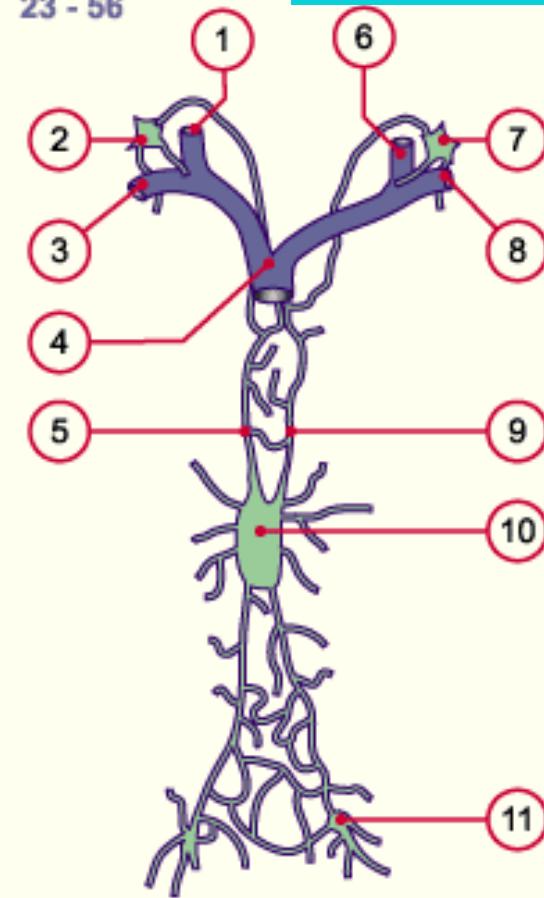
Todo el sistema cardiovascular







23 - 56



1. Right jugular vein Right jugular and axillary lymphatic plexus
2. Subclavian vein
3. Superior vena cava
4. Right thoracic duct
5. Left jugular vein
6. Left jugular and axillary lymphatic plexus
7. lymphatic plexus
8. Left subclavian vein
9. Left thoracic duct
10. Cysterna chyli
11. Inguinal lymphatic plexus



