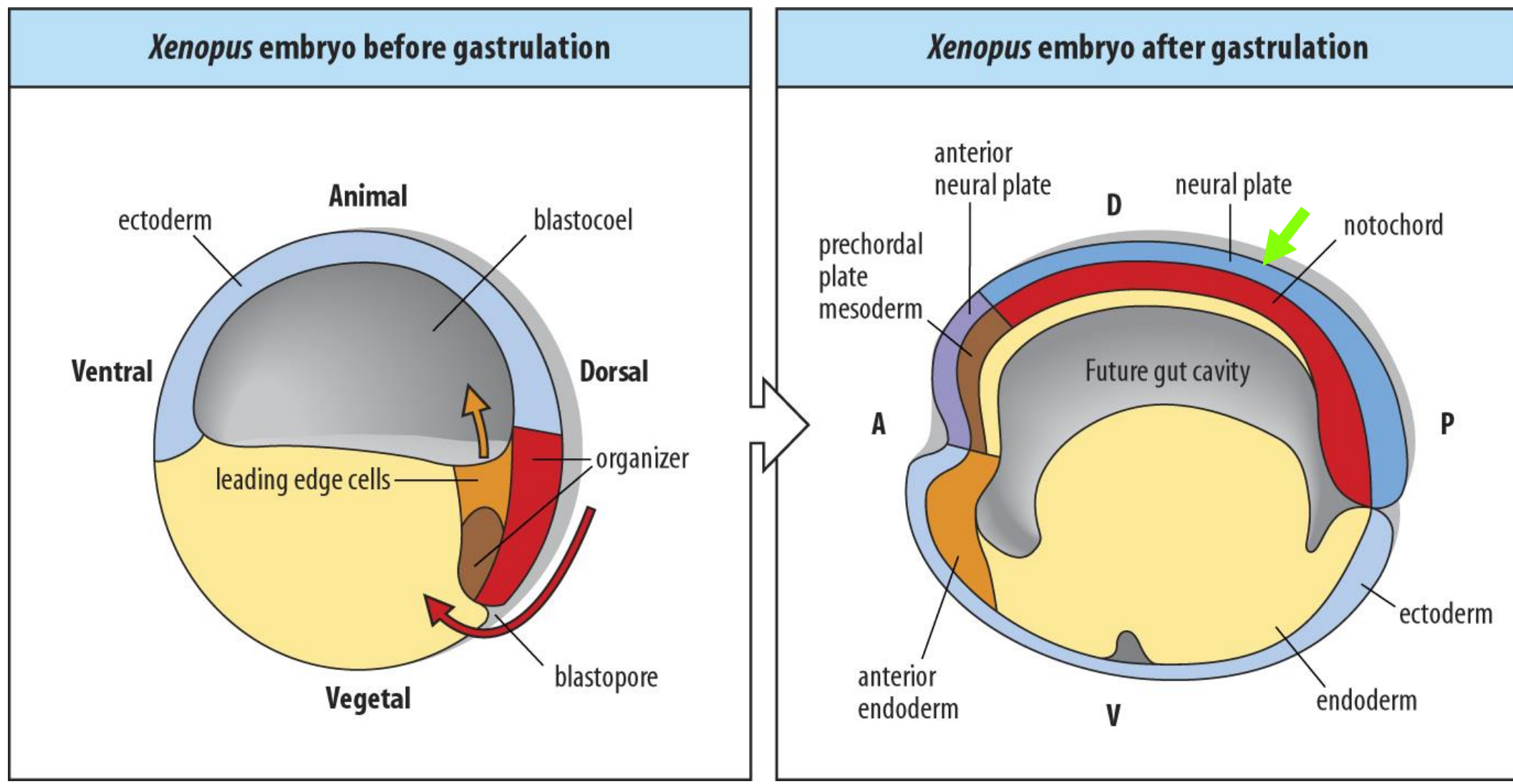
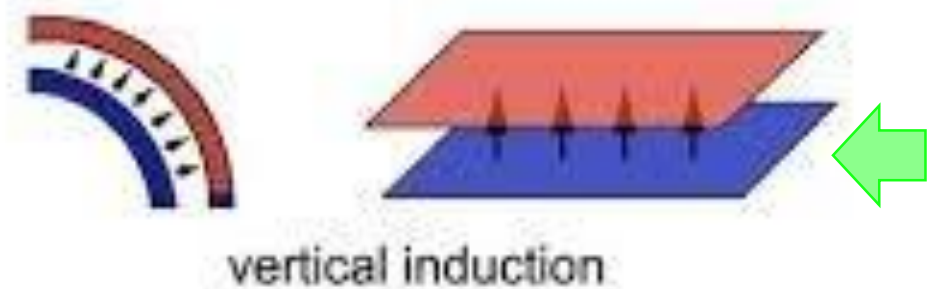
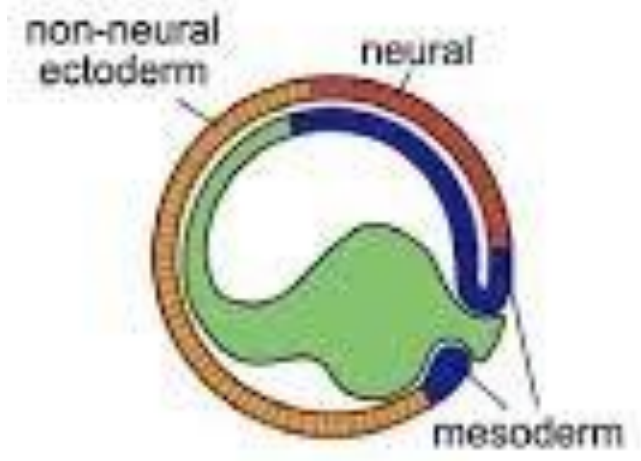


Neurulación

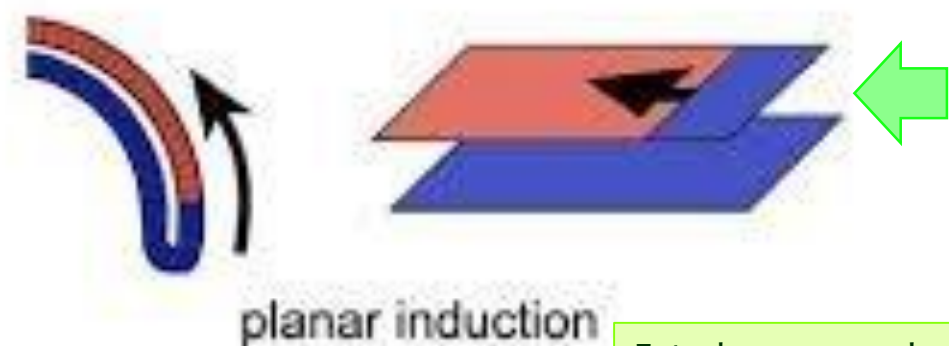



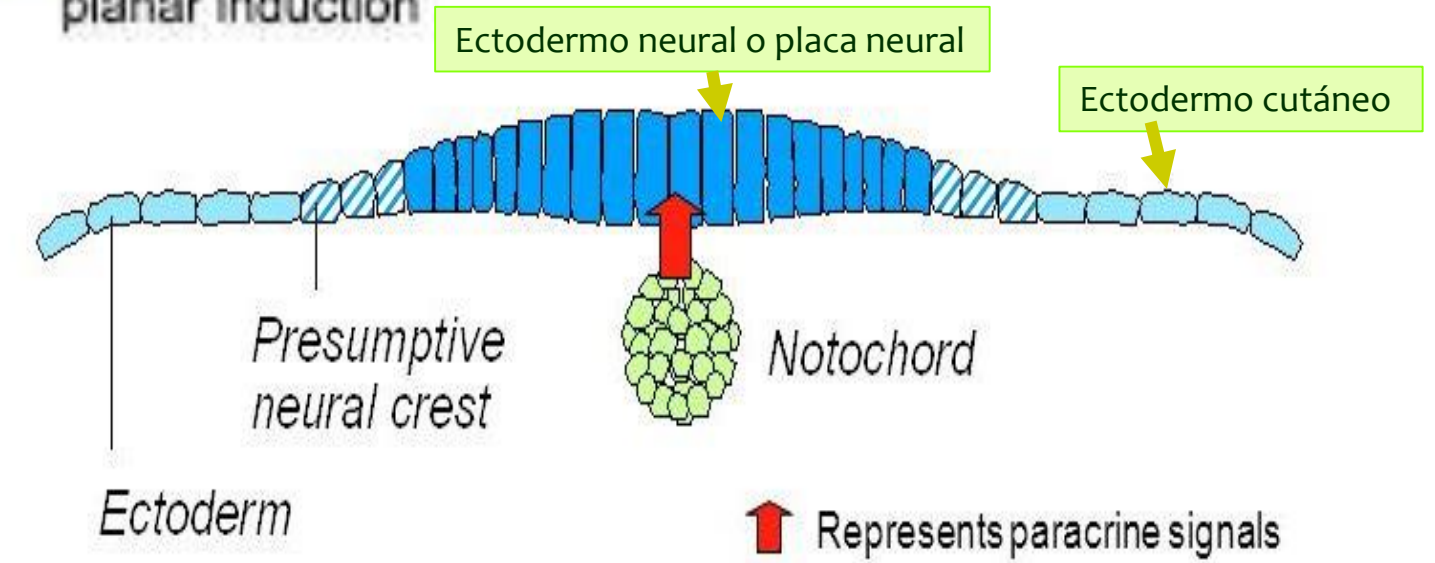
Inducción neural

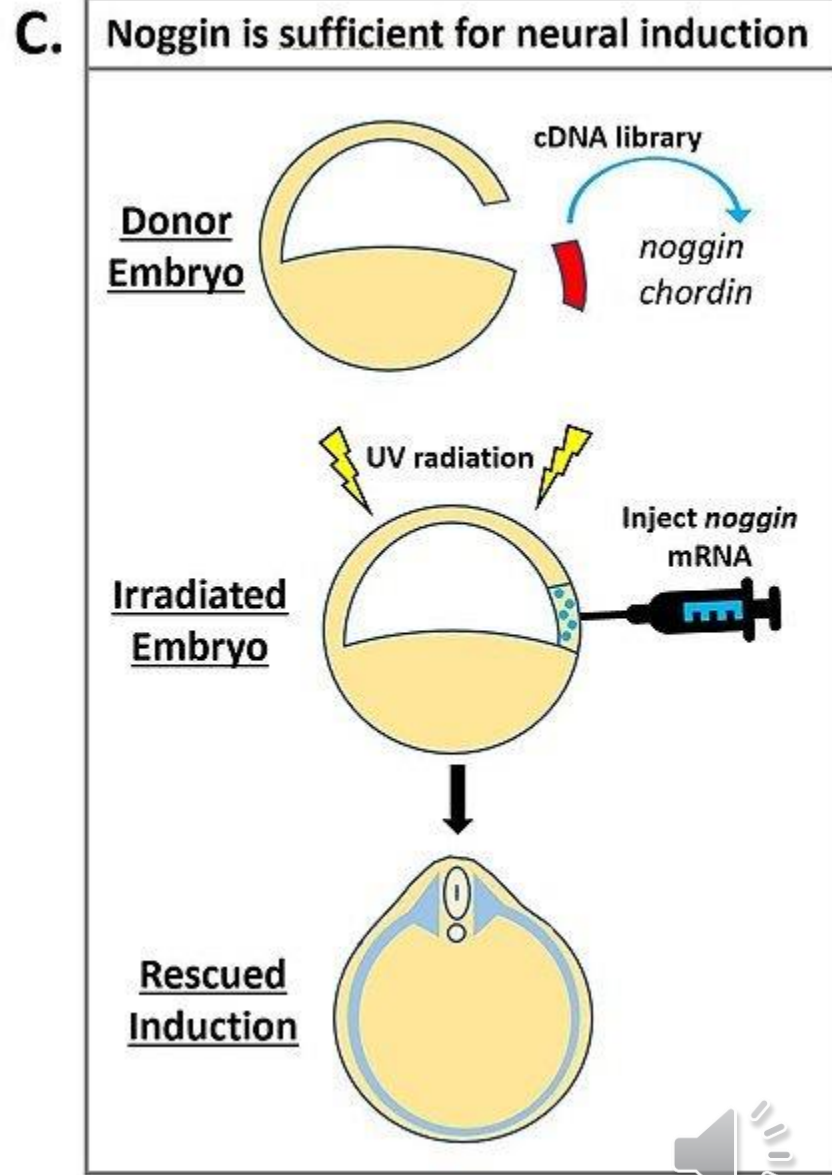
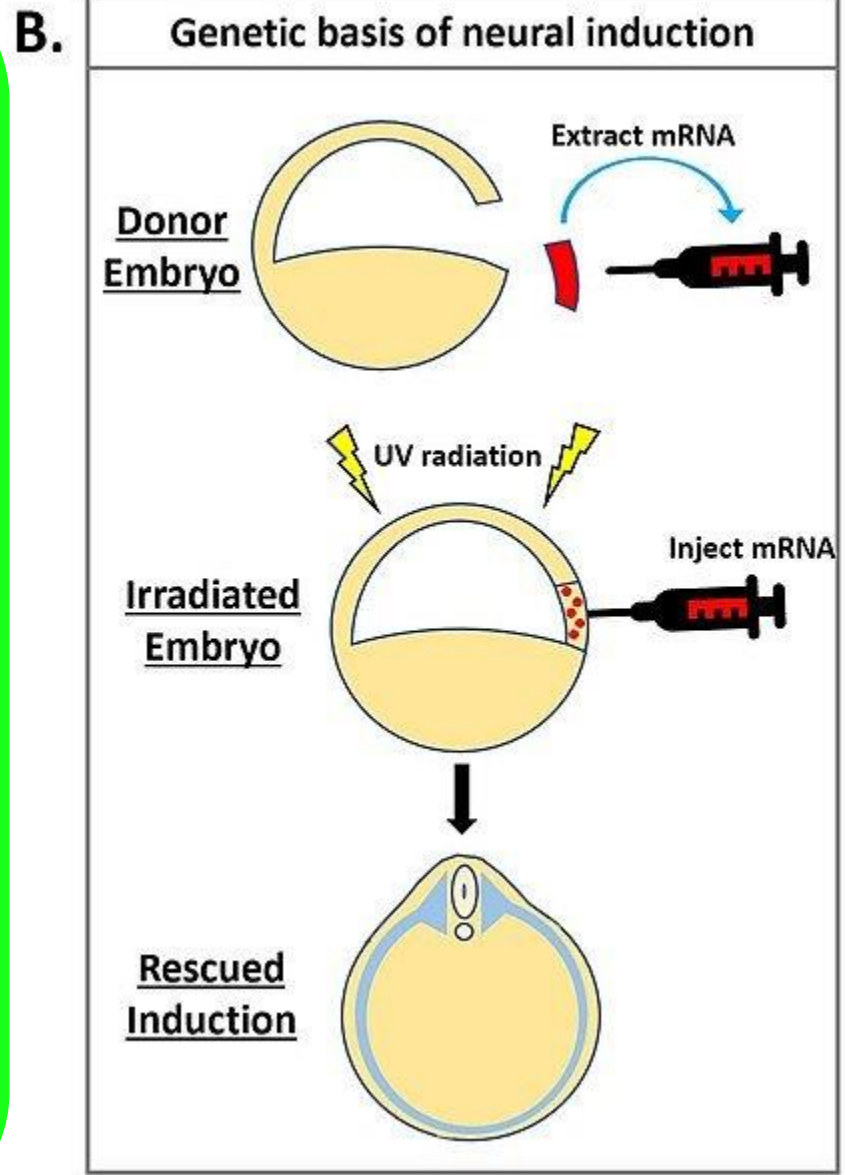
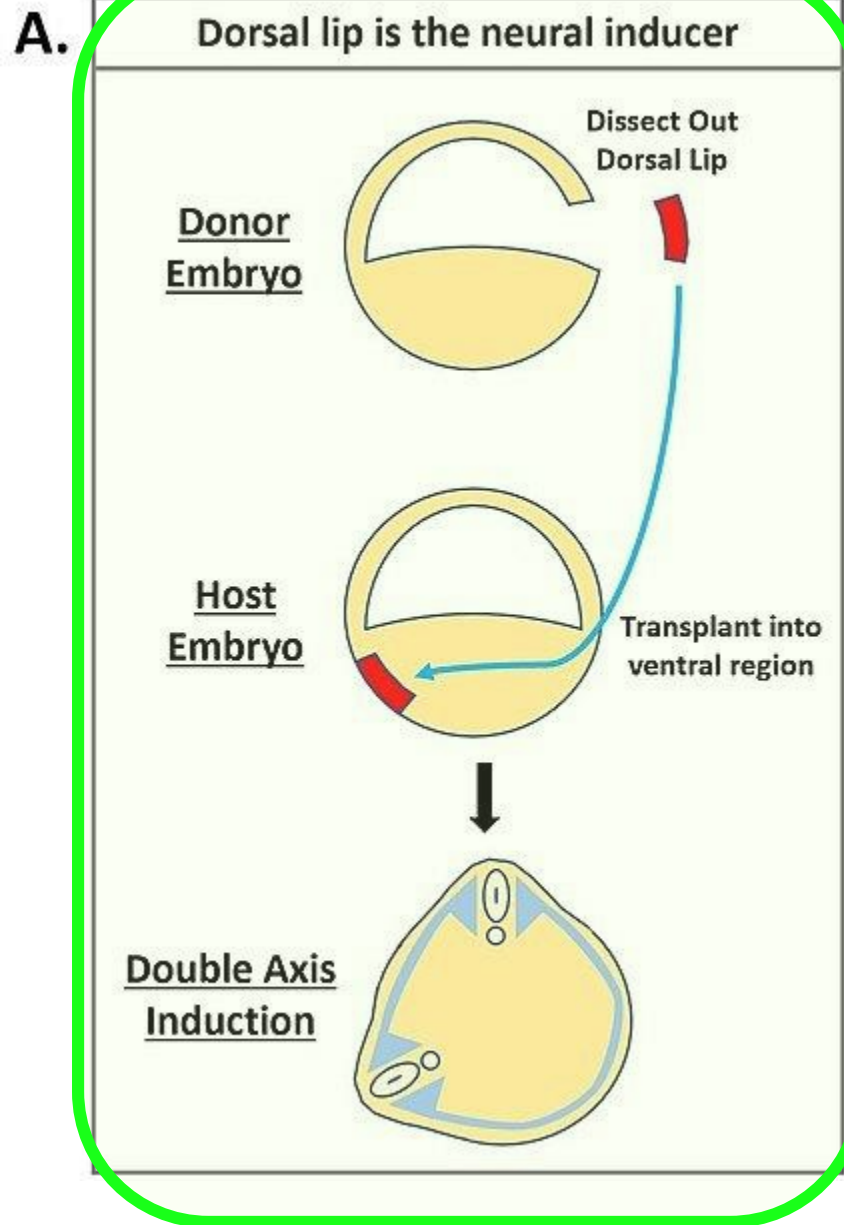


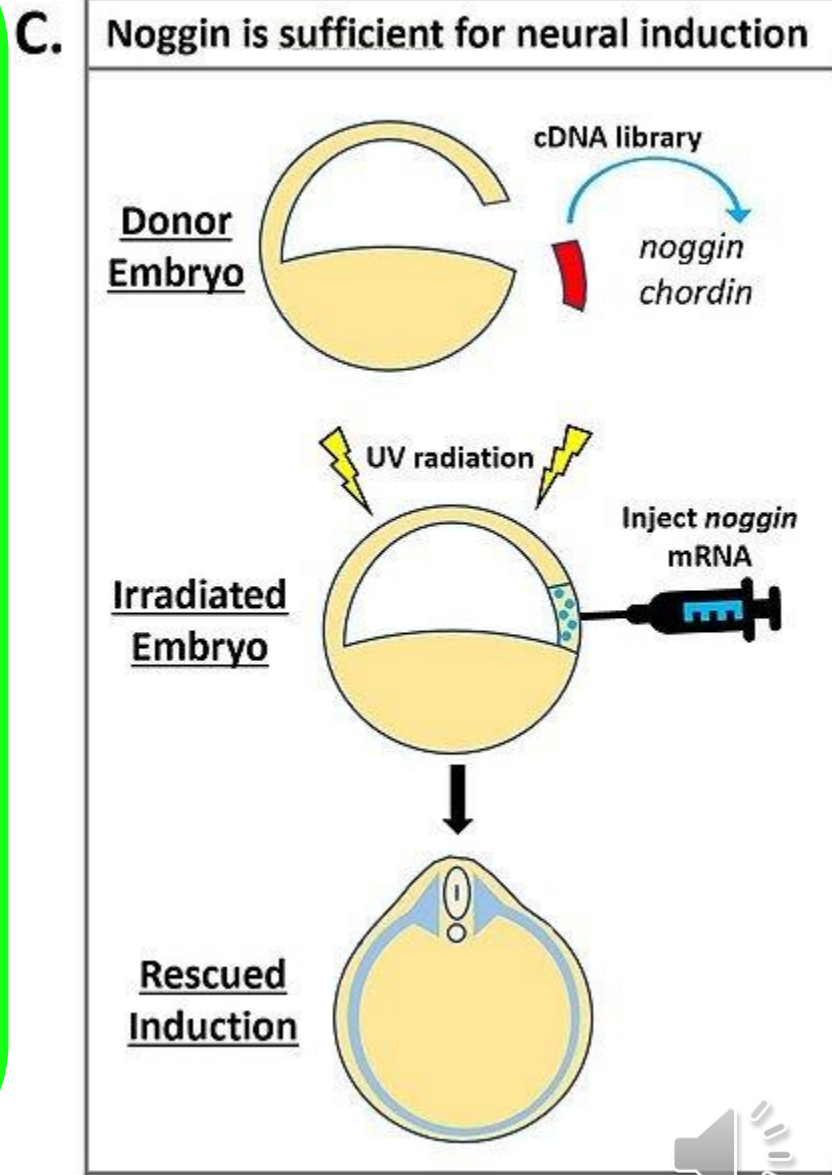
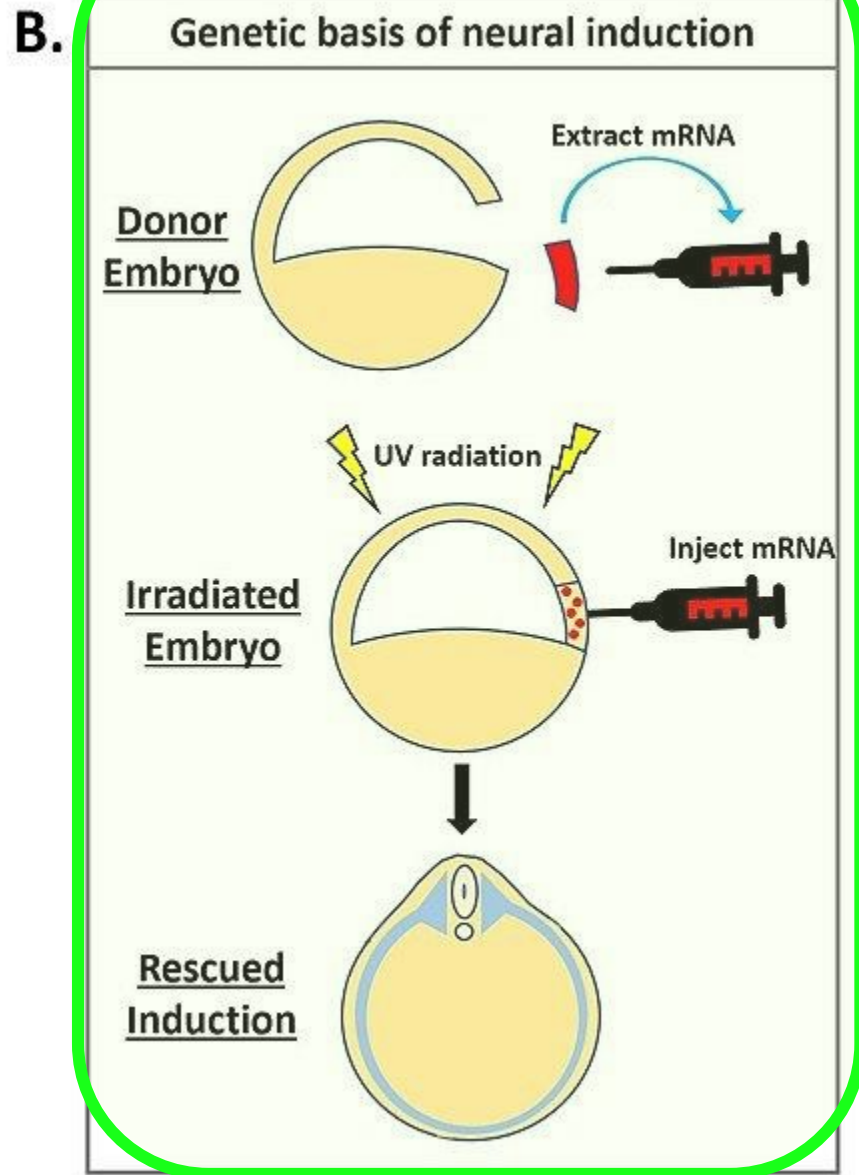
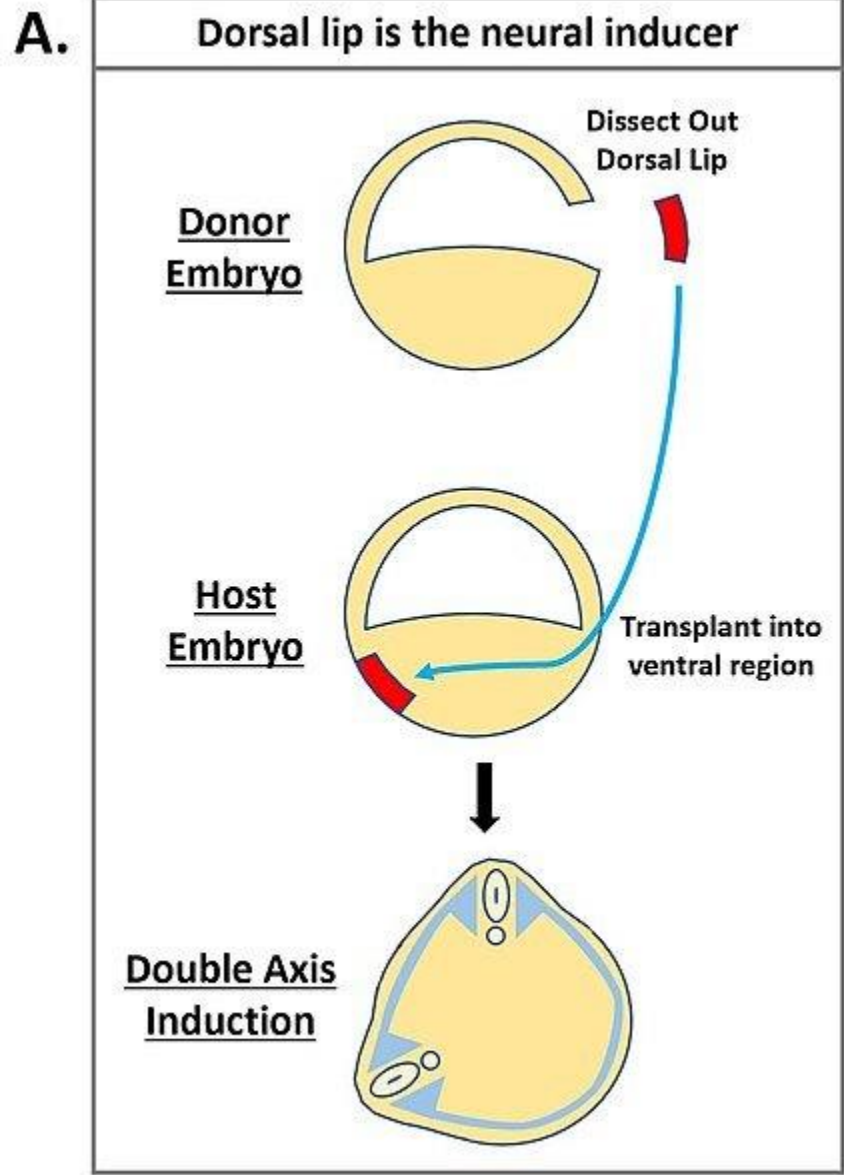
Señales que van del notocordo al ectodermo suprayacente: **inducción neural**

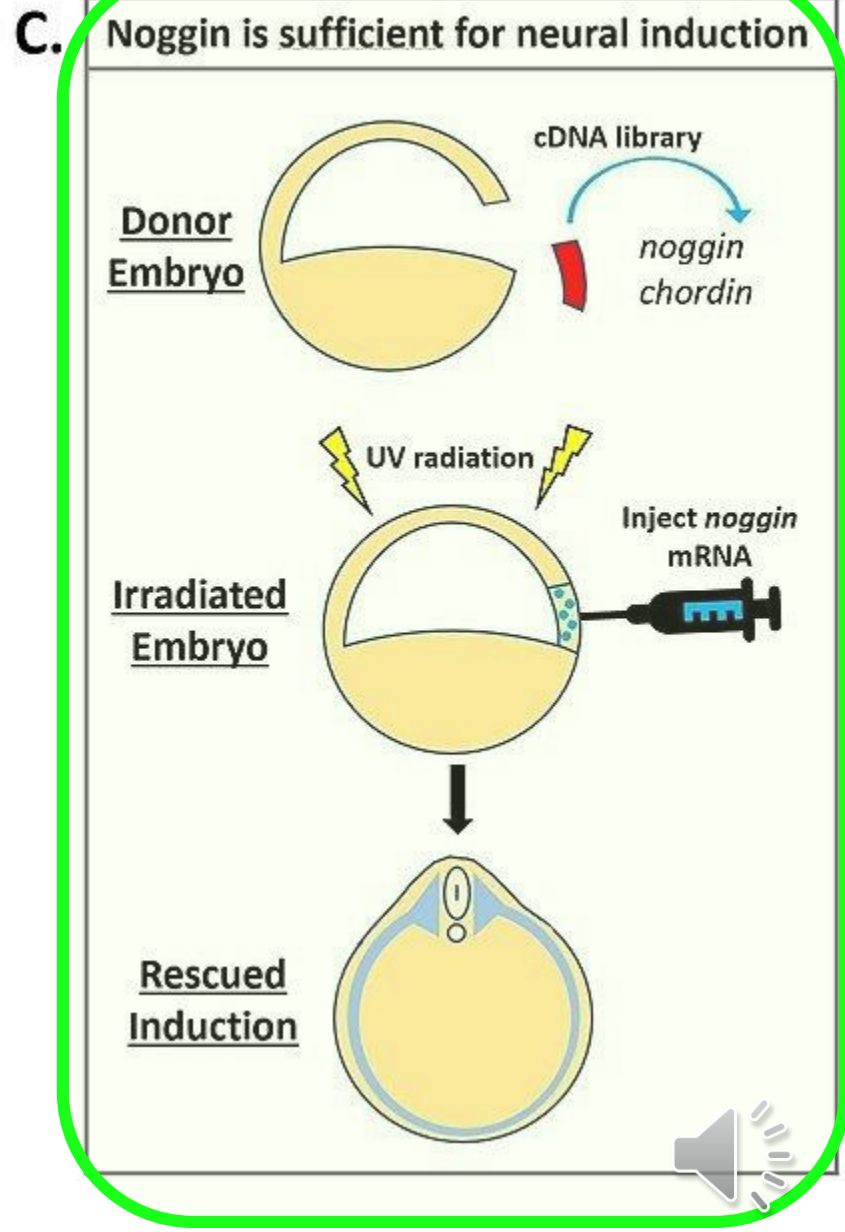
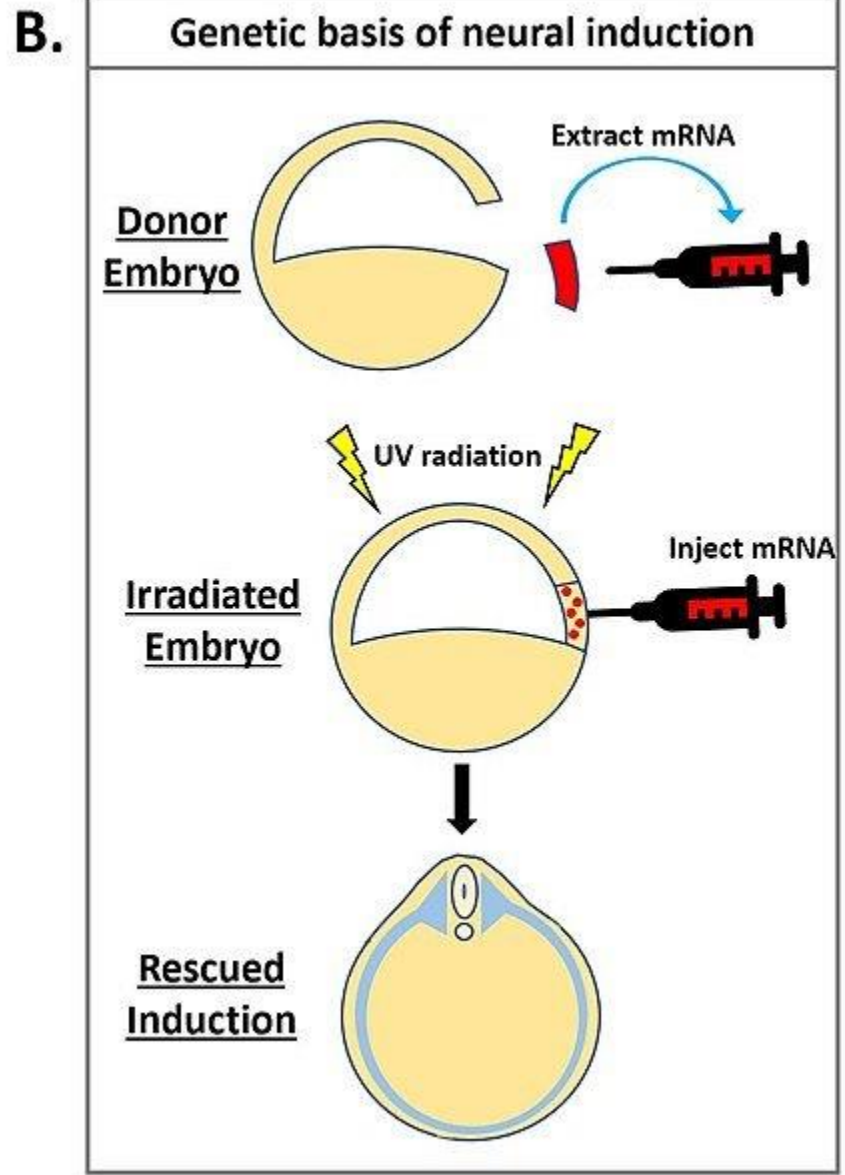
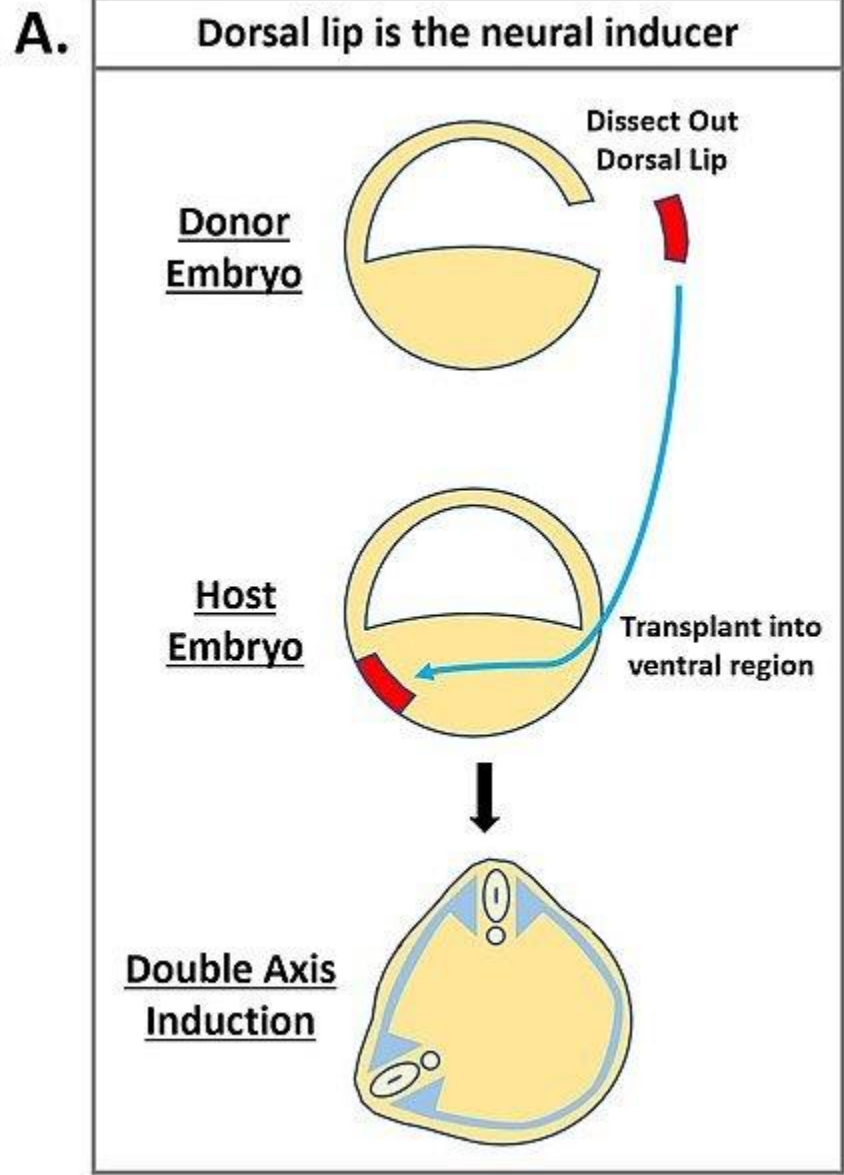


Señales que van del organizador por el ectodermo suprayacente al notocordo: **regionalización neural**









Placa neural

The diagram illustrates the process of neural induction. It features three stacked rectangular boxes on the left. The top box is dark green and labeled 'Placa neural'. The middle box is a lighter green and labeled 'Ectodermo suprayacente'. The bottom box is a light tan color and labeled 'Notocordio'. Two grey arrows point upwards from the middle and bottom boxes towards the top box. To the right of these boxes, a large green curly bracket spans the vertical extent of the middle and bottom boxes. Further to the right, a green rectangular box contains the text 'Inducción neural'. In the bottom right corner of the slide, there is a small grey speaker icon.

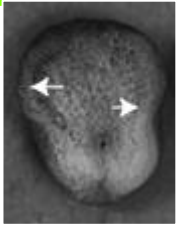
Ectodermo
suprayacente

Notocordio

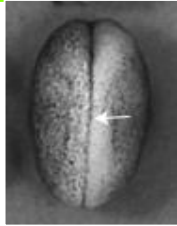Inducción
neural



Neurulación



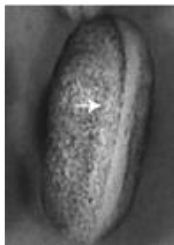Formación
placa neural



Cierre del tubo
neural



Sistema
nervioso
central



Néurula



Neurulación

Ectodermo

SNC

Epidermis

Mesodermo

Mesodermo
paraxial

Mesodermo
intermedio

Mesodermo
lateral

Endodermo

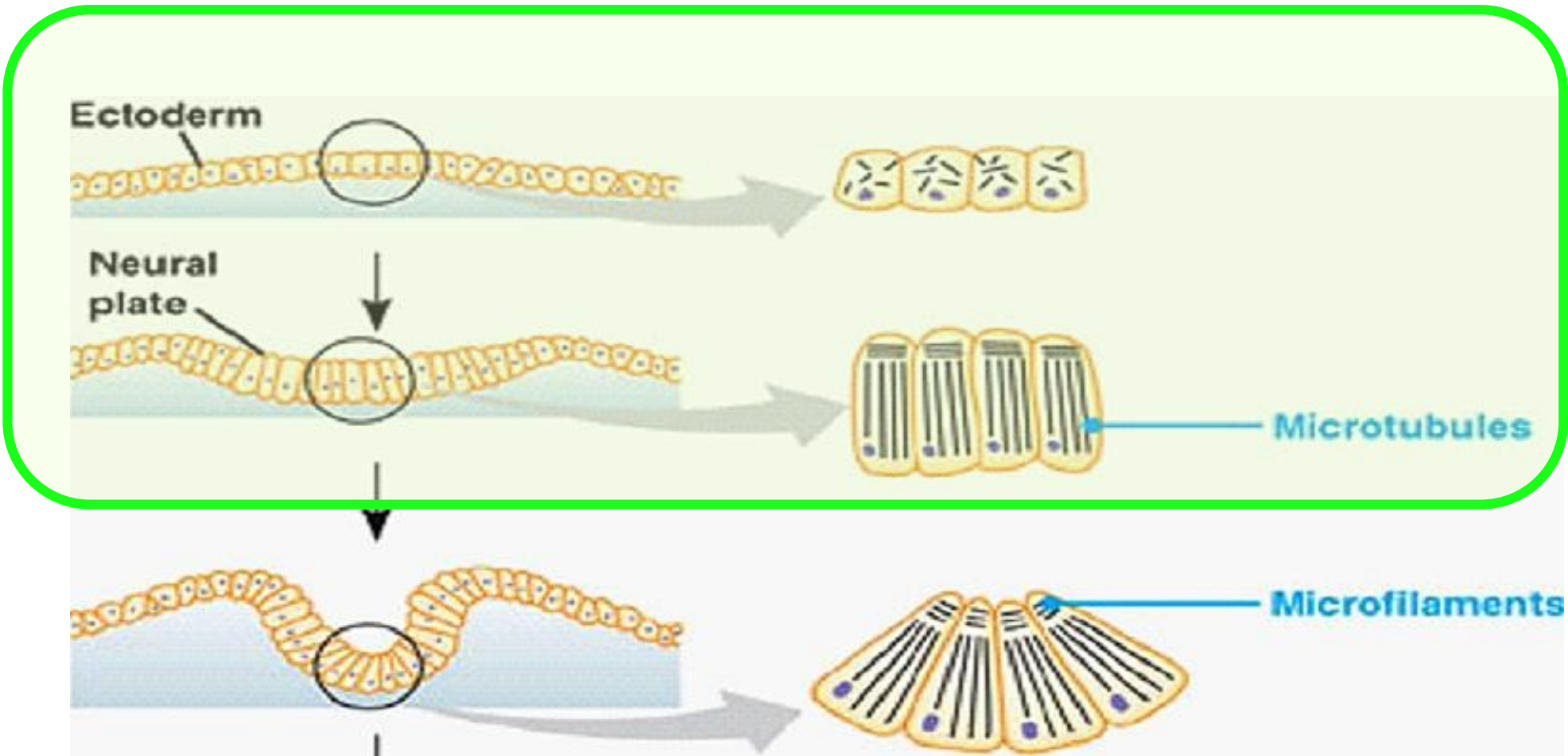
Endodermo
anterior

Endodermo
medio y
posterior

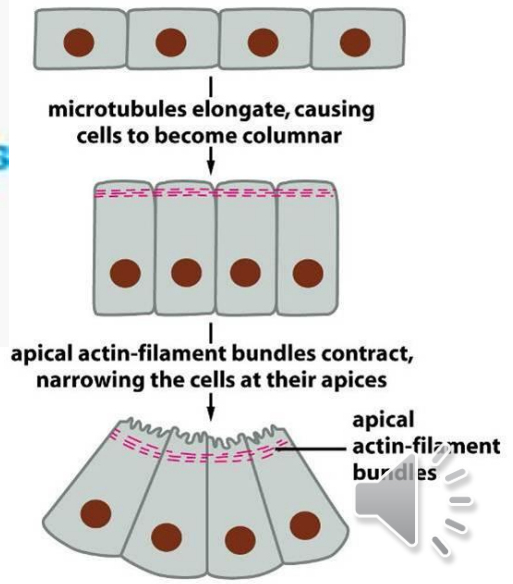
Tubo
digestivo y
derivados



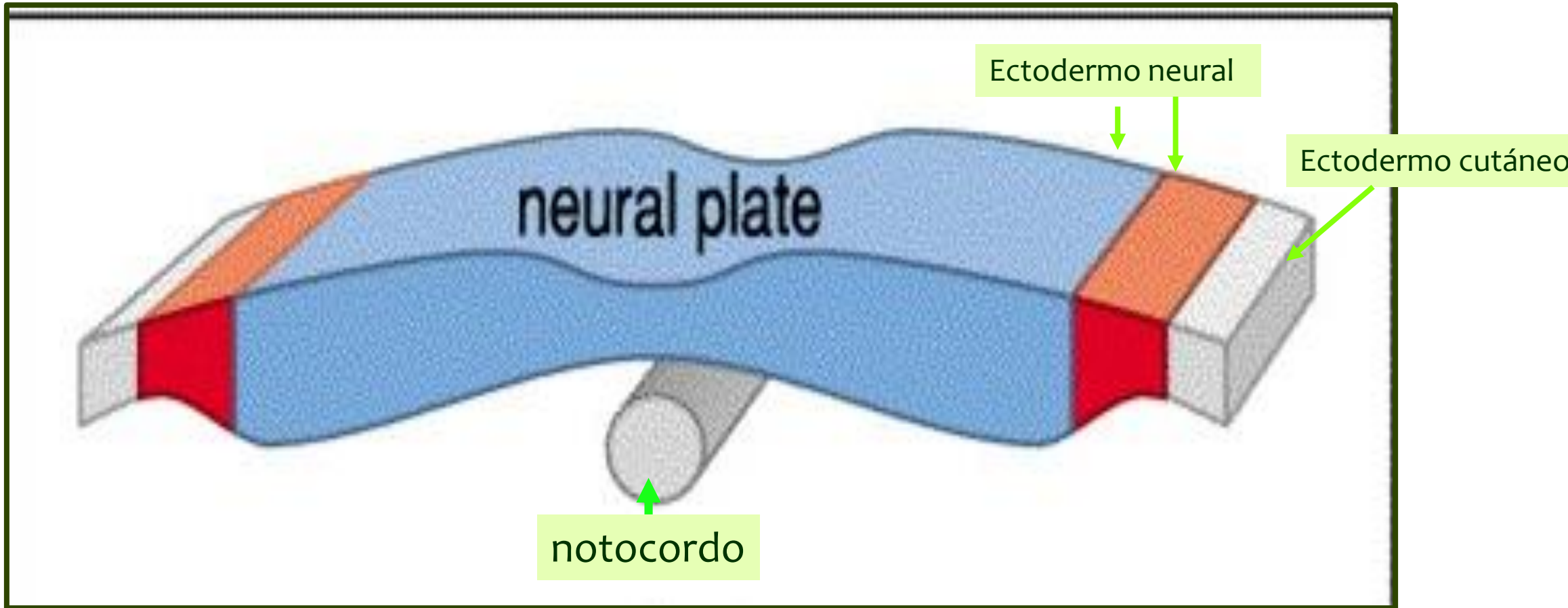
Neurulación



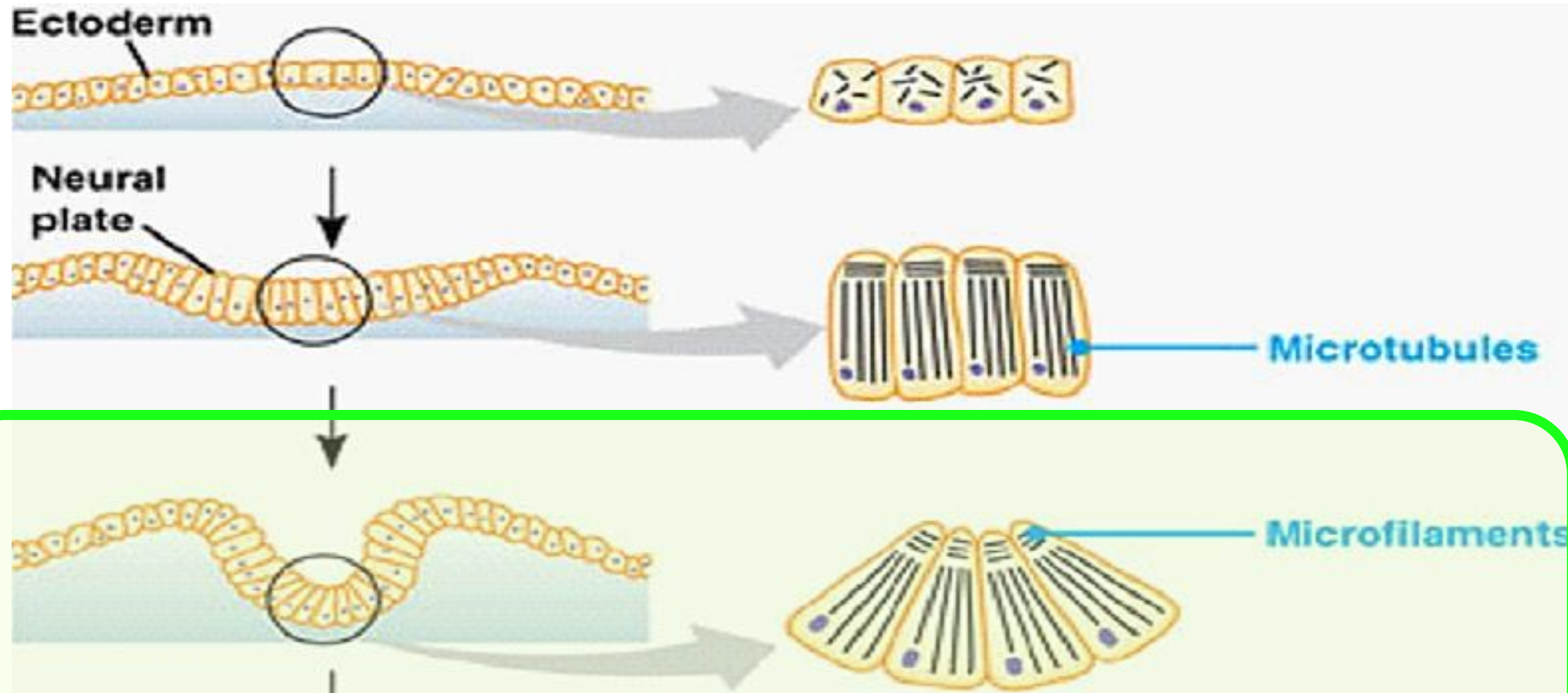
Placa neural



Neurulación




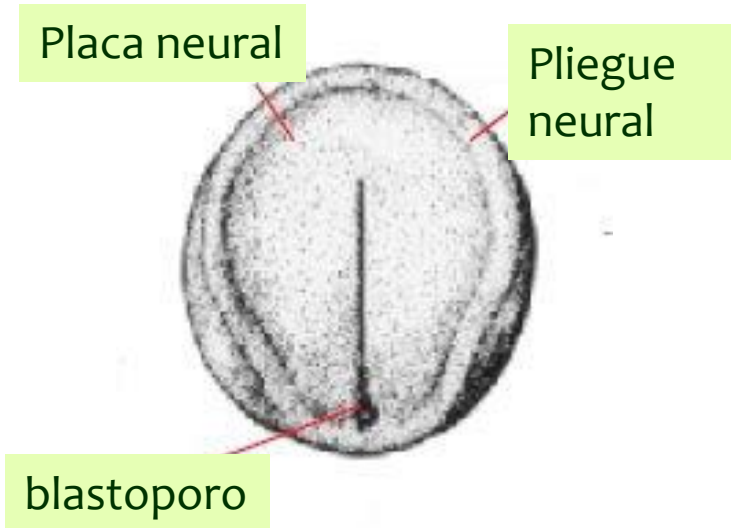
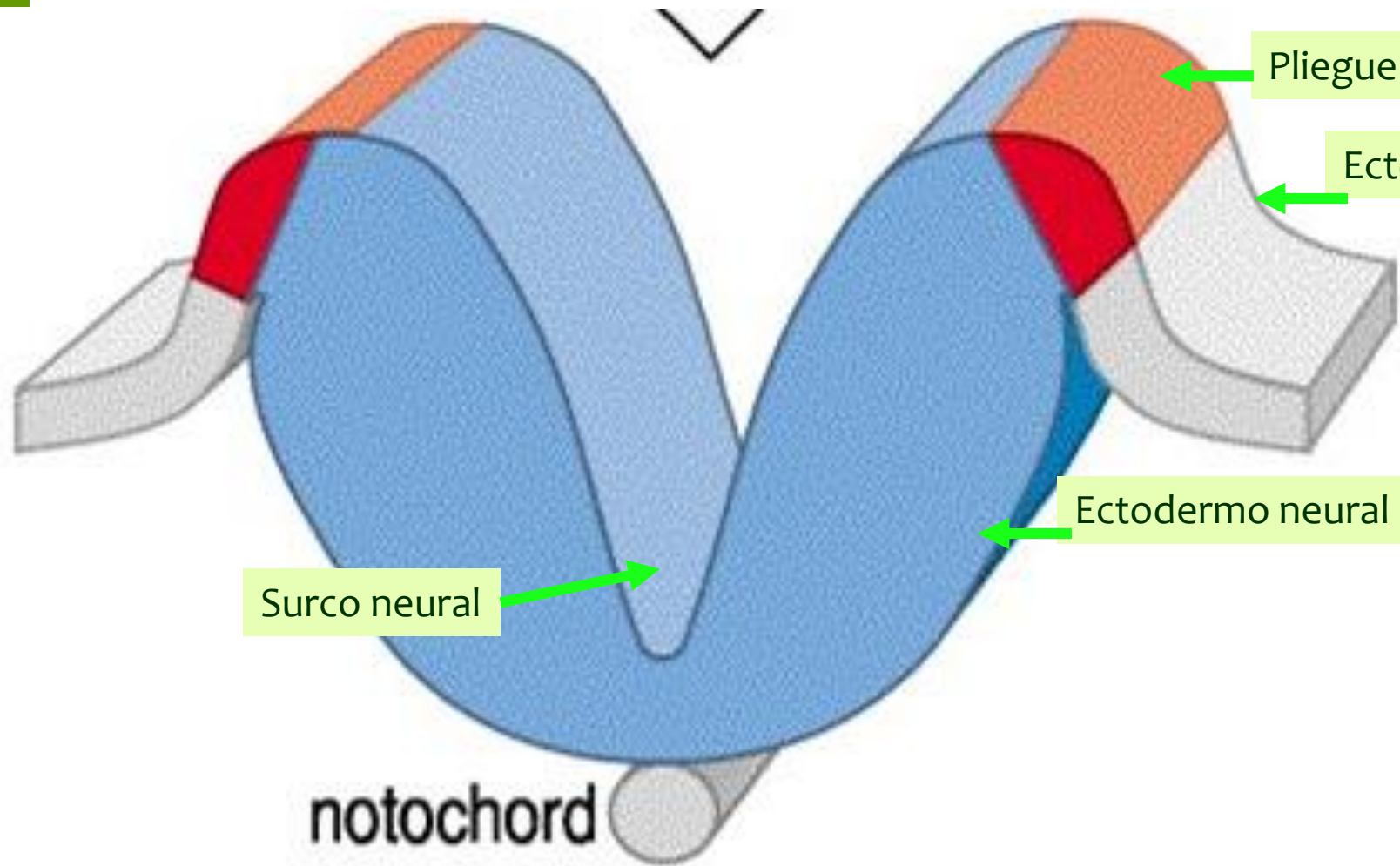
Neurulación



Surco neural

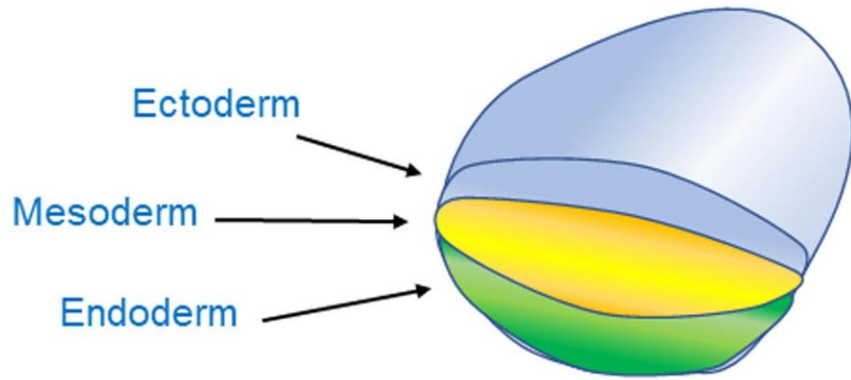


Neurulación

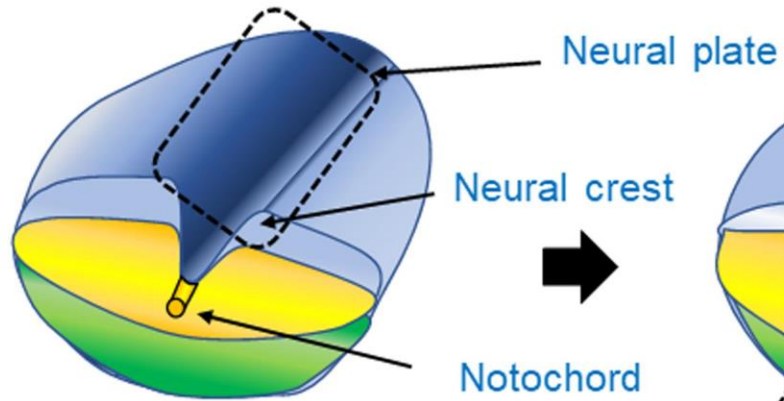


Neurulación

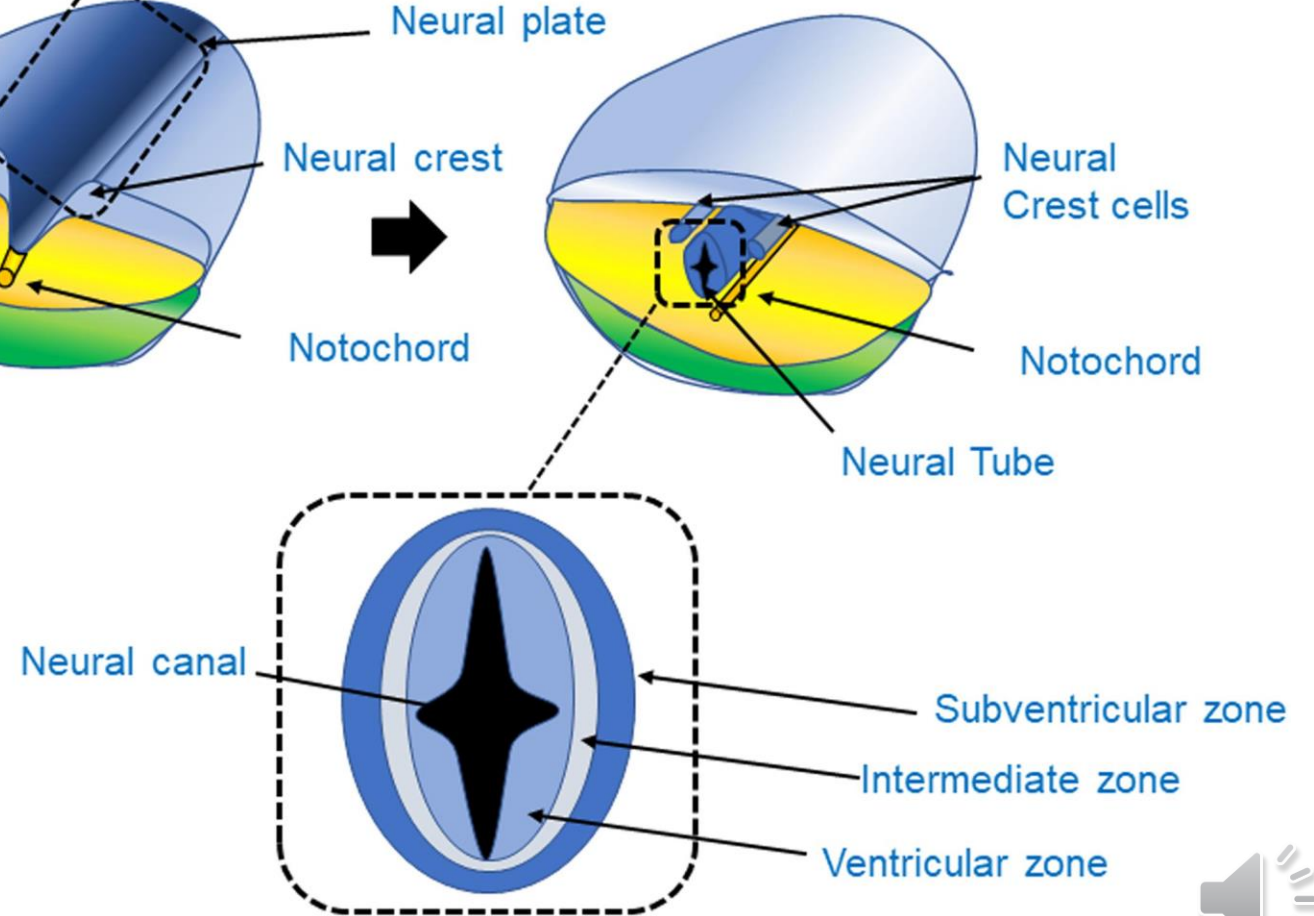
Trilaminar germ layer disc



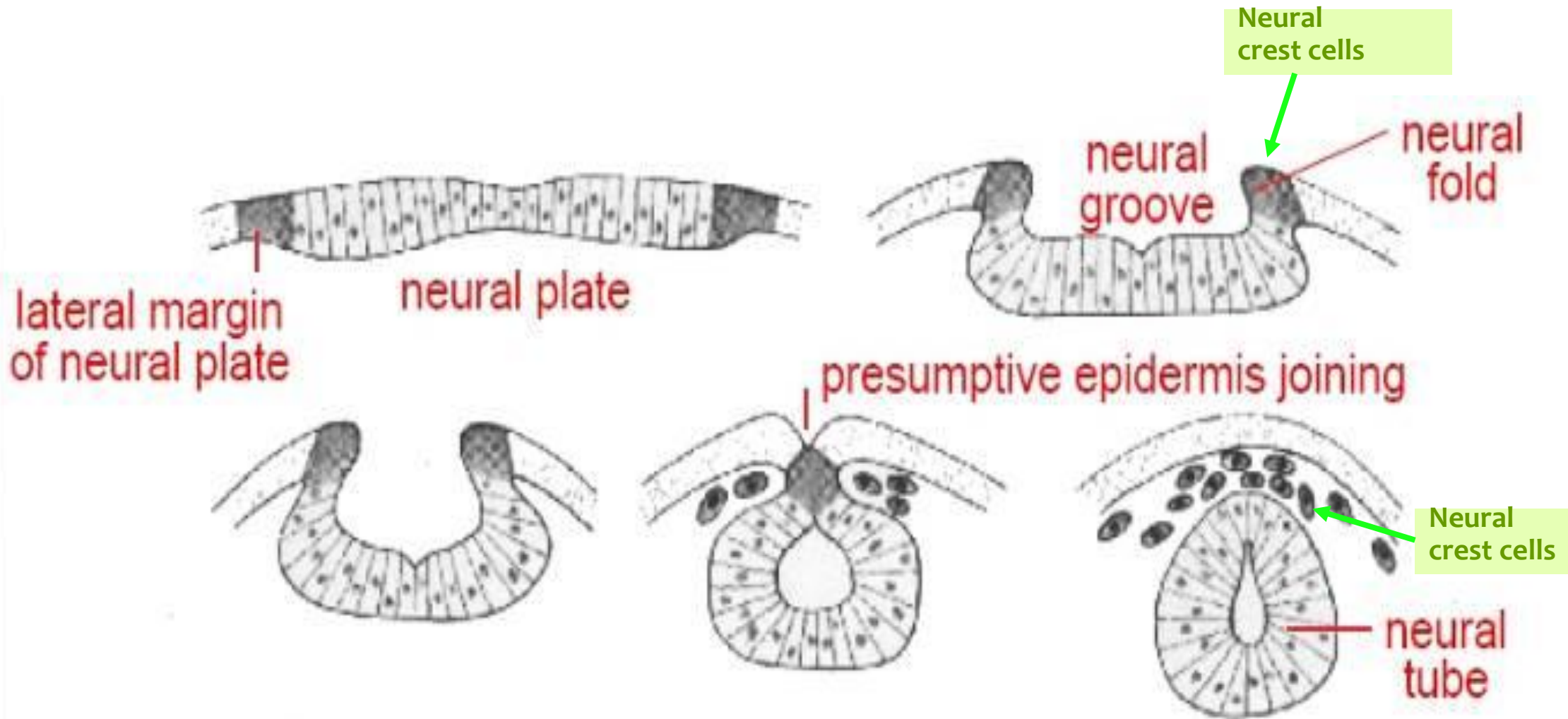
Neural induction



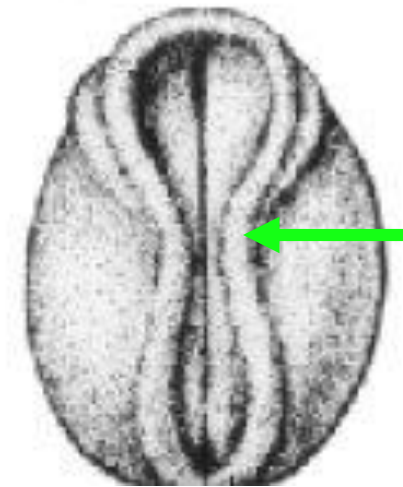
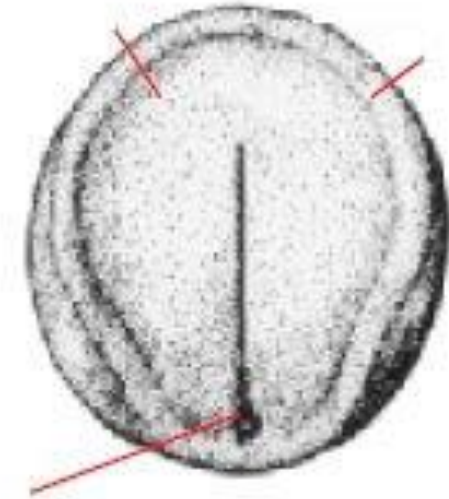
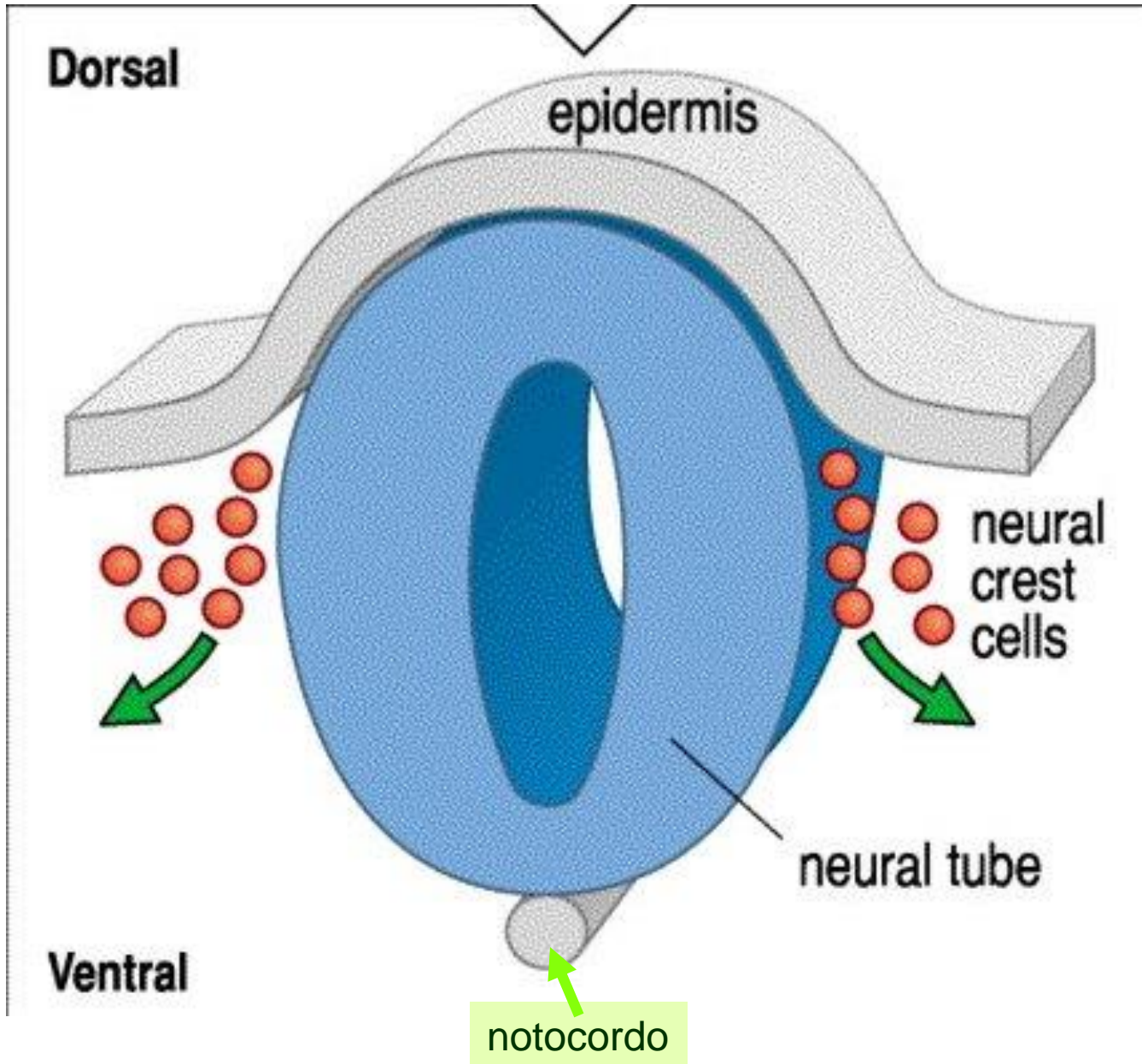
Neural tube formation



Neurulación



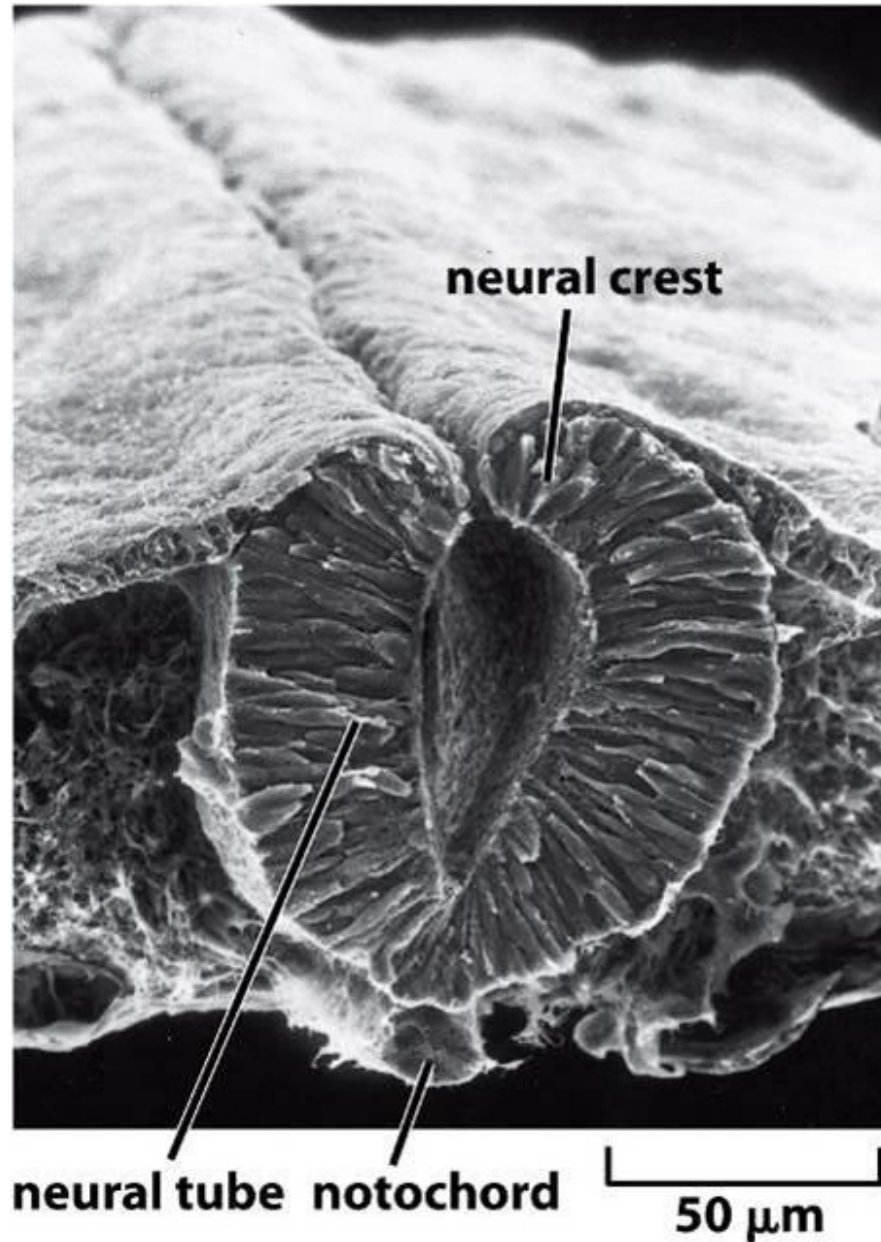
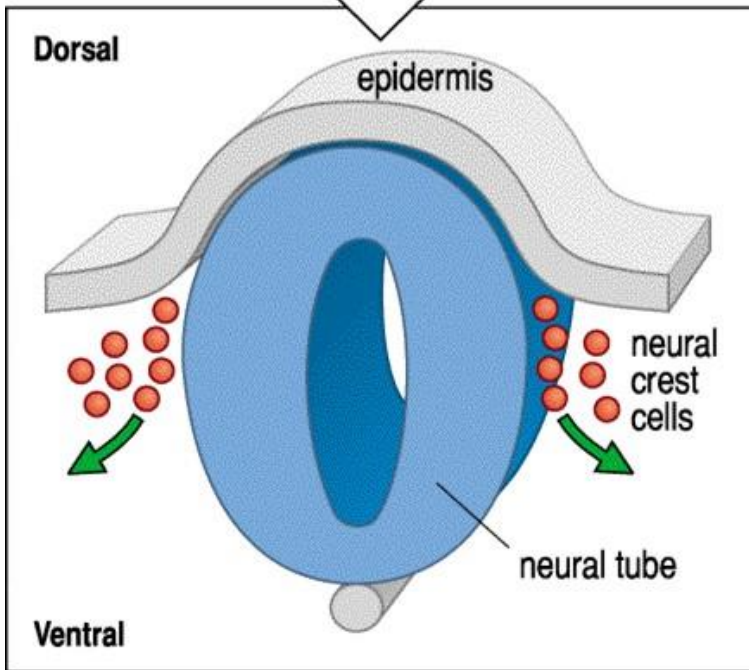
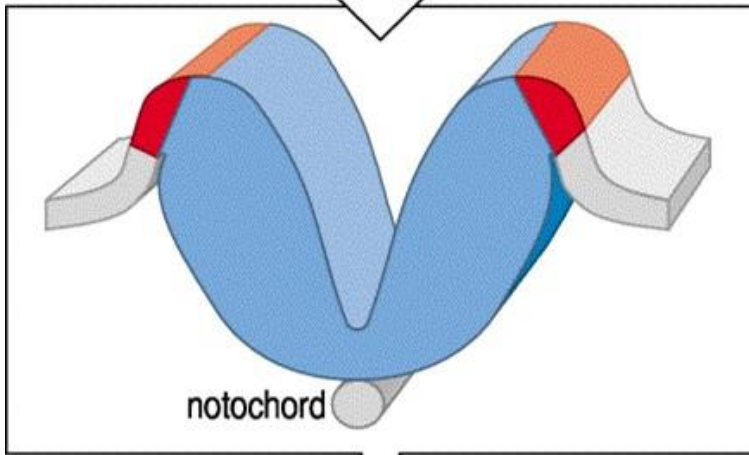
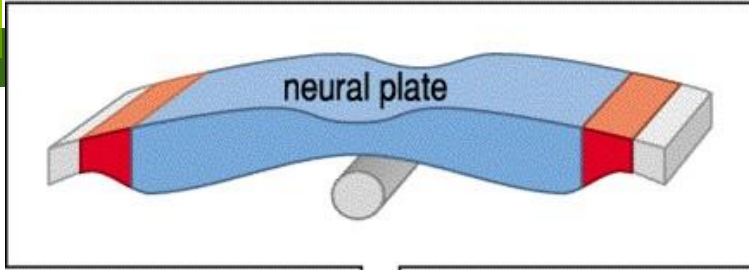
Neurulación



Punto de cierre del tubo neural



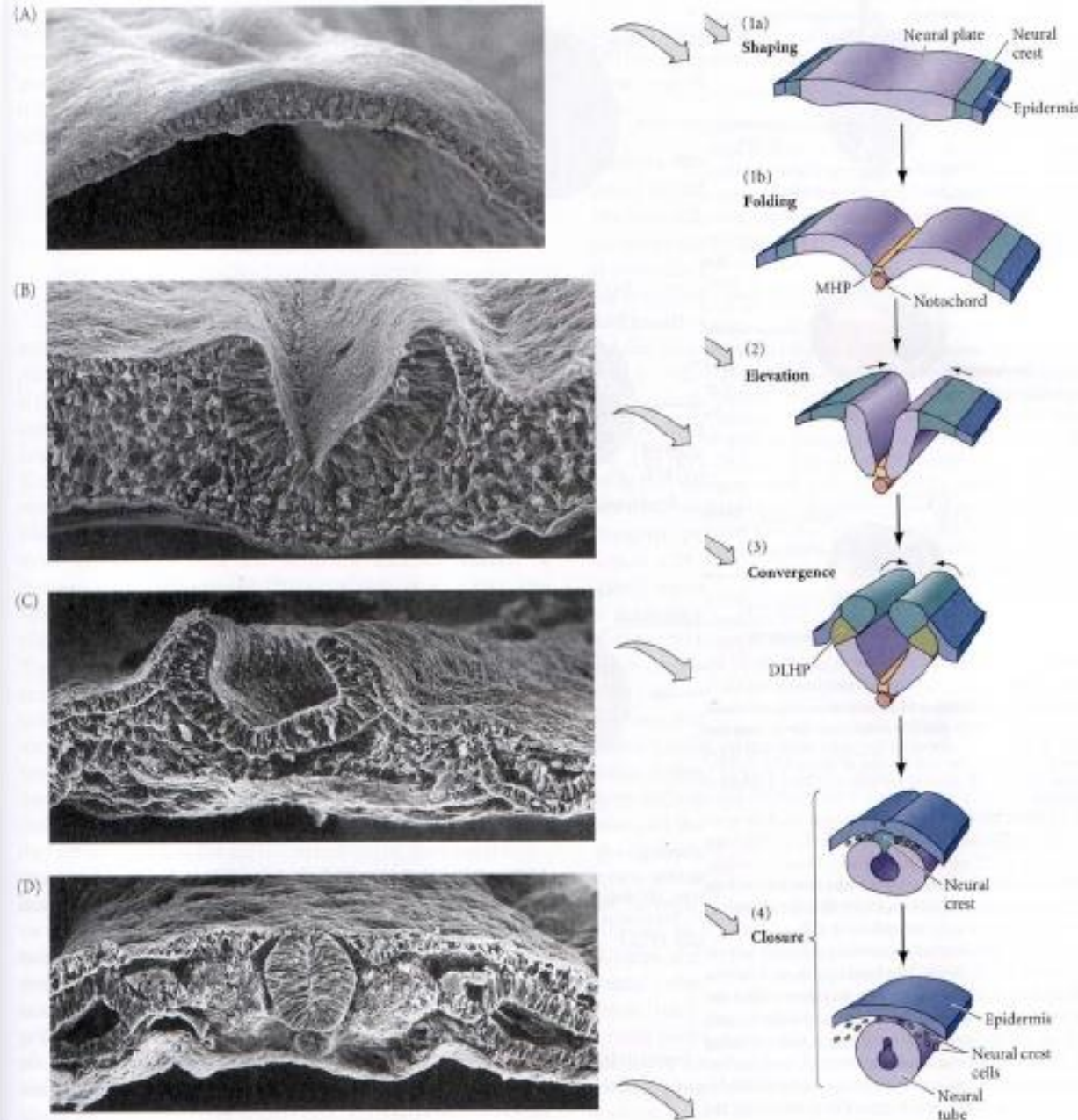
Neurulación



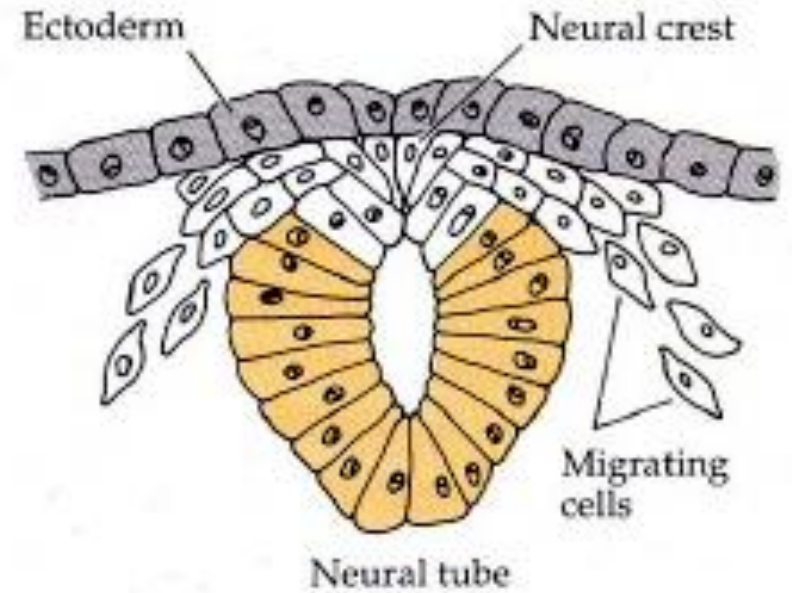
Cerramiento del tubo neural en la región troncal



Neurulación



Detailed steps in neural tube formation



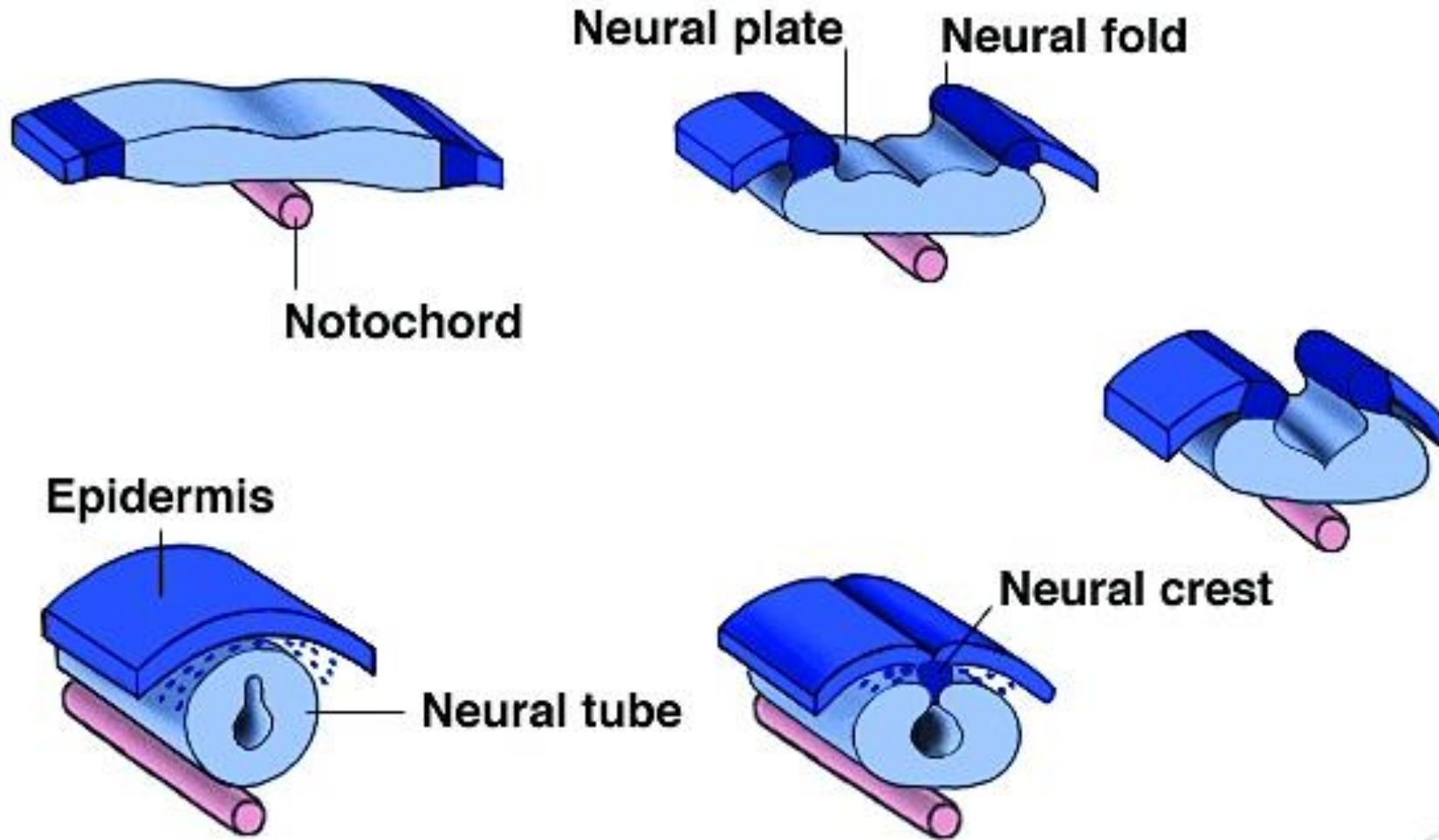
(C) **E-Cadherin**
N-Cadherin

Figure 3.17


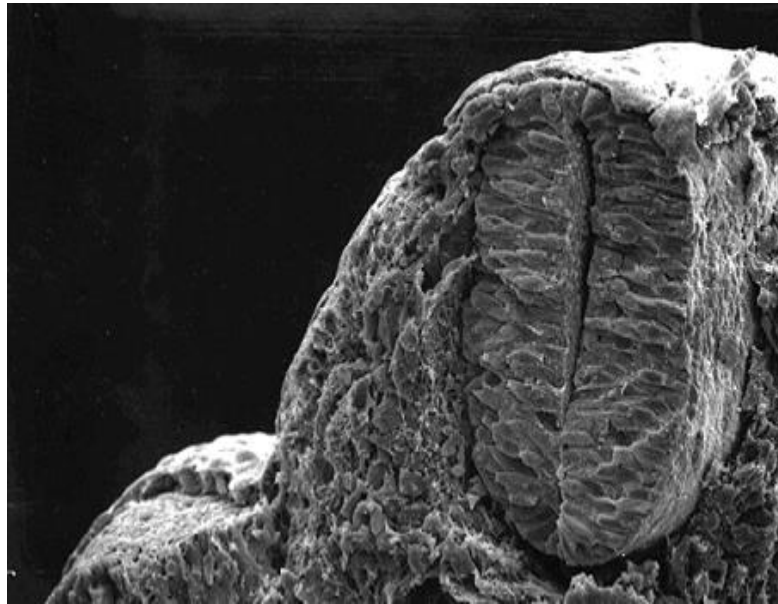
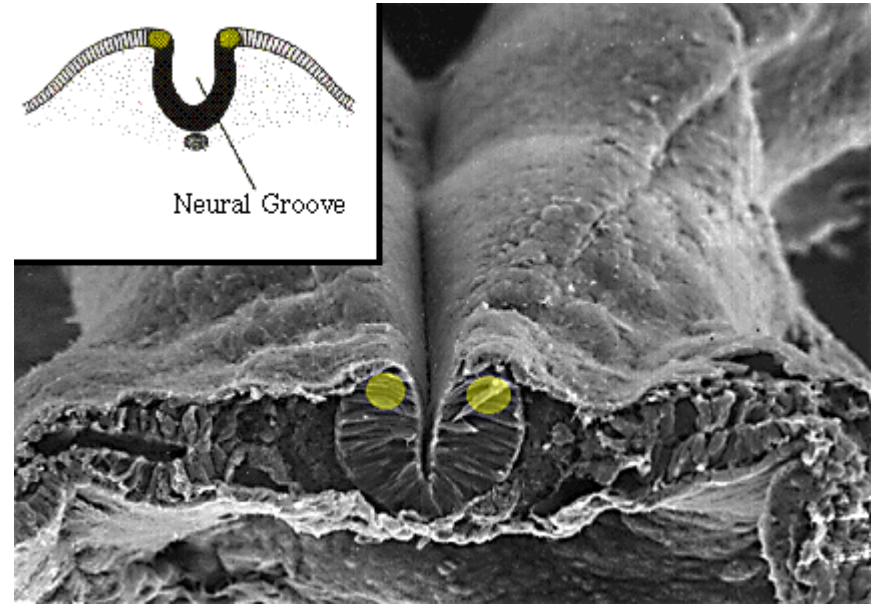
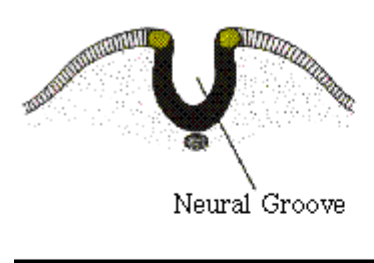
[Gilbert 7th ed., Fig. 12.3]



Neurulation




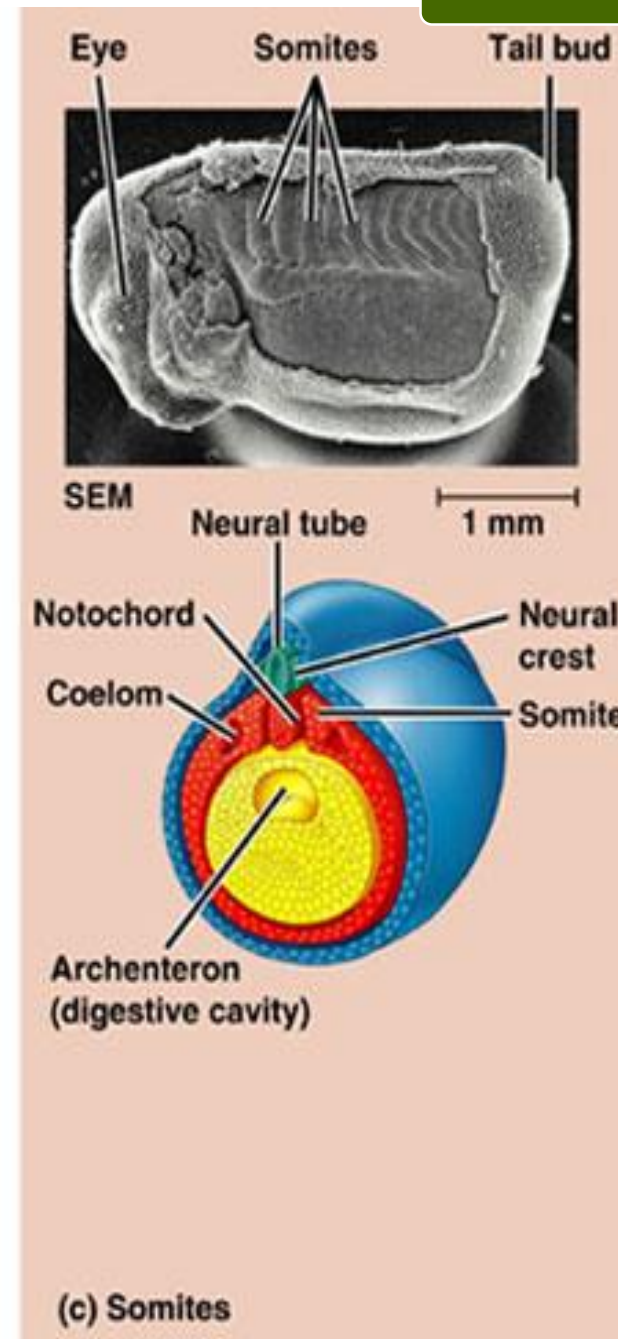
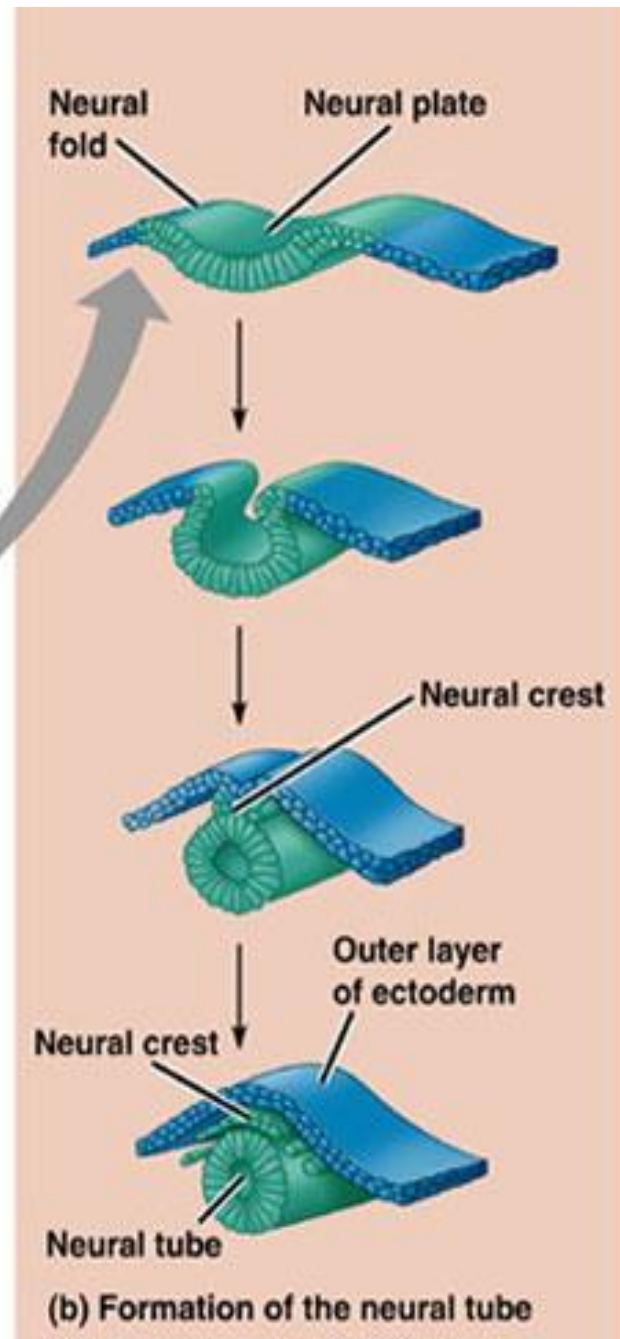
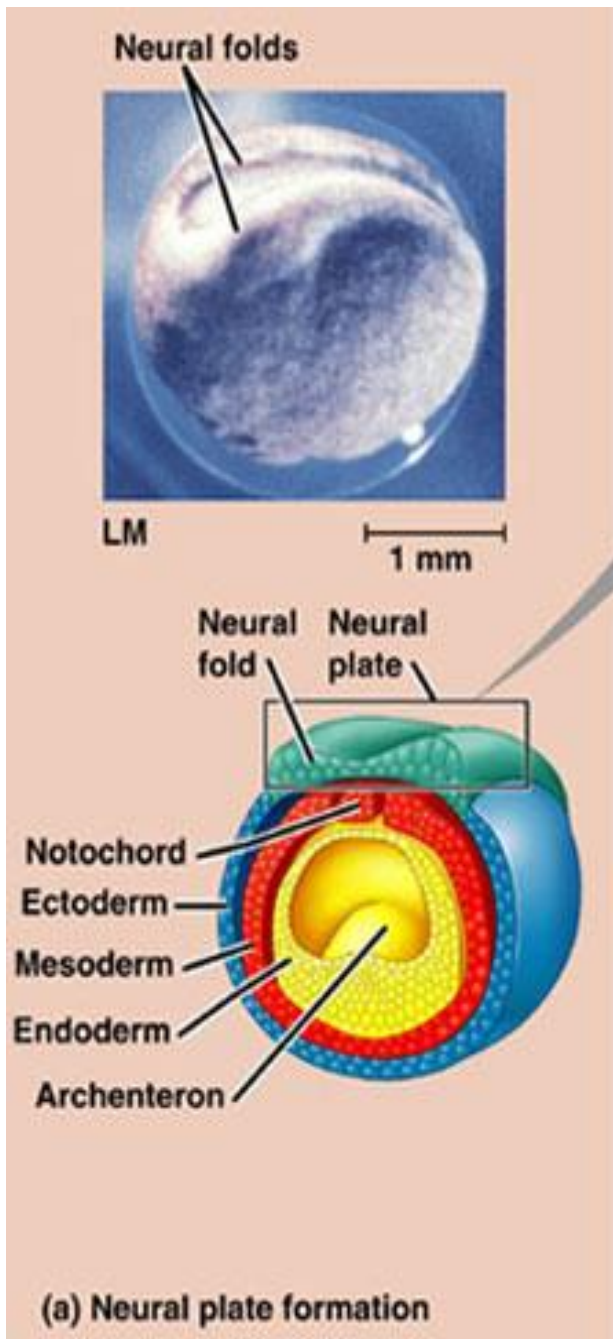
Neurulación

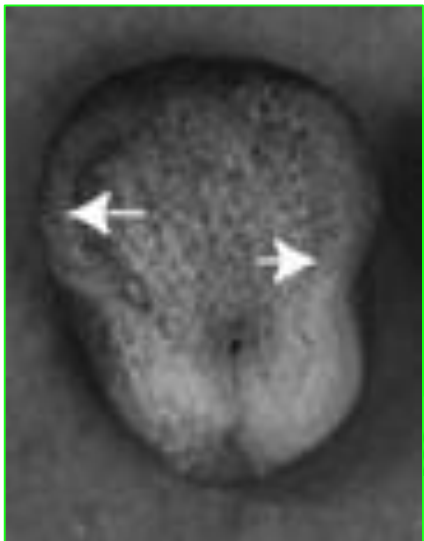
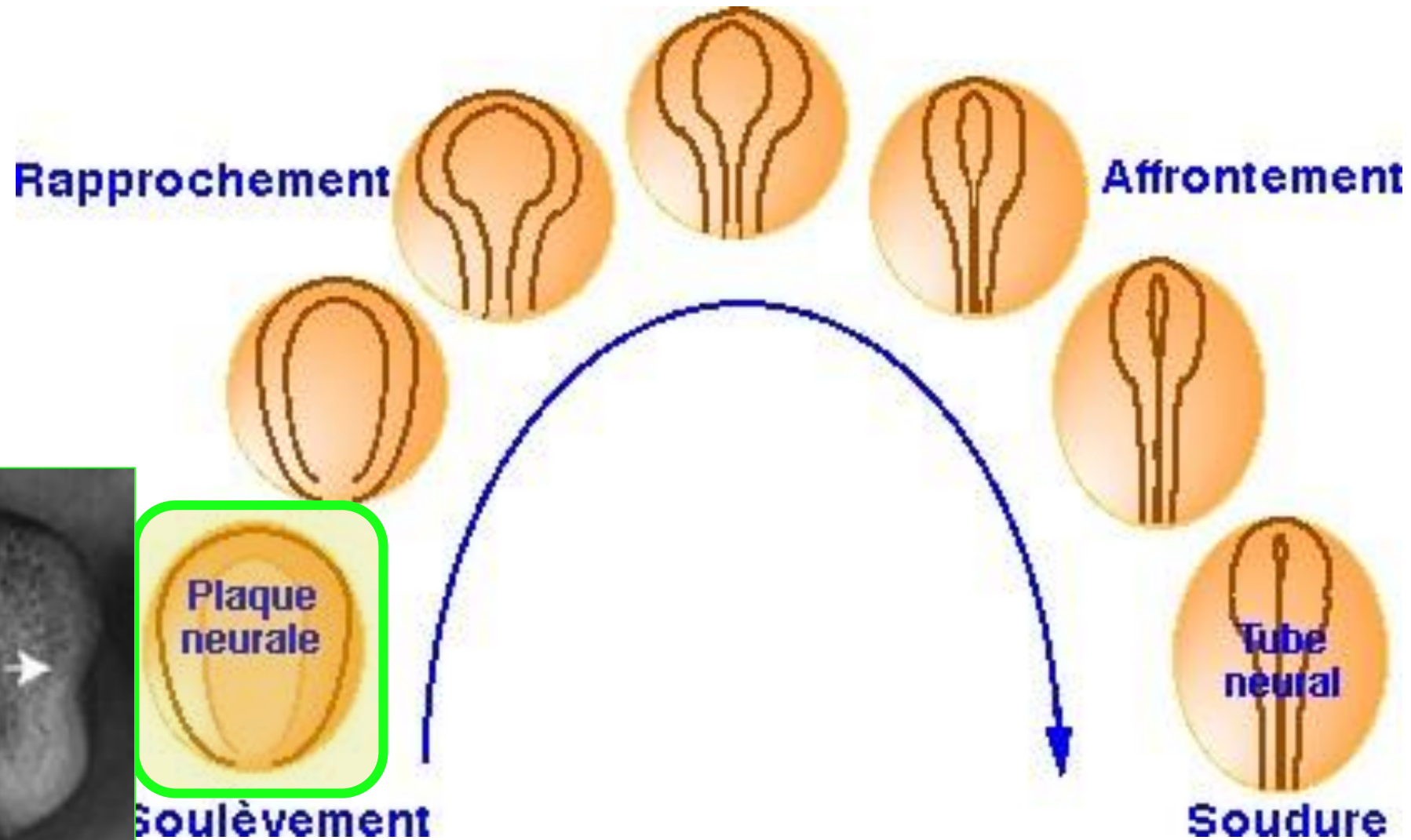


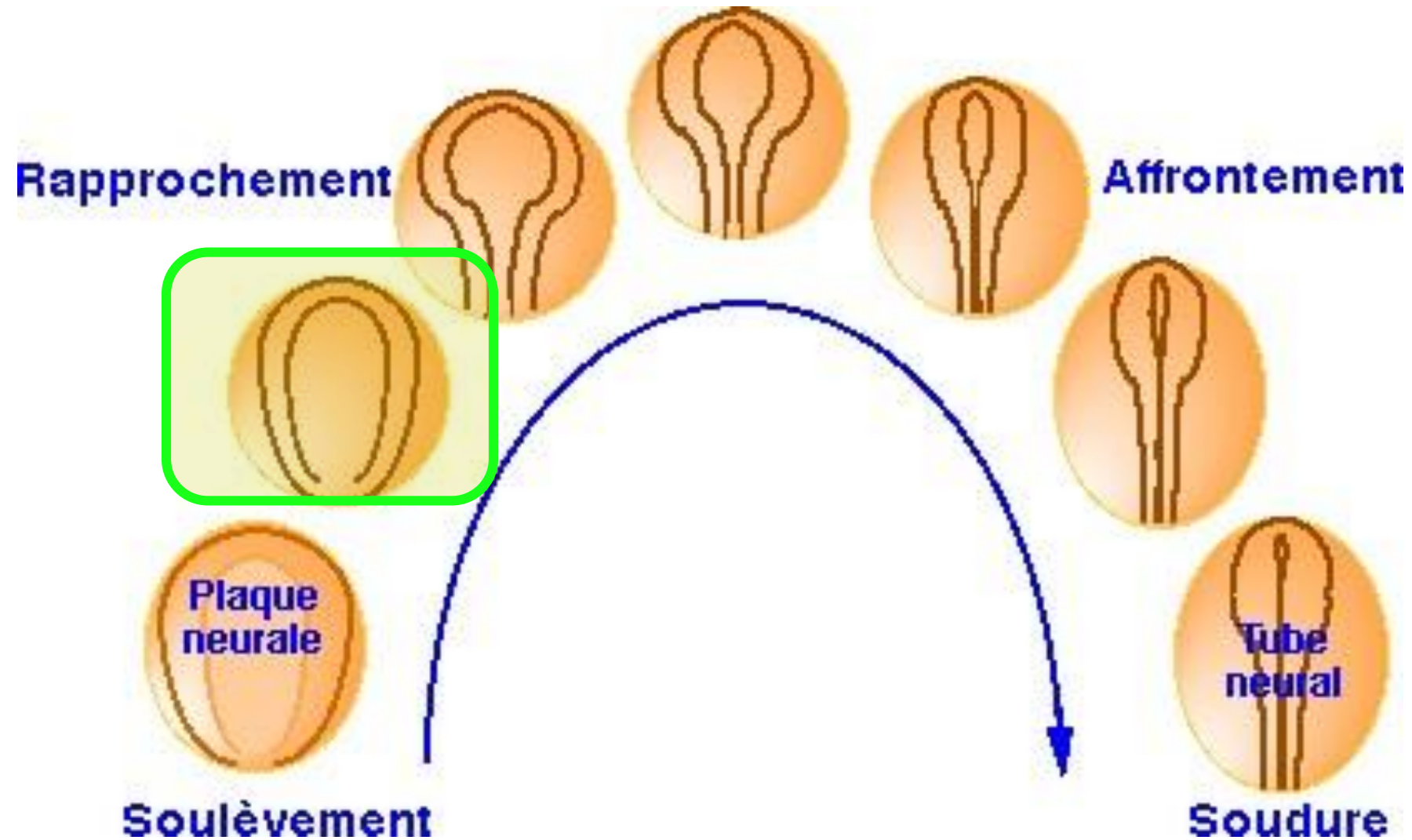
Localización de células de los pliegues neurales

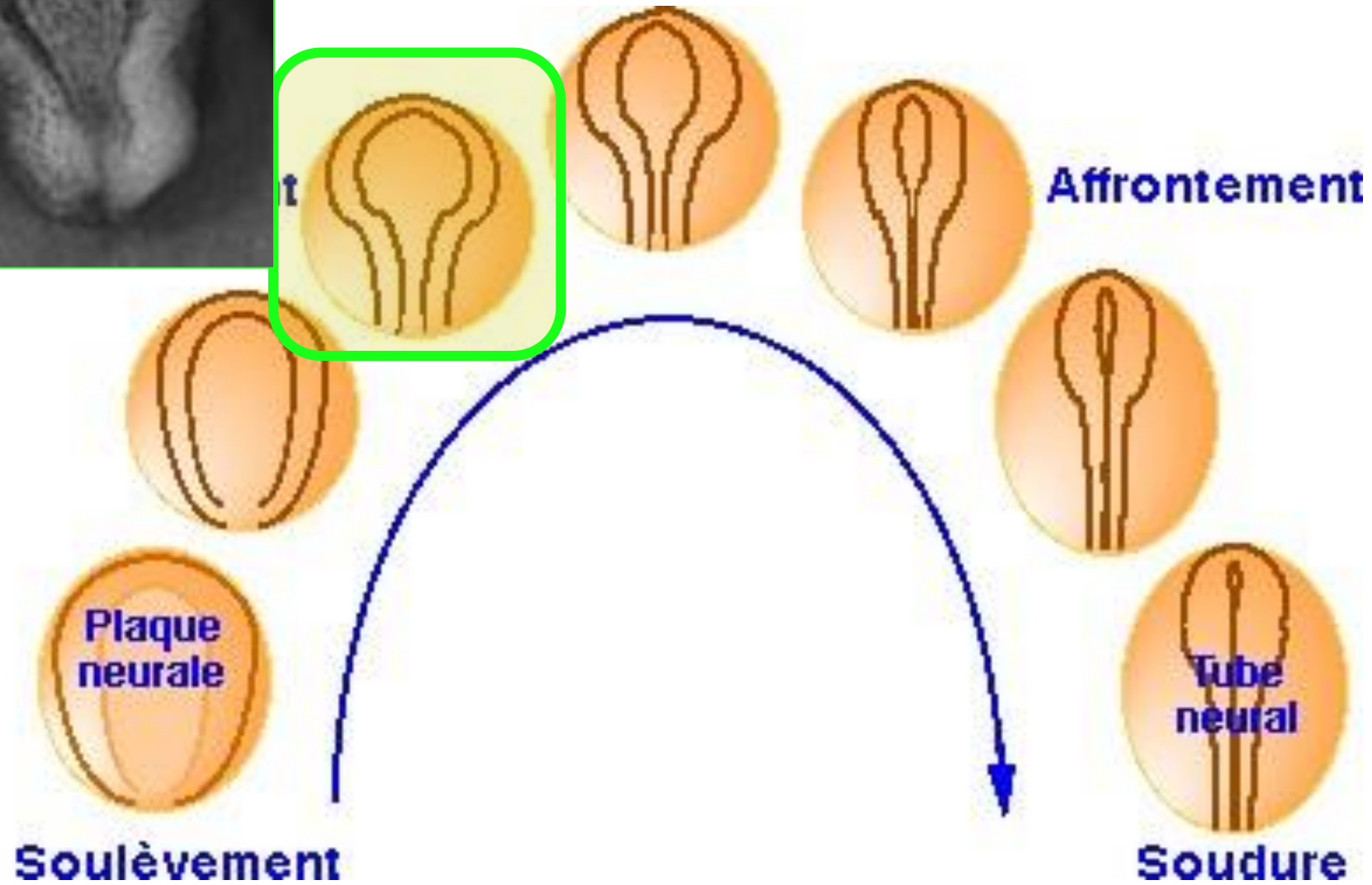
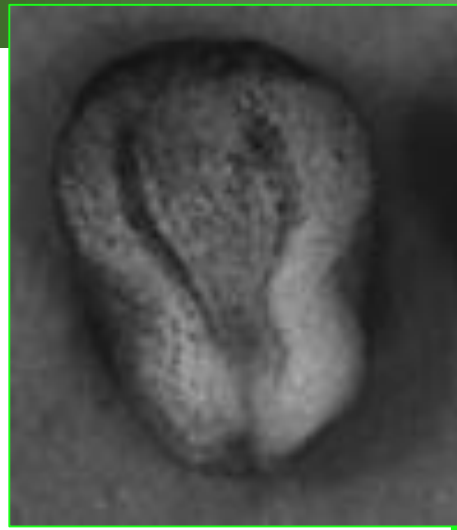
Células de la cresta neural desprendiéndose

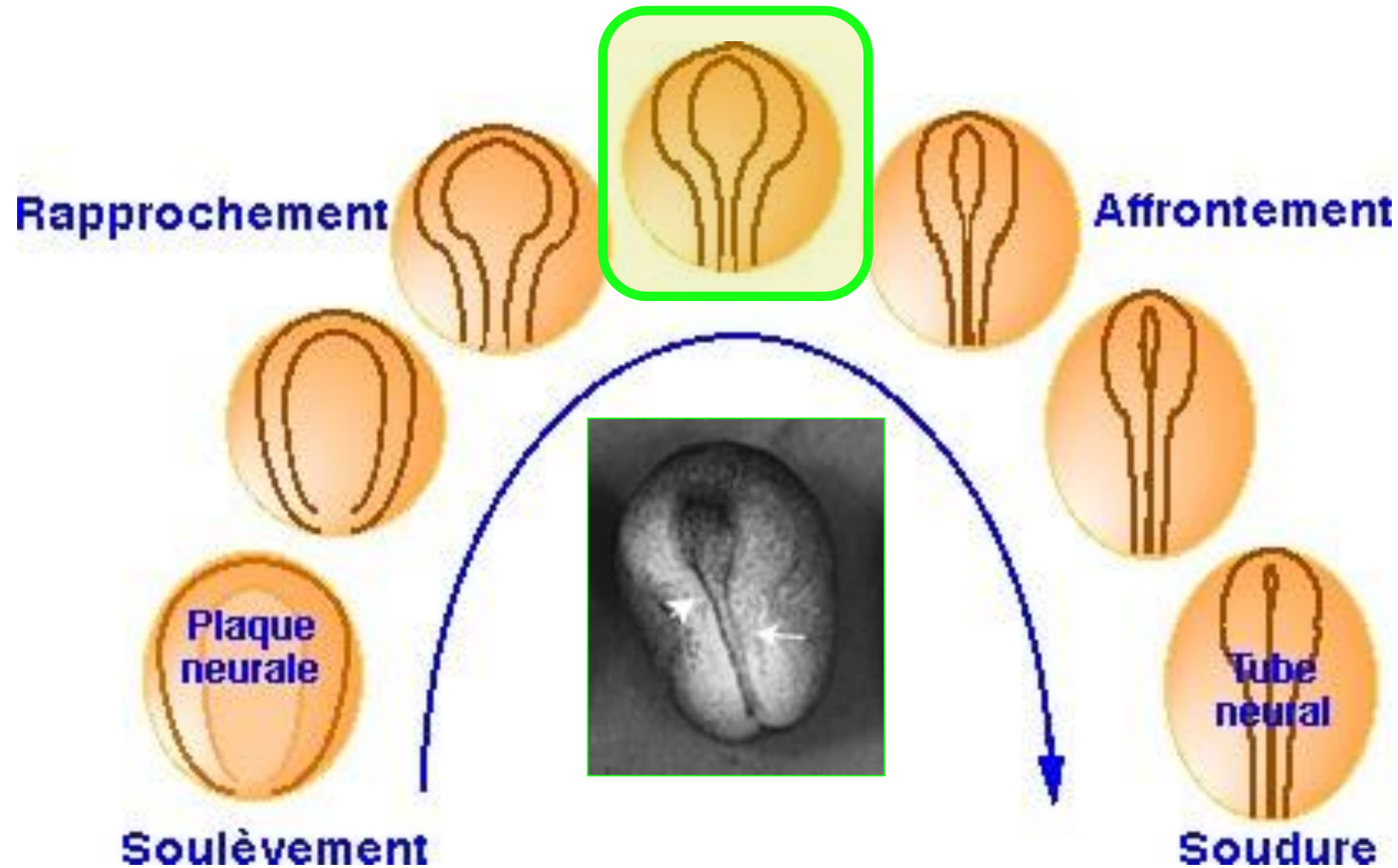


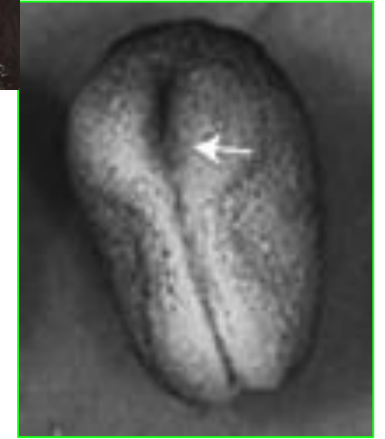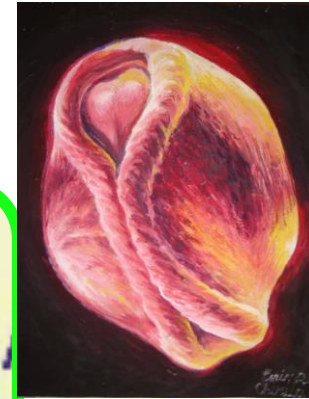
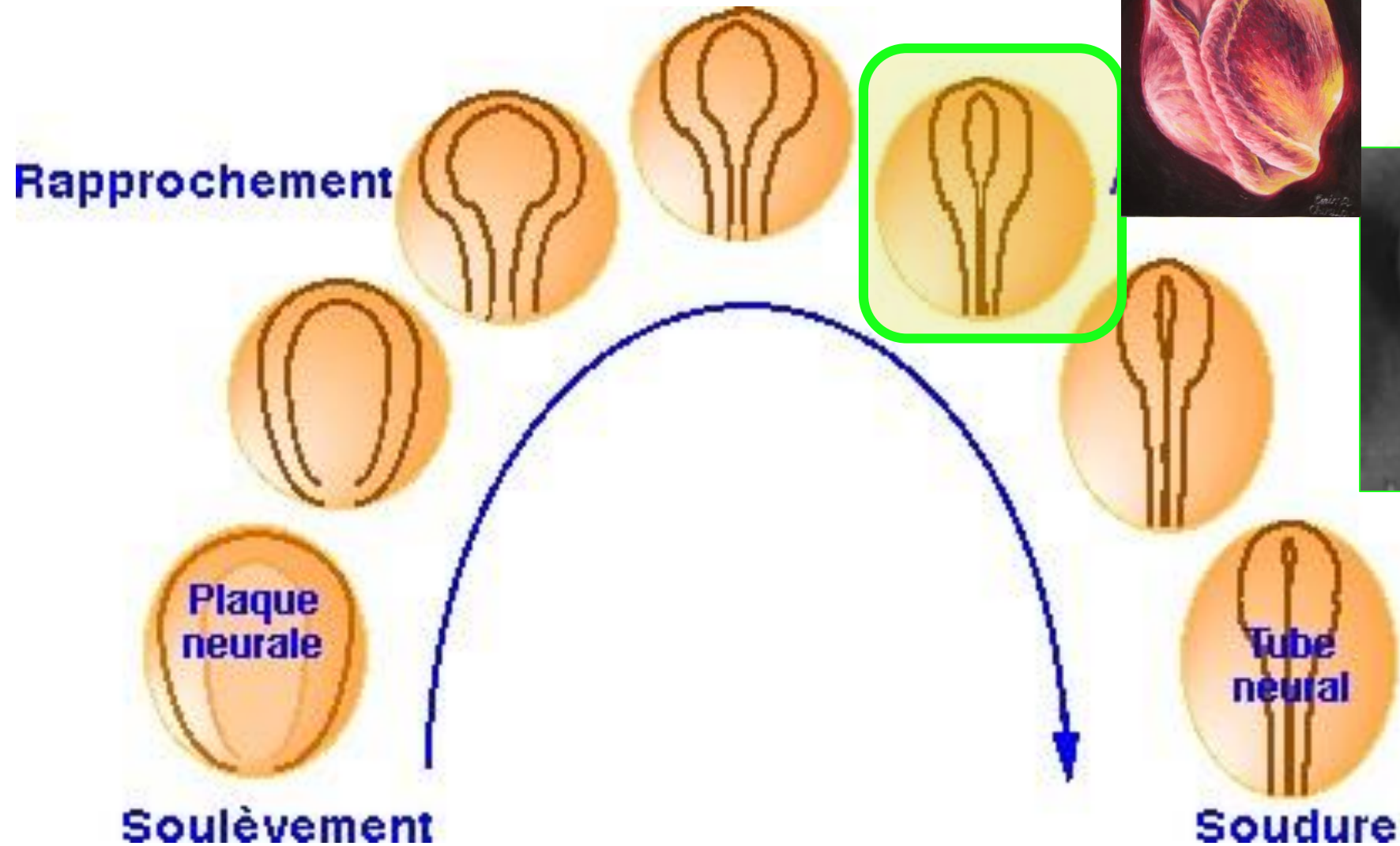


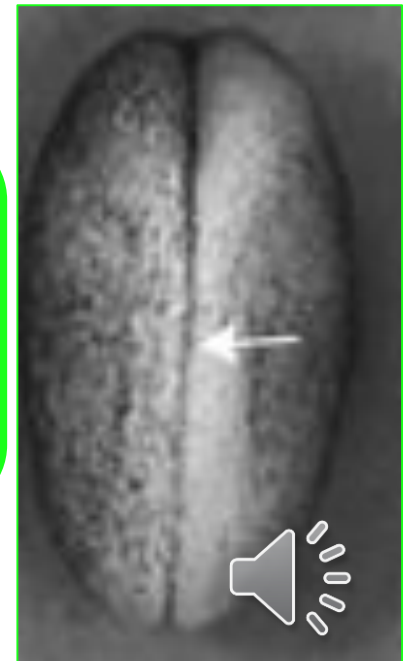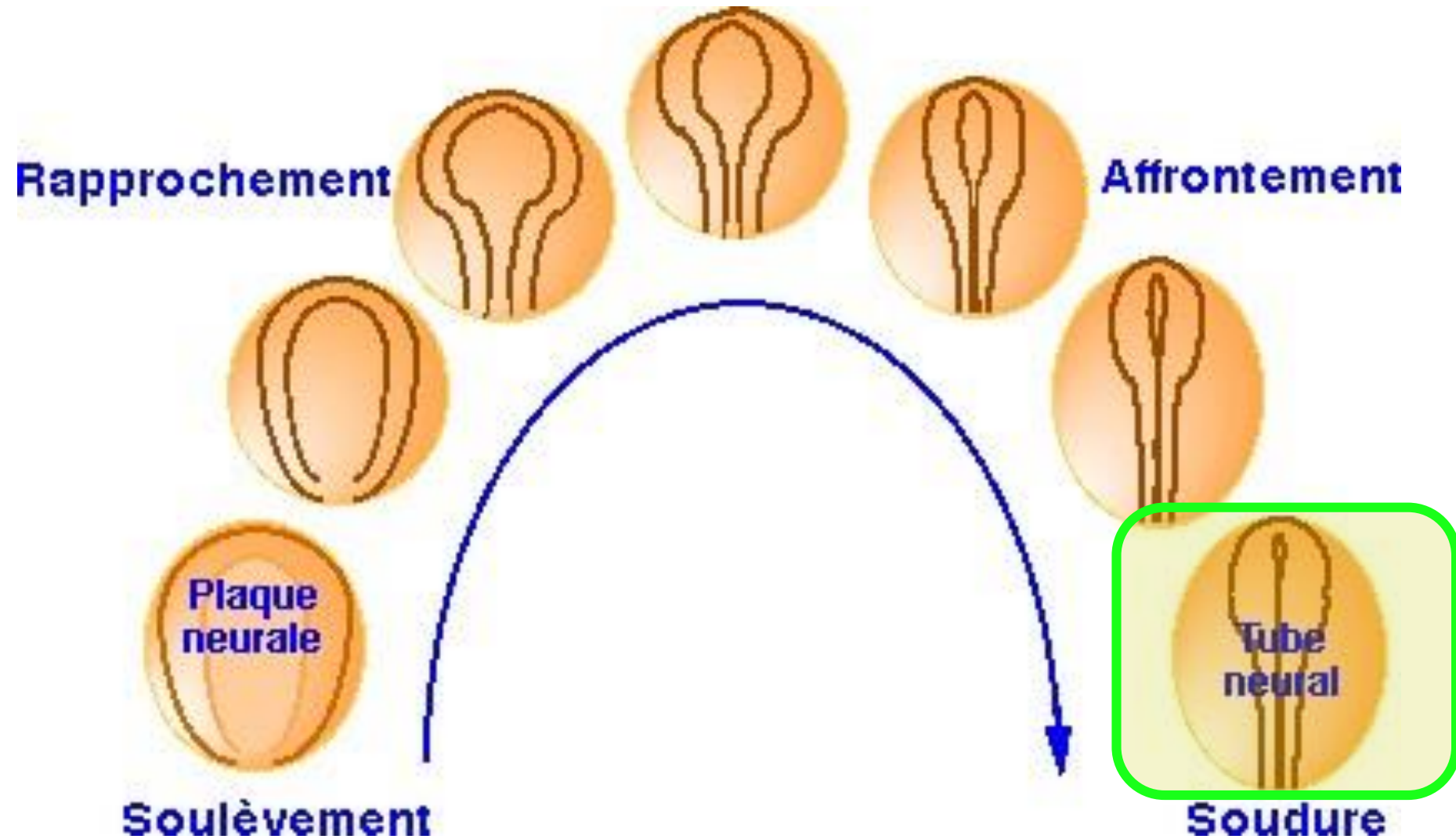




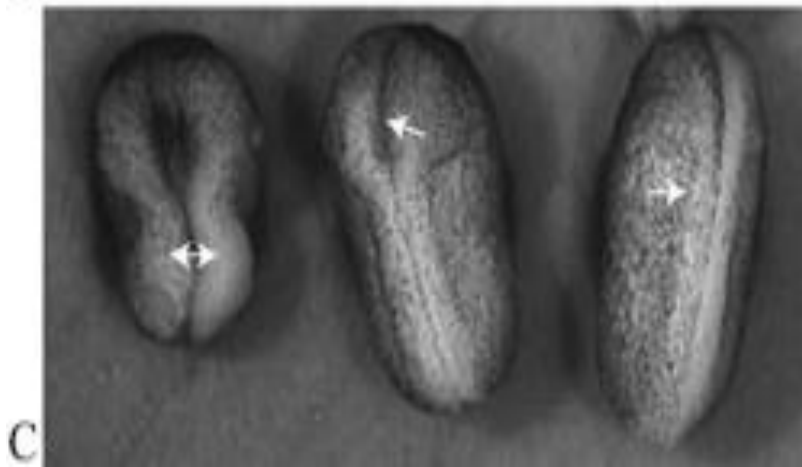
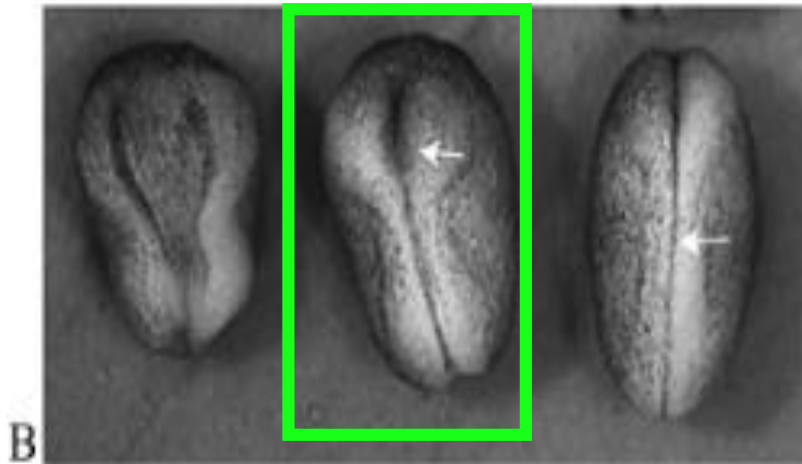
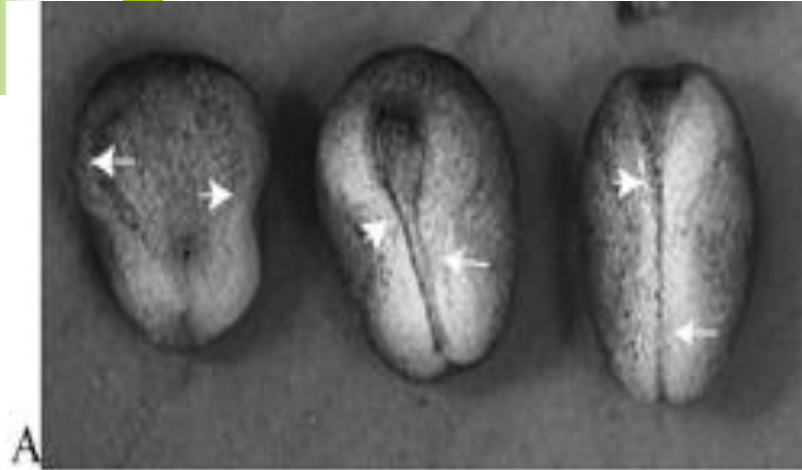






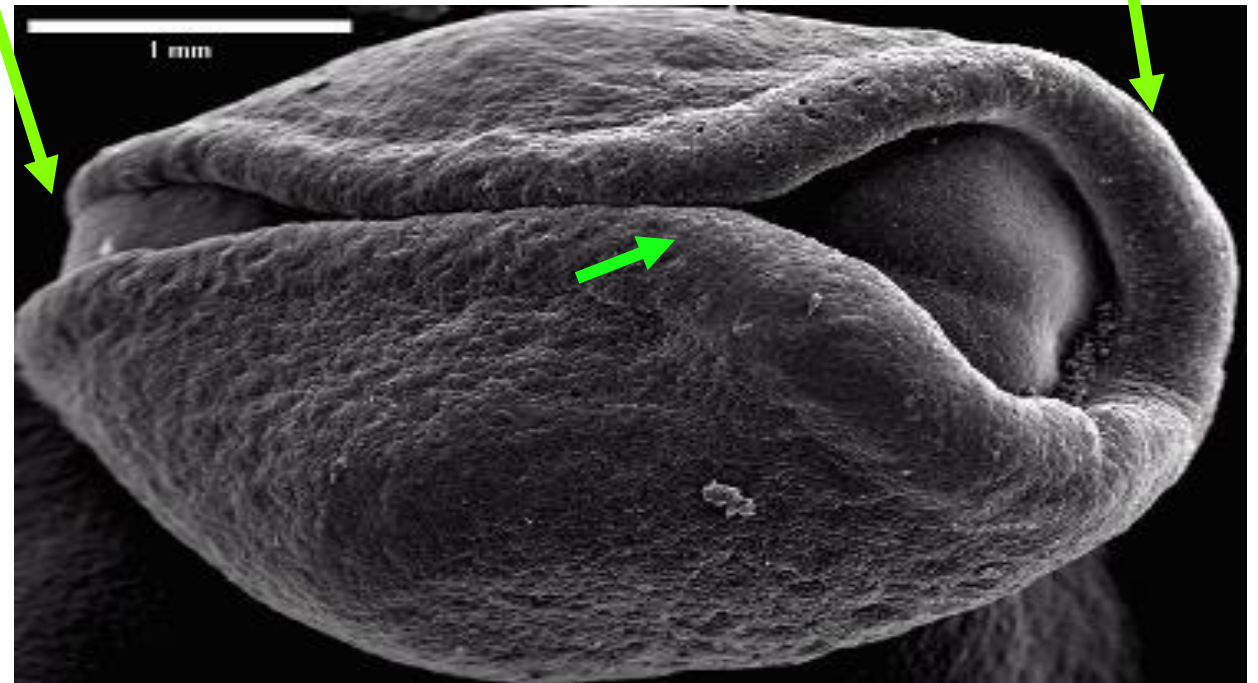


Neurulación



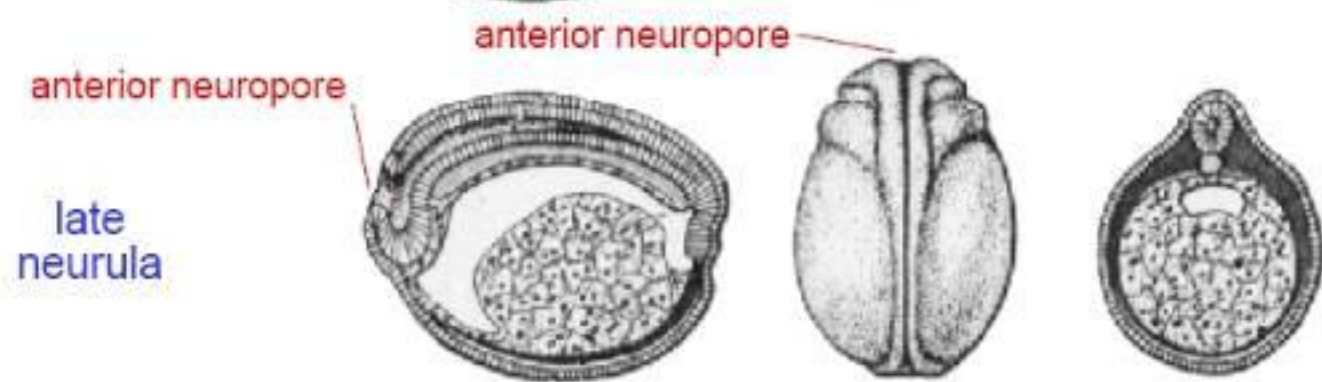
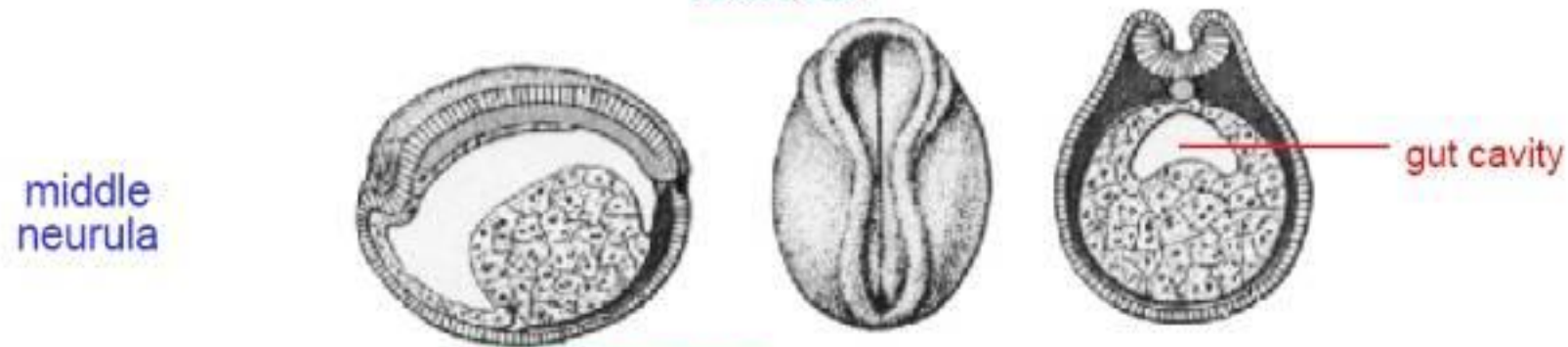
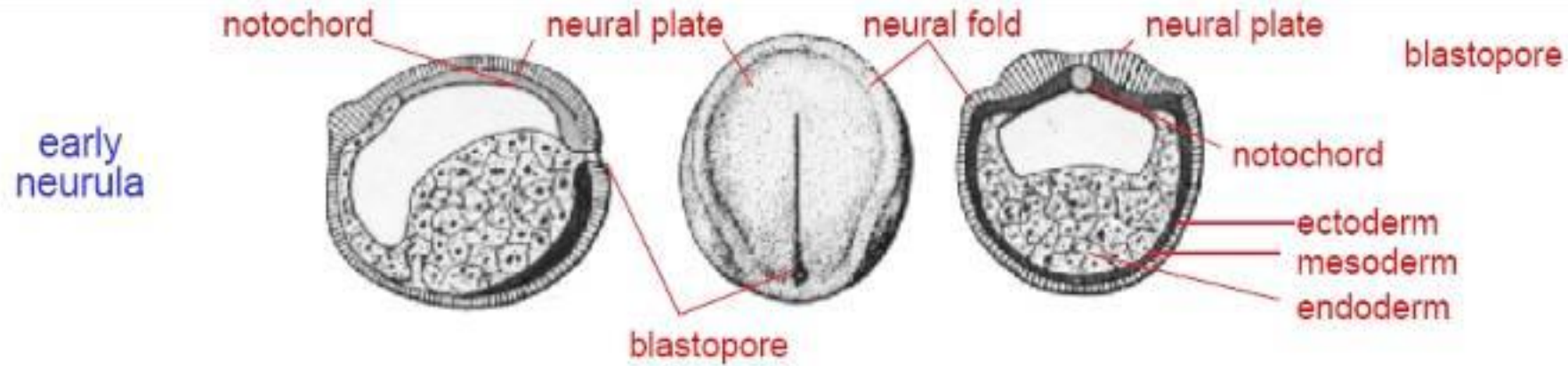
Neuroporo posterior

Neuroporo anterior



Punto inicial de cierre del tubo nervioso





midsagittal dorsal surface transverse

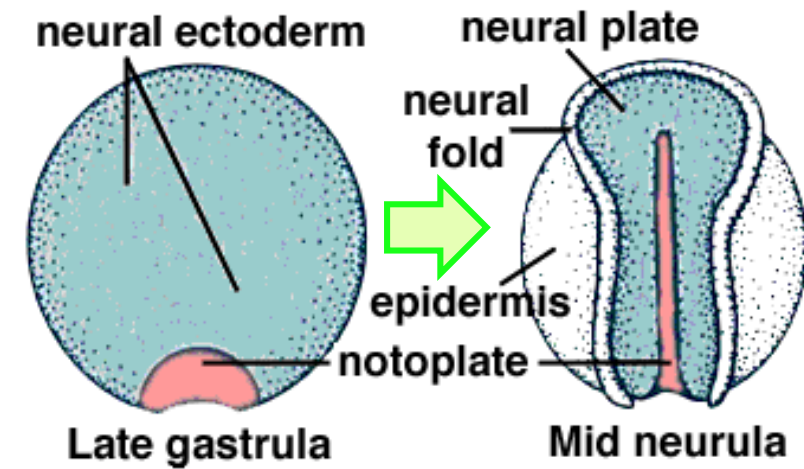
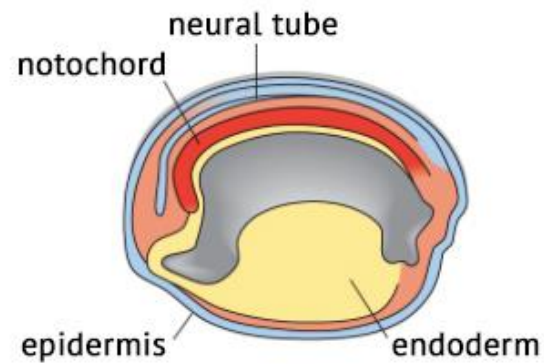
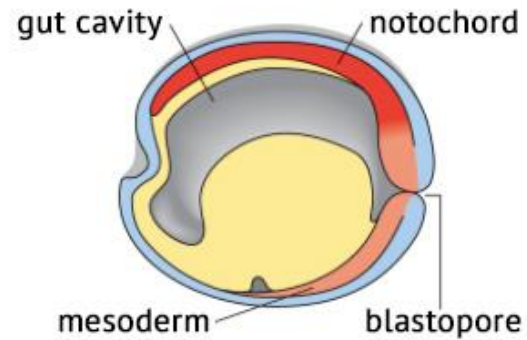
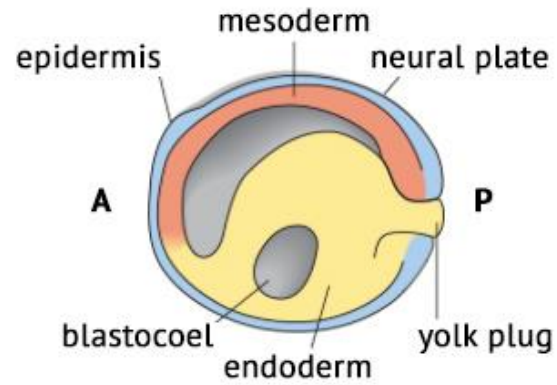


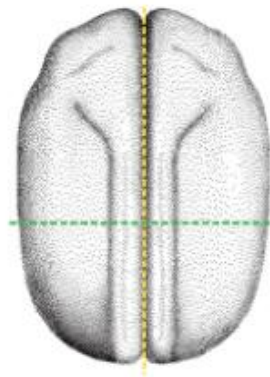
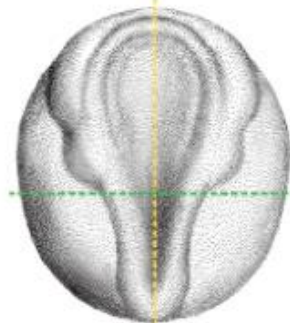
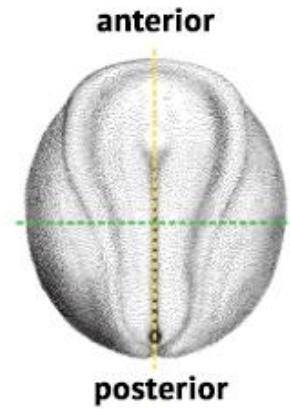
FIG. 7-7



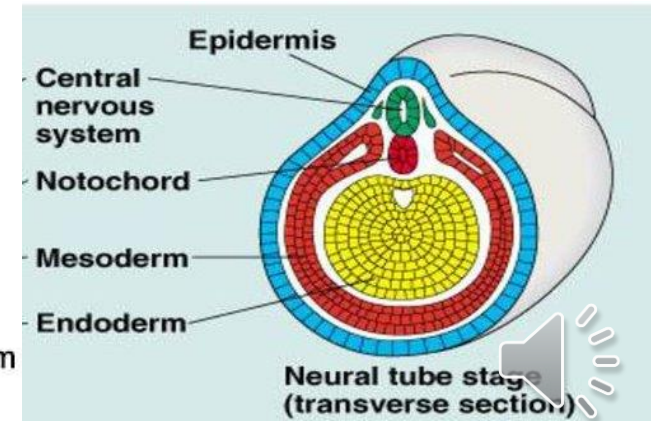
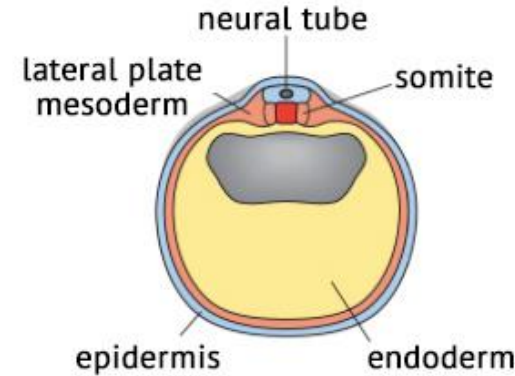
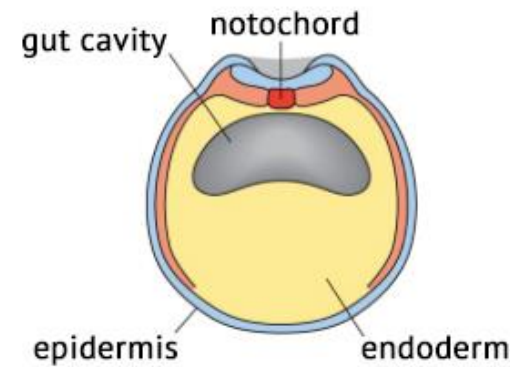
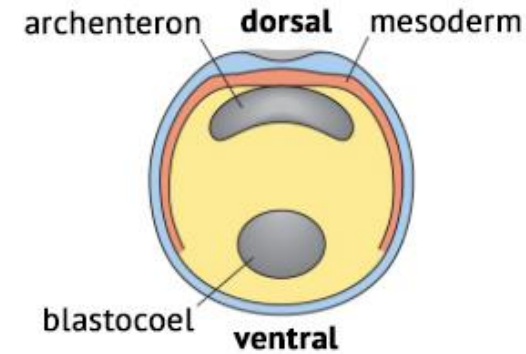
sagittal section

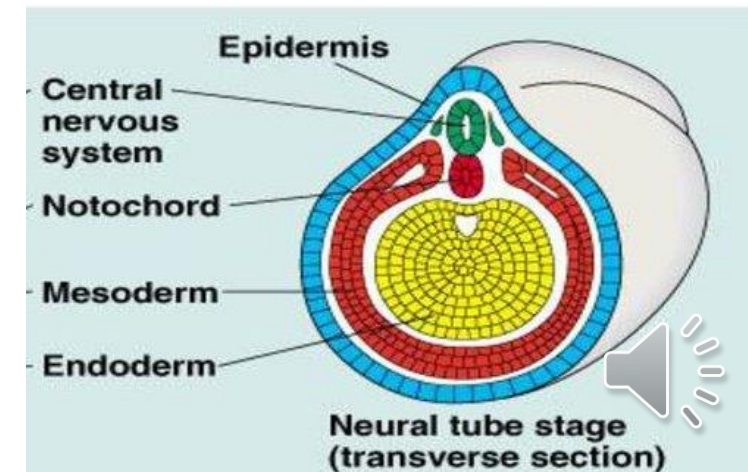
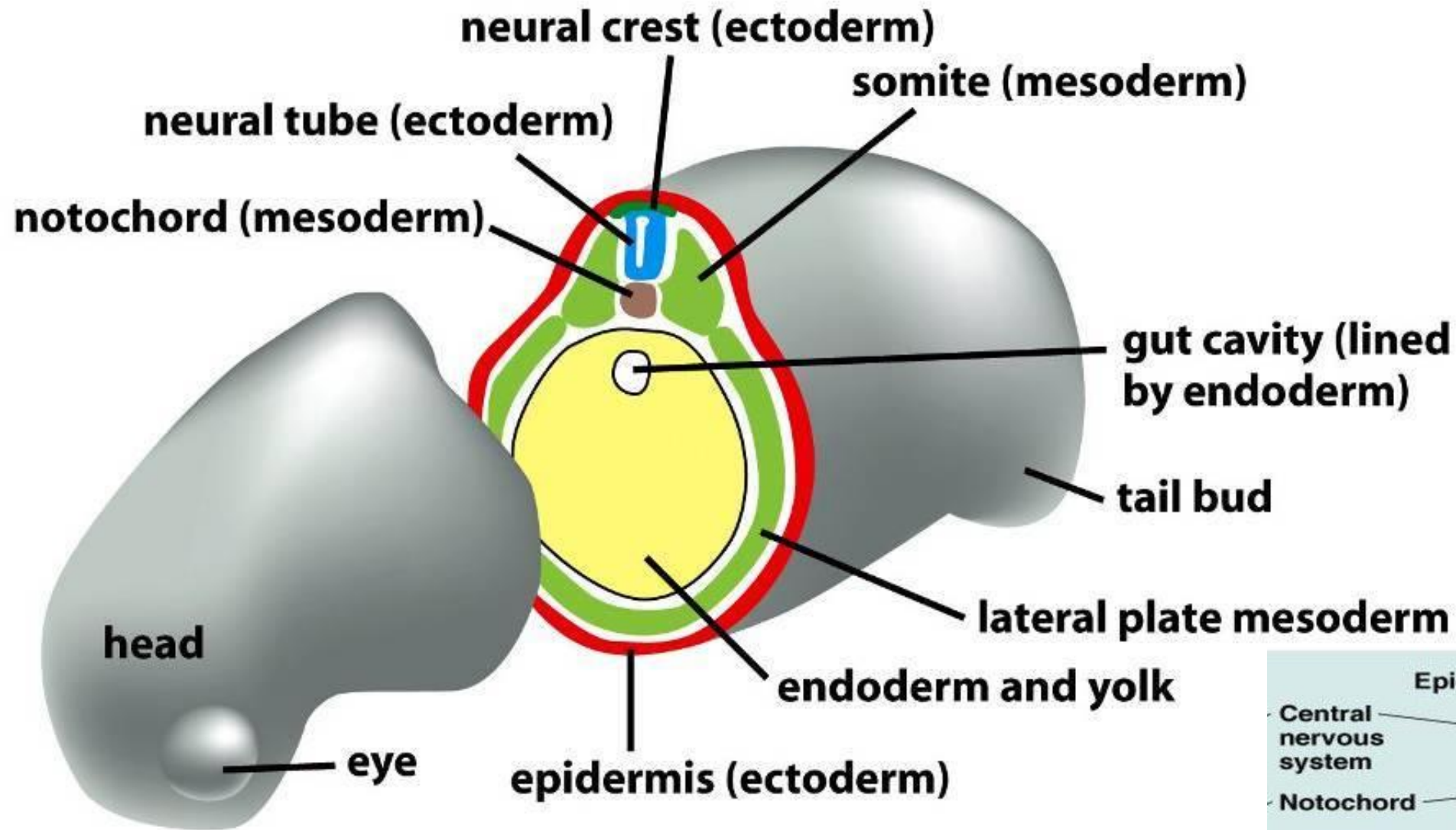


dorsal view of embryo

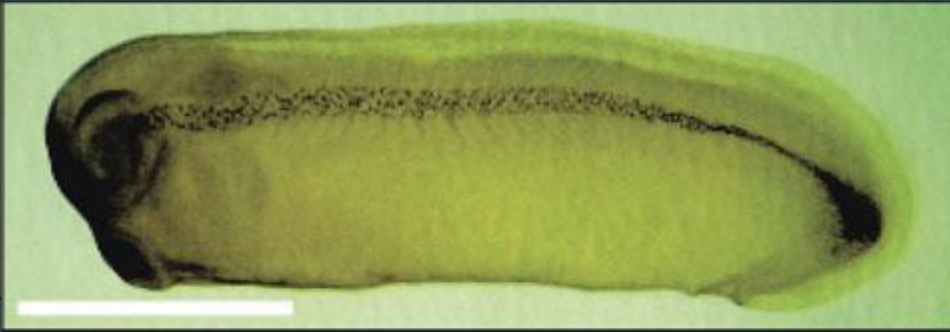


transverse section

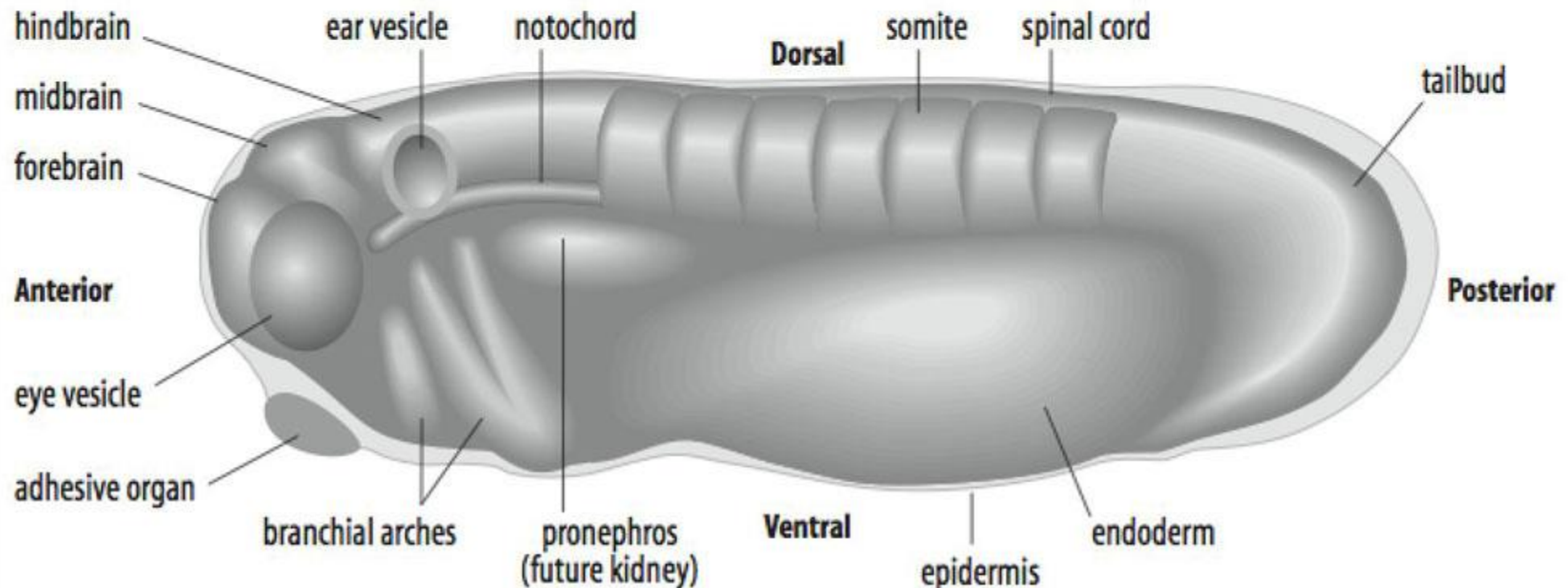


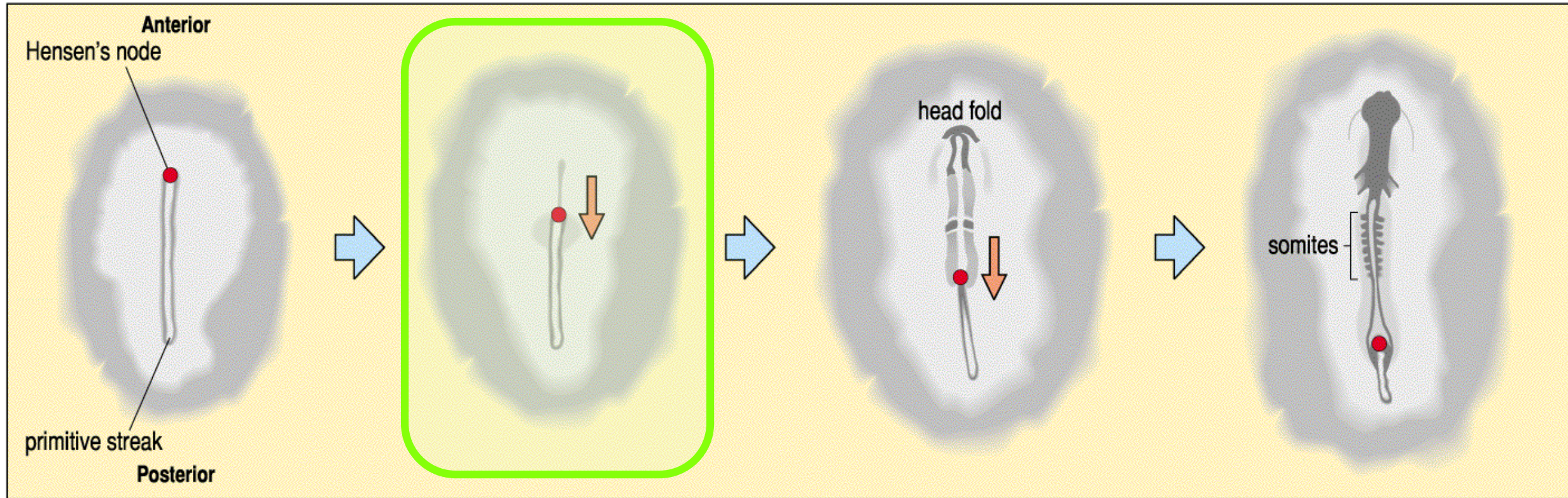


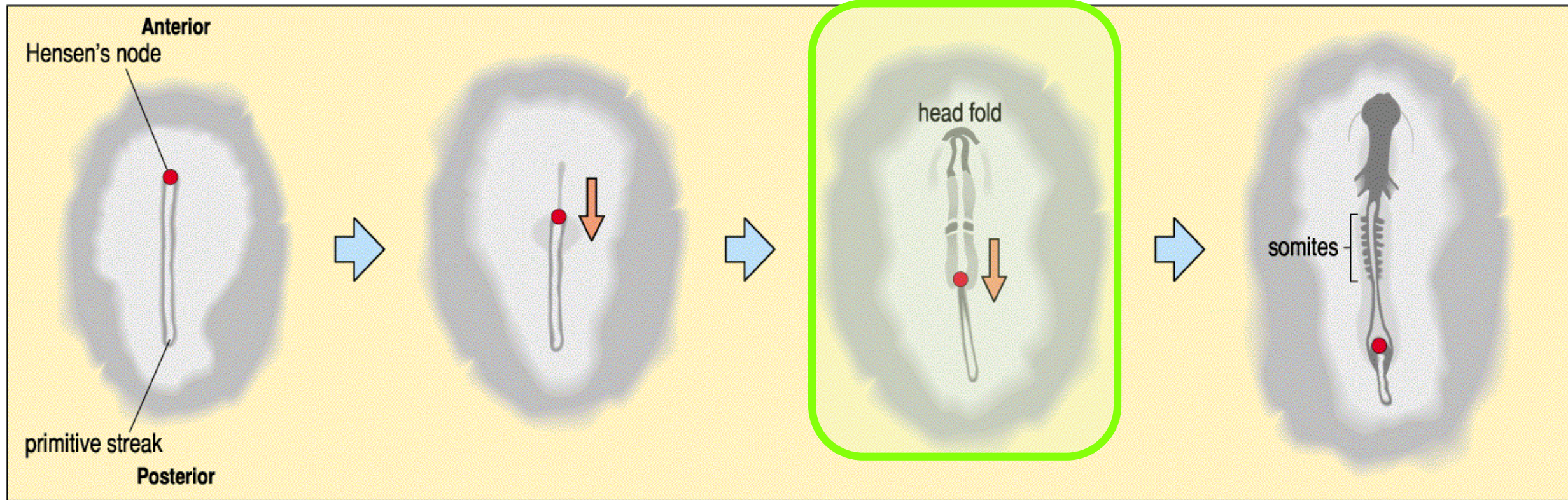
Stage 26 *Xenopus* embryo (tailbud stage)

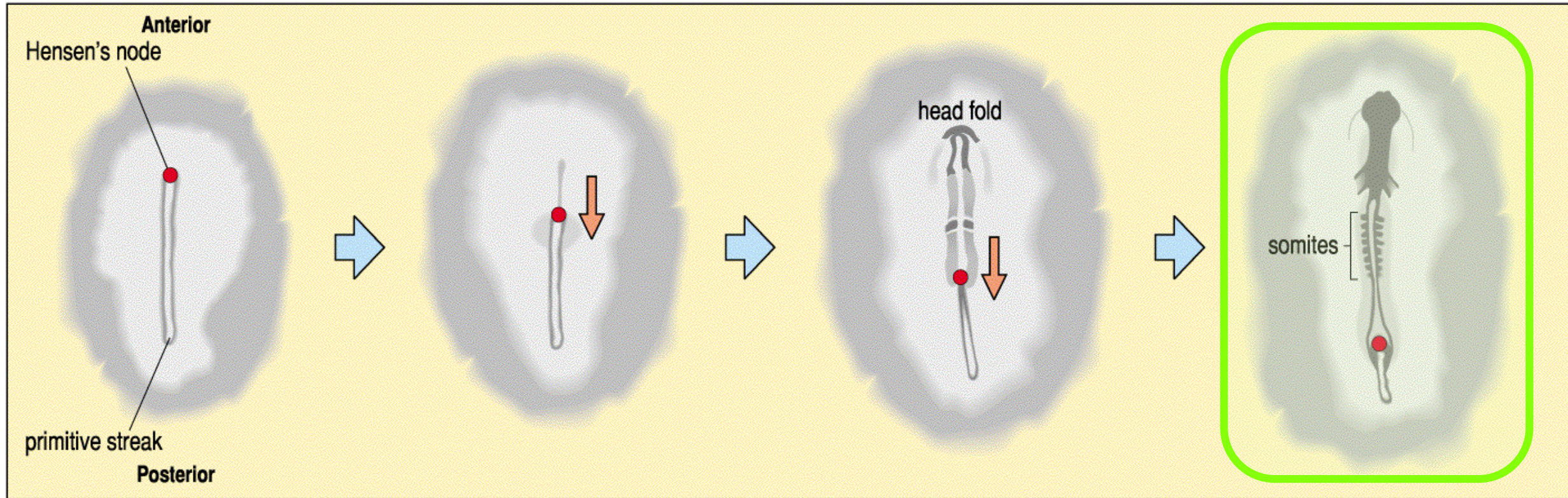


Schematic of *Xenopus* embryo with epidermis on the left-hand side removed

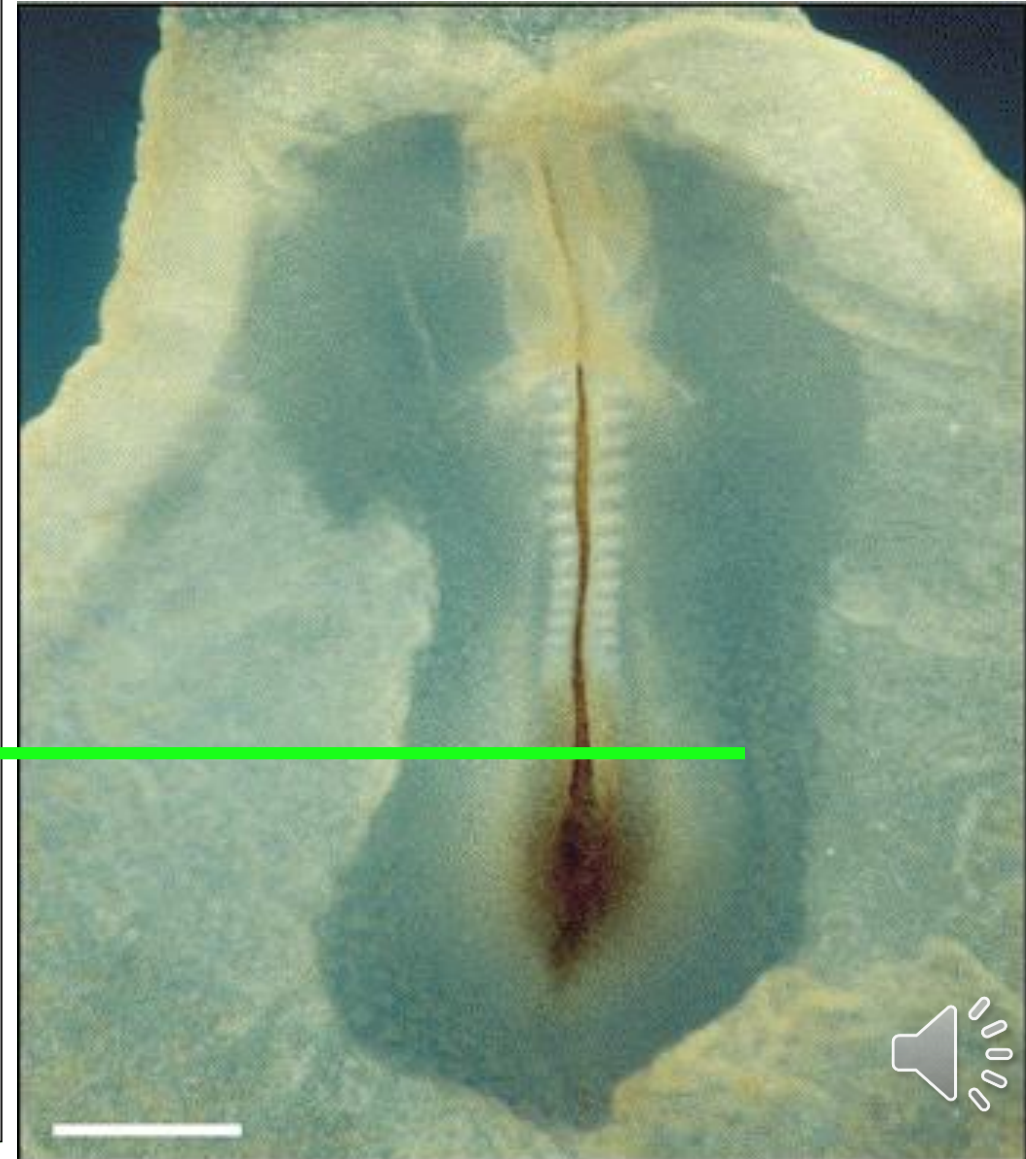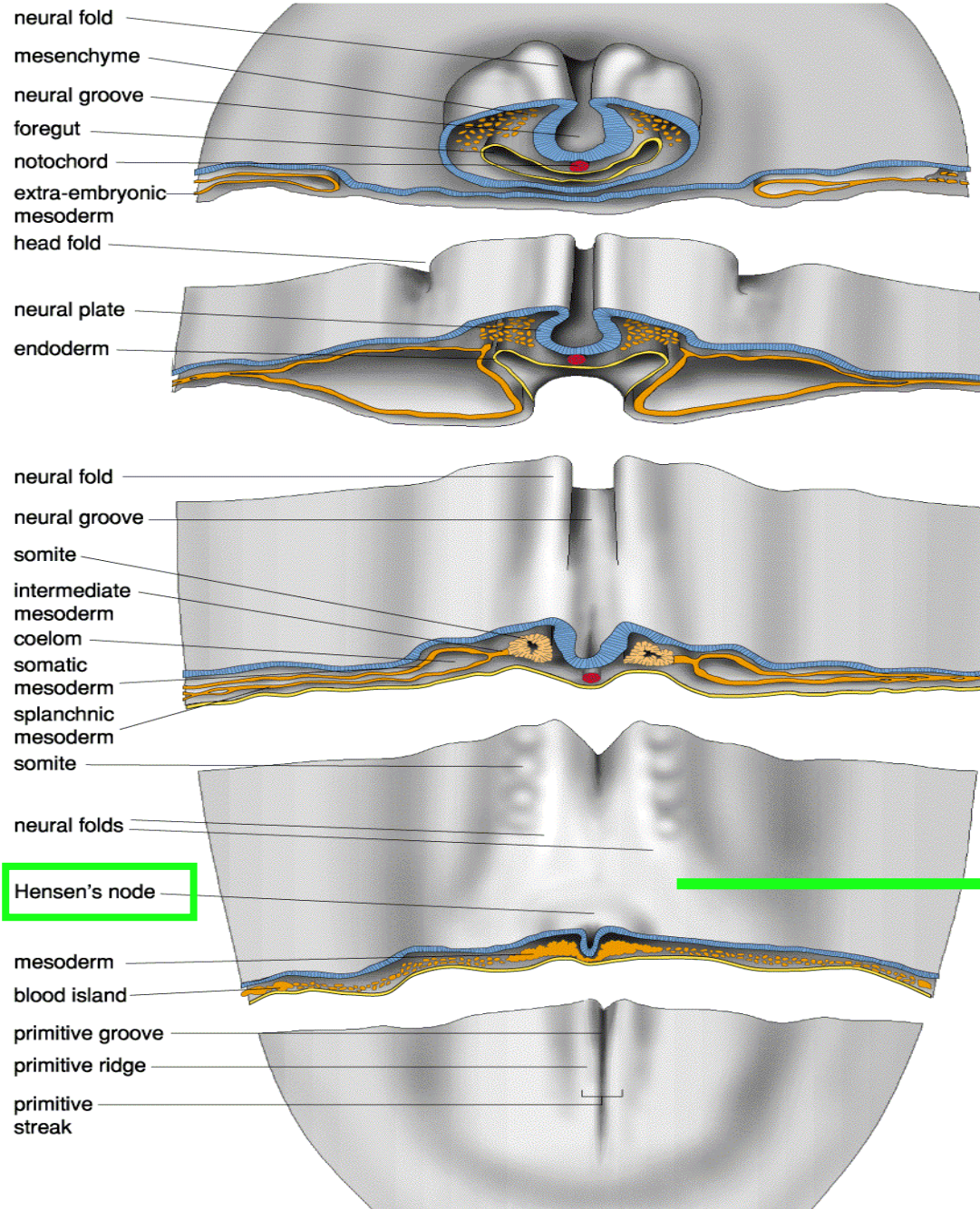








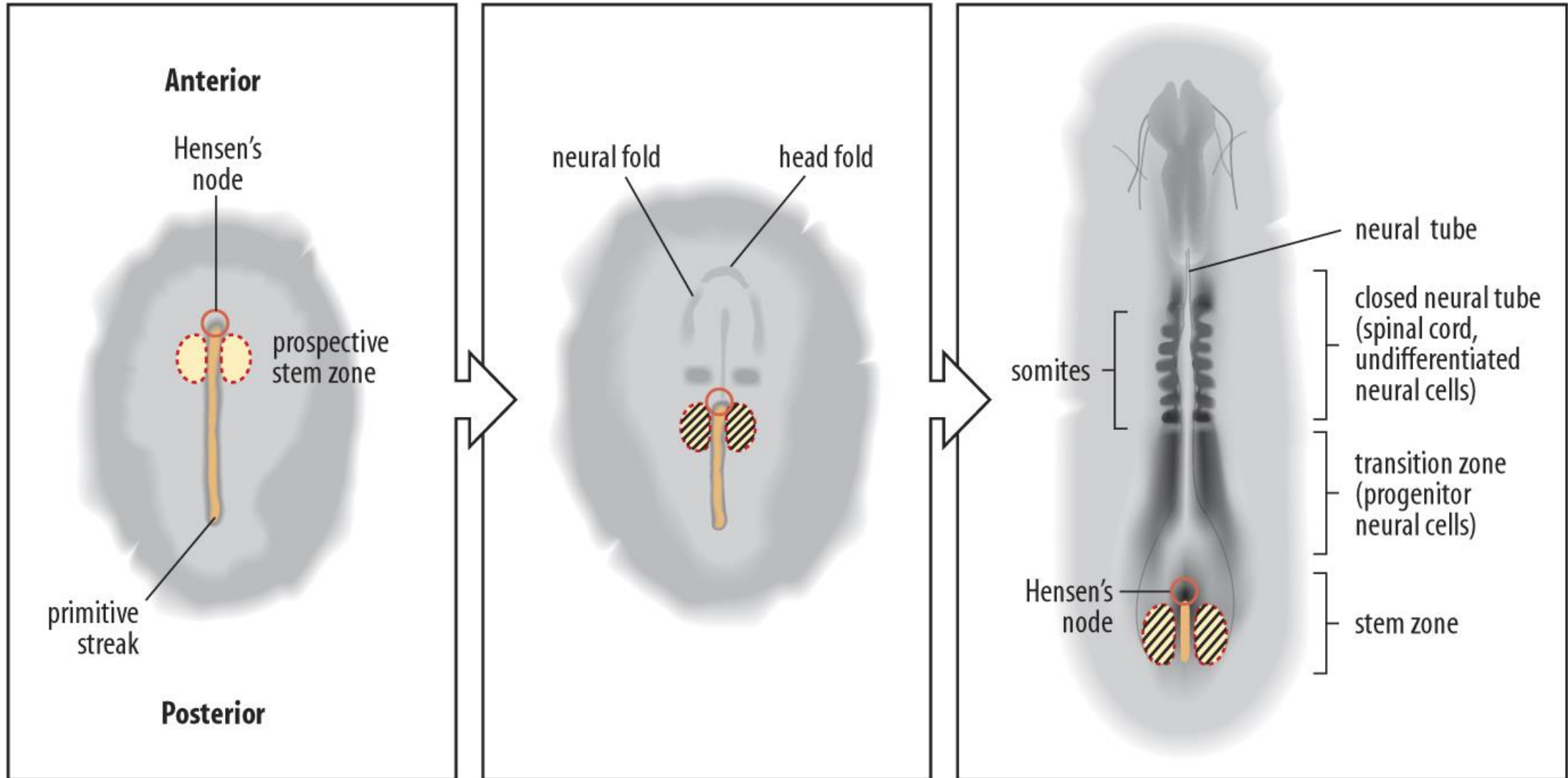
Neurulación



Neurulación

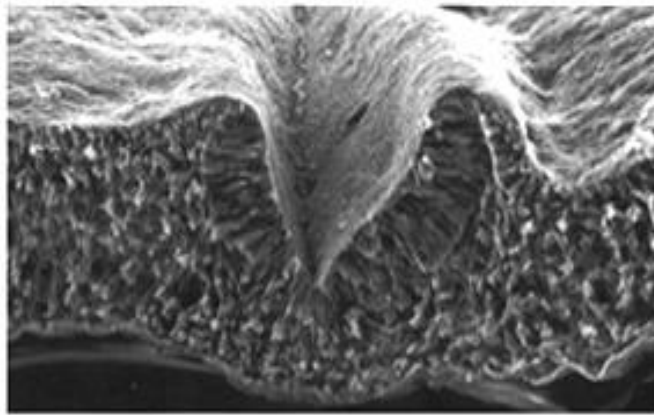
En la región posterior no ha culminado la gastrulación



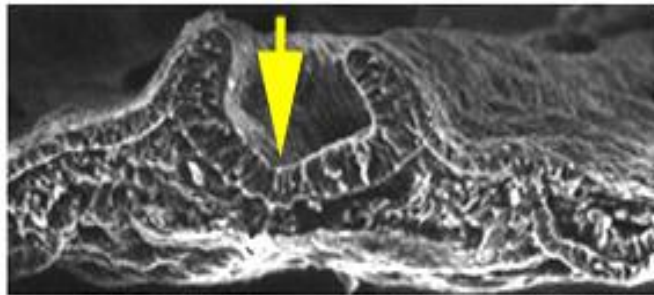


 *Sax1*

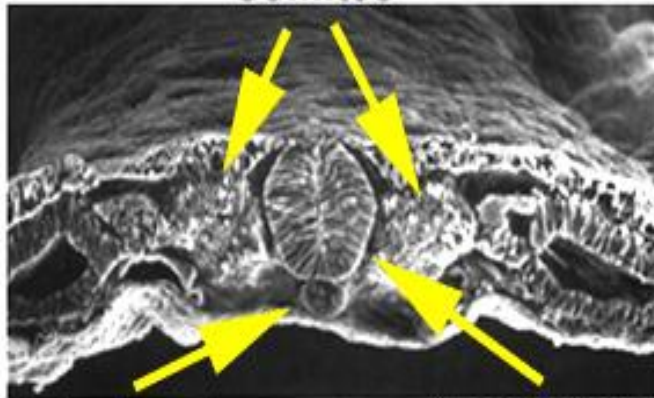




Neural groove

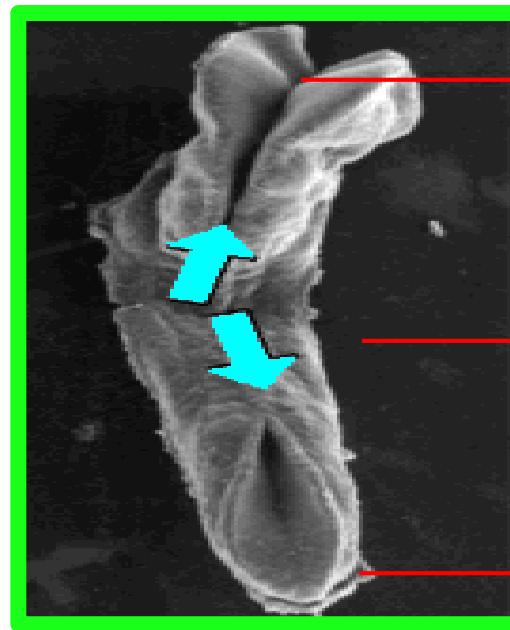
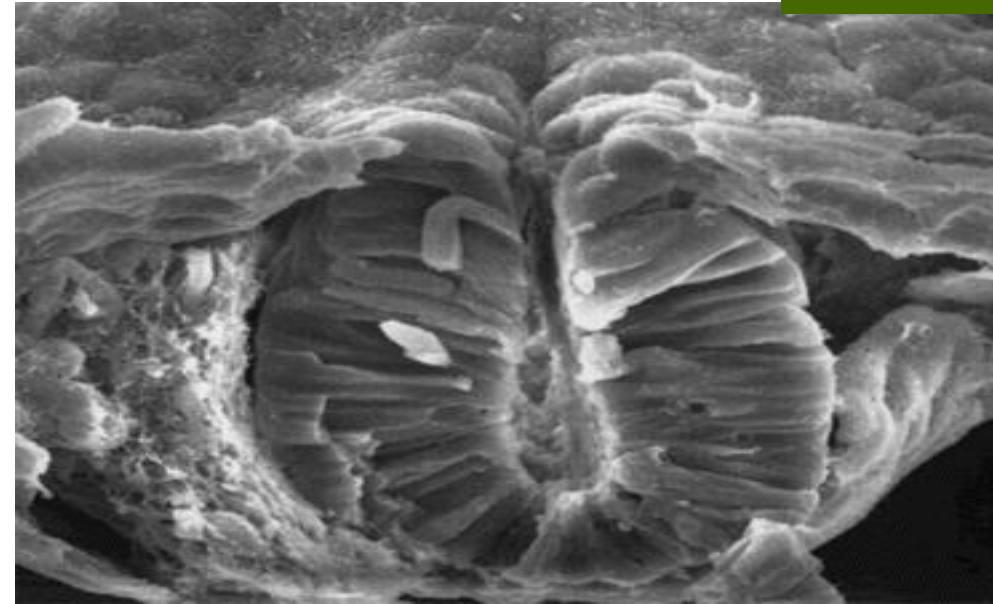


Somites



Notochord

Neural tube



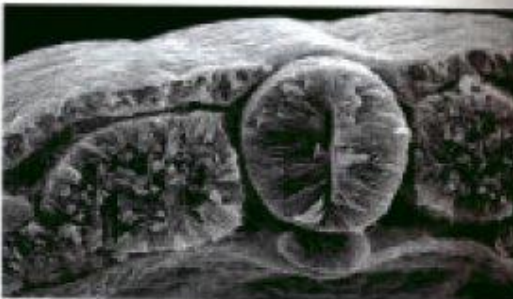
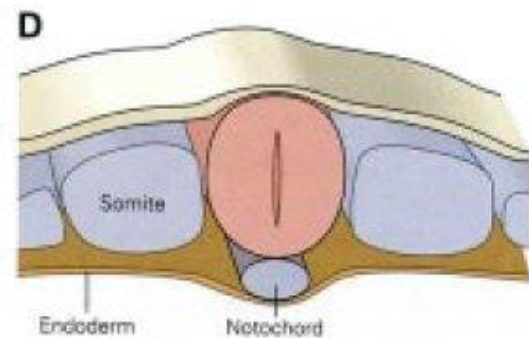
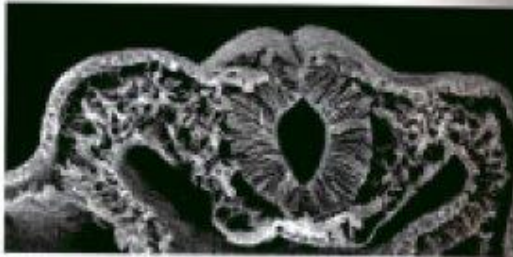
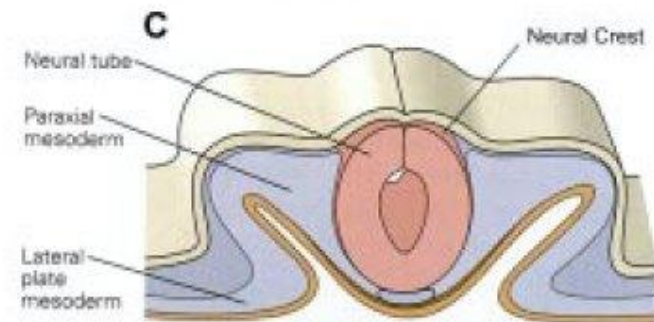
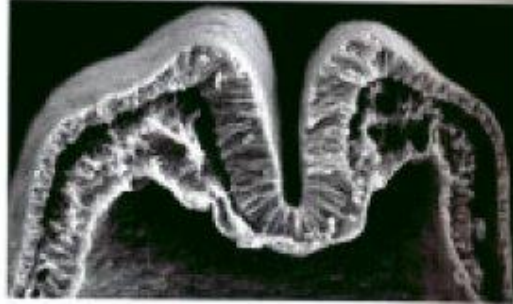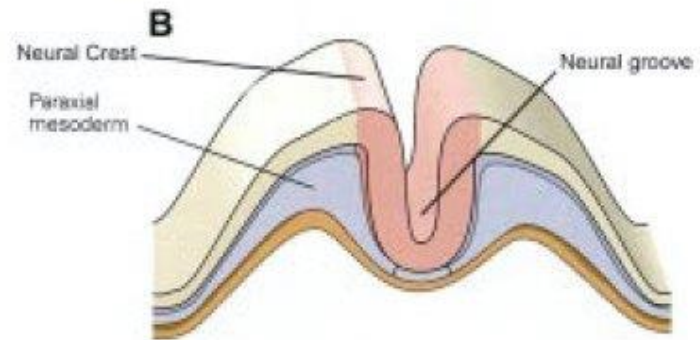
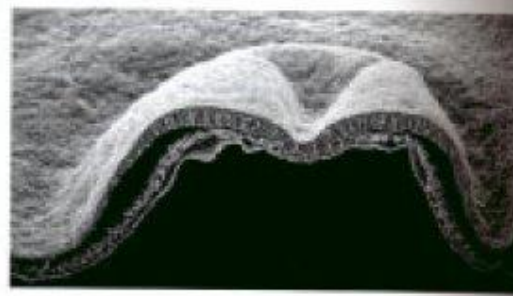
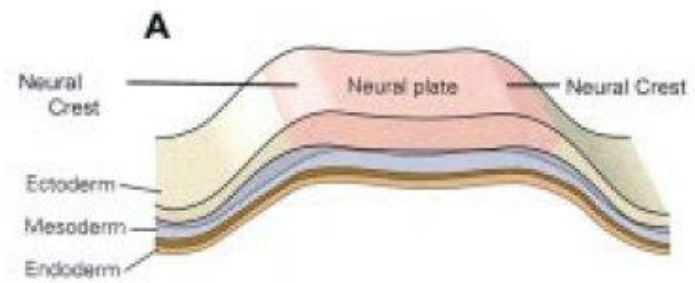
Neuroporo anterior

Inicio del cierre del tubo neural en la región troncal

Neuroporo posterior



Neurulación



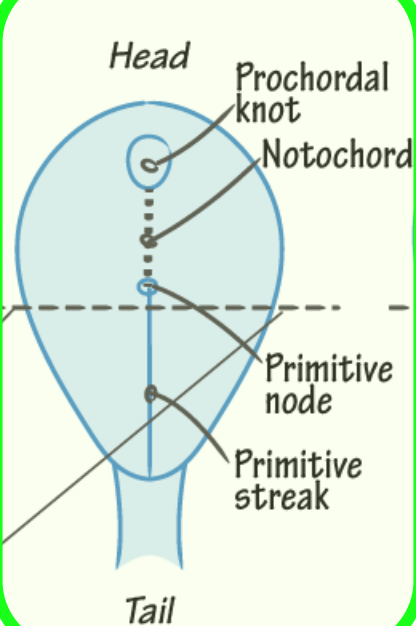


NEURULATION

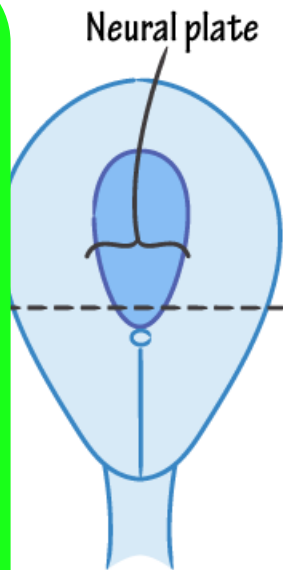
+ Neurulation

- ✓ Notochord induces overlying ectoderm to develop into the neural plate.
- ✓ The neural plate folds into the neural tube and the neural crests are pinched off.
- ✓ The neural tube derives the CNS.
- ✓ The neural crests derive the PNS + select other cells (eg. melanocytes).

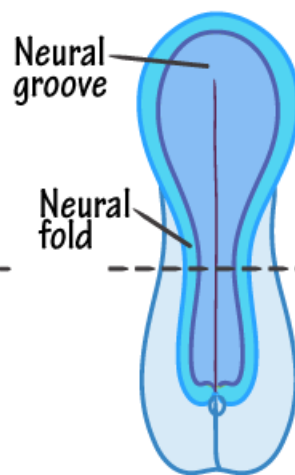
Superior View



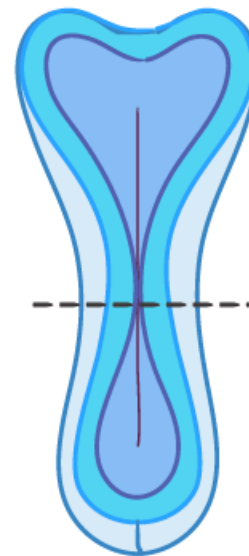
~ DAY 17



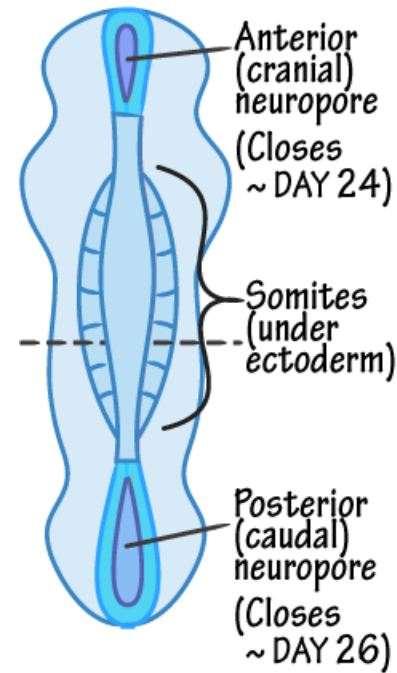
~ DAY 18



~ DAY 21



~ DAY 23



Amniotic cavity

Primitive streak

Coronal View

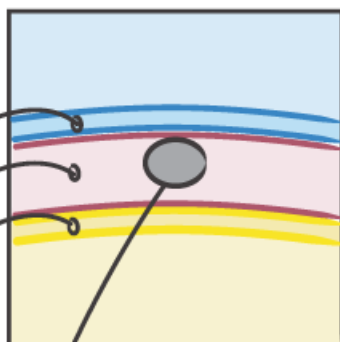
Trilaminar germ disc
Ectoderm
Mesoderm
Endoderm

Yolk sac

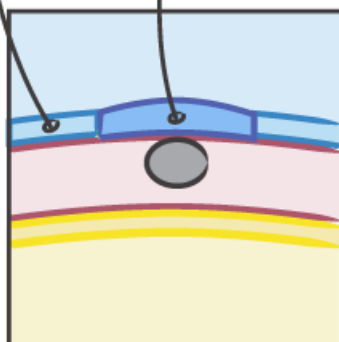
Notochord

- ✓ Forms the embryonic central axis.
- ✓ Induces neural plate formation.
- ✓ Est. spine: degenerates to nucleus pulposus.

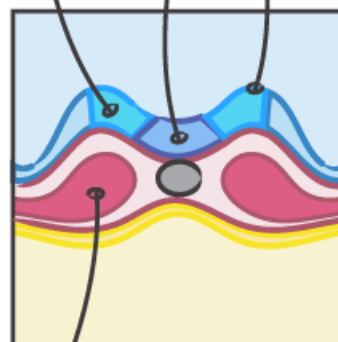
Ectoderm



Neural plate

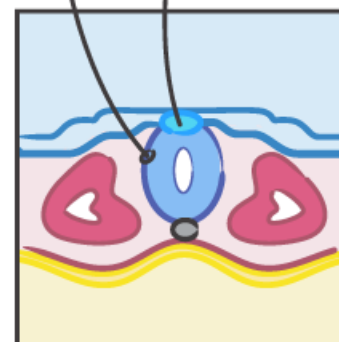


Neural fold

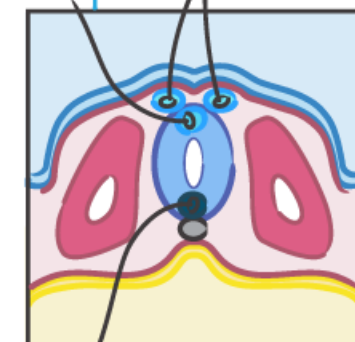


Neural crest: neural fold tips

Neural tube



Neural crest cells



Floor plate

- ✓ Somite (Paraxial mesoderm)
- ✓ Sclerotome (bone and cartilage)
- ✓ Myotome (skeletal muscle)
- ✓ Dermatome (dermis)



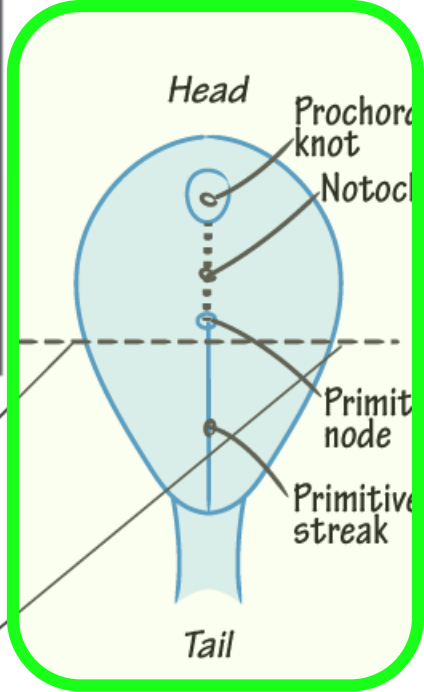


NEURULATION

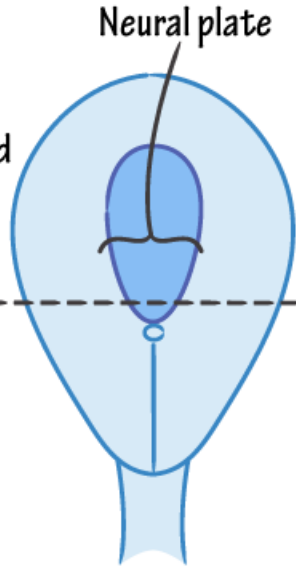
+ Neurulation

- ✓ Notochord induces overlying ectoderm to develop into the neural plate.
- ✓ The neural plate folds into the neural tube and the neural crests are pinched off.
- ✓ The neural tube derives the CNS.
- ✓ The neural crests derive the PNS + select other cells (eg, melanocytes).

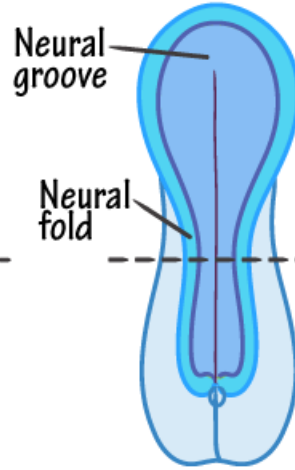
Superior View



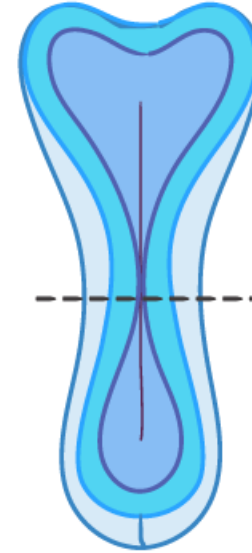
~ DAY 17



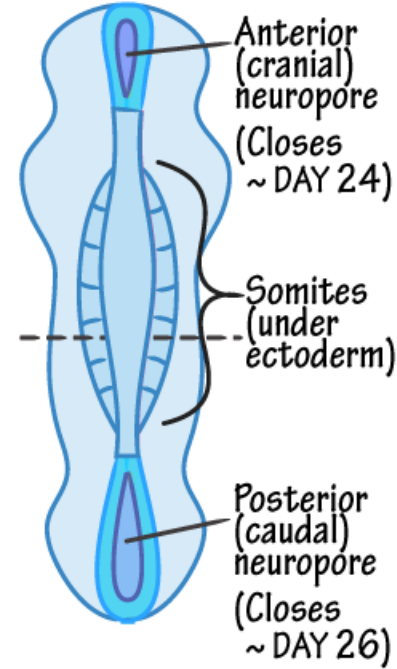
~ DAY 18



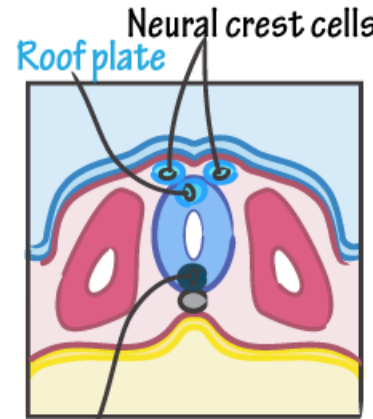
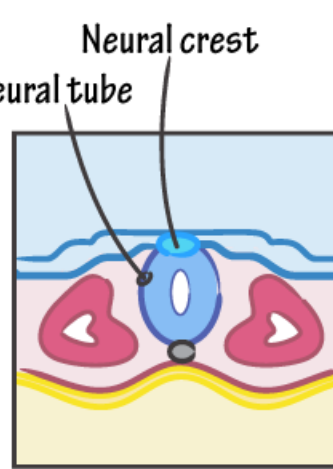
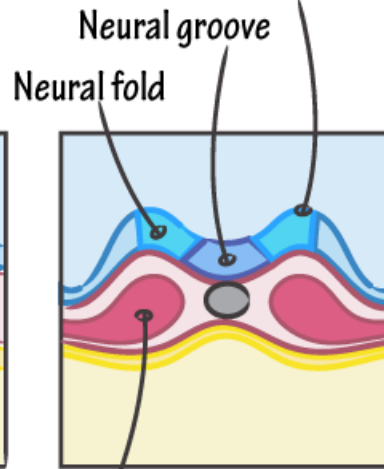
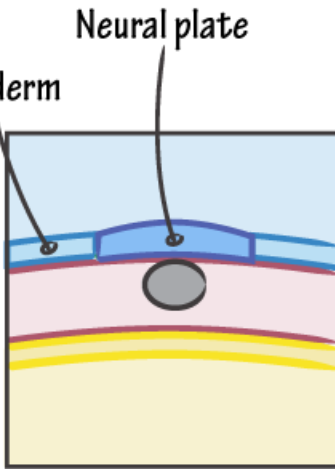
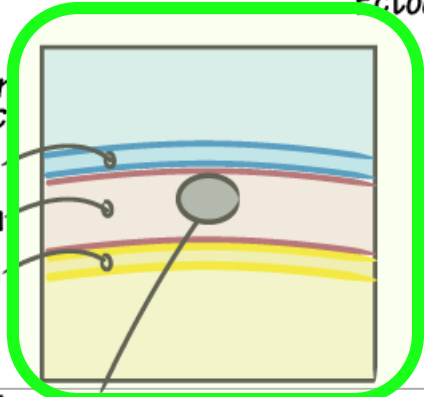
~ DAY 21



~ DAY 23



Coronal View



- Notochord**
- ✓ Forms the embryonic central axis.
 - ✓ Induces neural plate formation.
 - ✓ Est. spine: degenerates to nucleus pulposus.

- Somite (Paraxial mesoderm)**
- ✓ Sclerotome (bone and cartilage)
 - ✓ Myotome (skeletal muscle)
 - ✓ Dermatome (dermis)

Amniotic cavity

Primitive streak

Trilaminar germ disc

Ectoderm

Mesoderm

Endoderm

Yolk sac



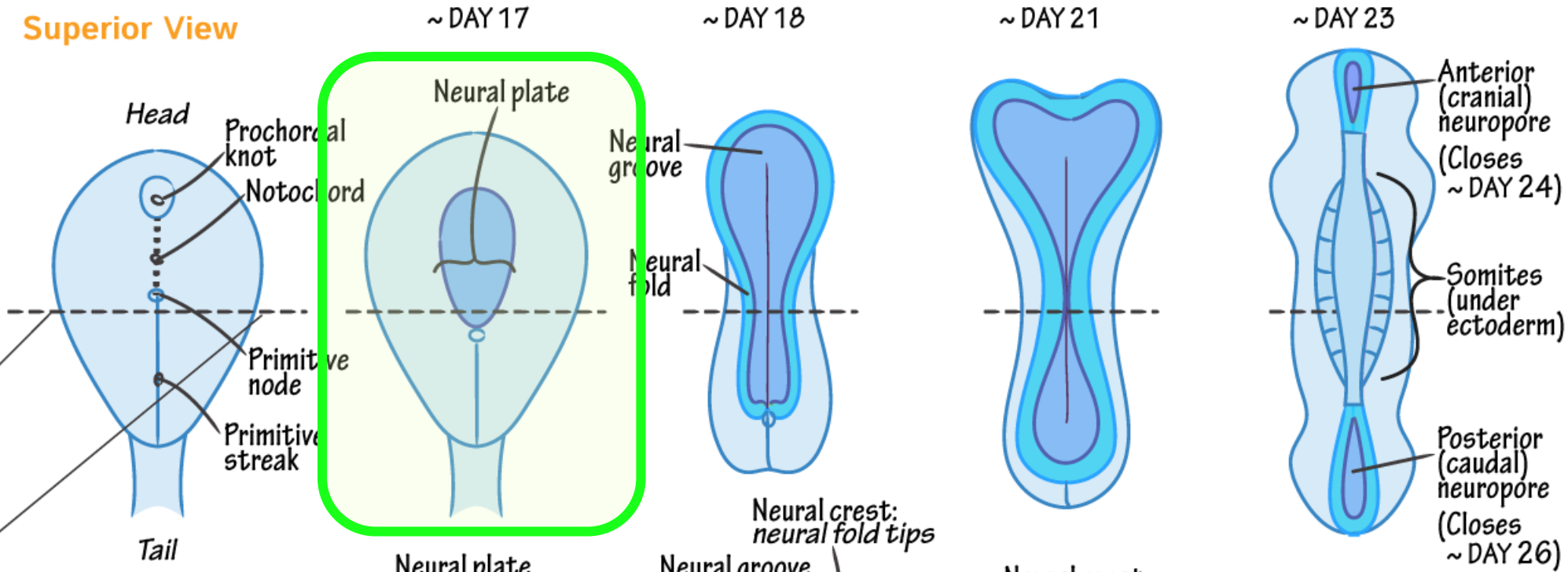


NEURULATION

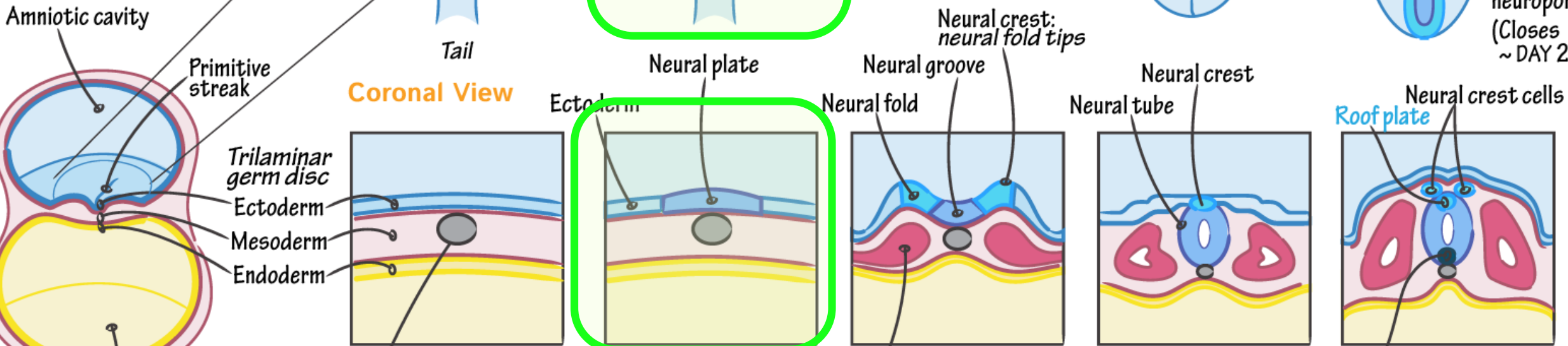
+ Neurulation

- ✓ Notochord induces overlying ectoderm to develop into the neural plate.
- ✓ The neural plate folds into the neural tube and the neural crests are pinched off.
- ✓ The neural tube derives the CNS.
- ✓ The neural crests derive the PNS + select other cells (eg. melanocytes).

Superior View



Coronal View



- Notochord**
- ✓ Forms the embryonic central axis.
 - ✓ Induces neural plate formation.
 - ✓ Est. spine: degenerates to nucleus pulposus.

- Somite (Paraxial mesoderm)**
- ✓ Sclerotome (bone and cartilage)
 - ✓ Myotome (skeletal muscle)
 - ✓ Dermatome (dermis)



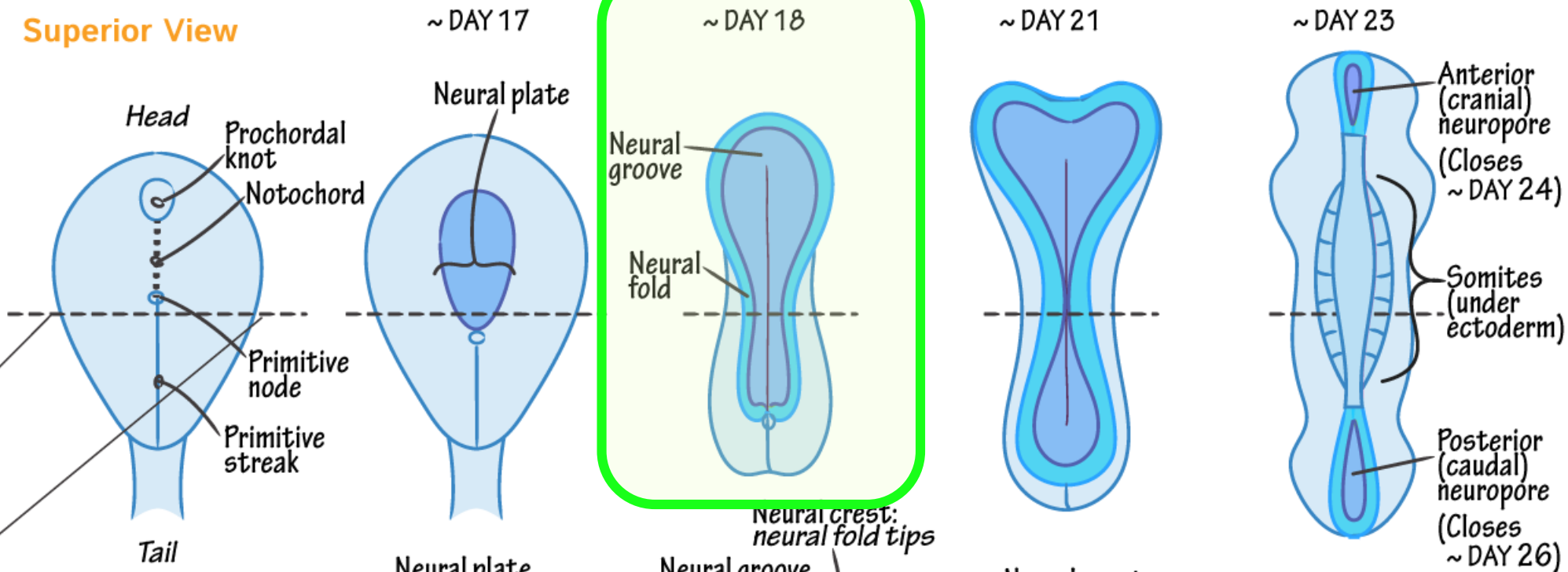


NEURULATION

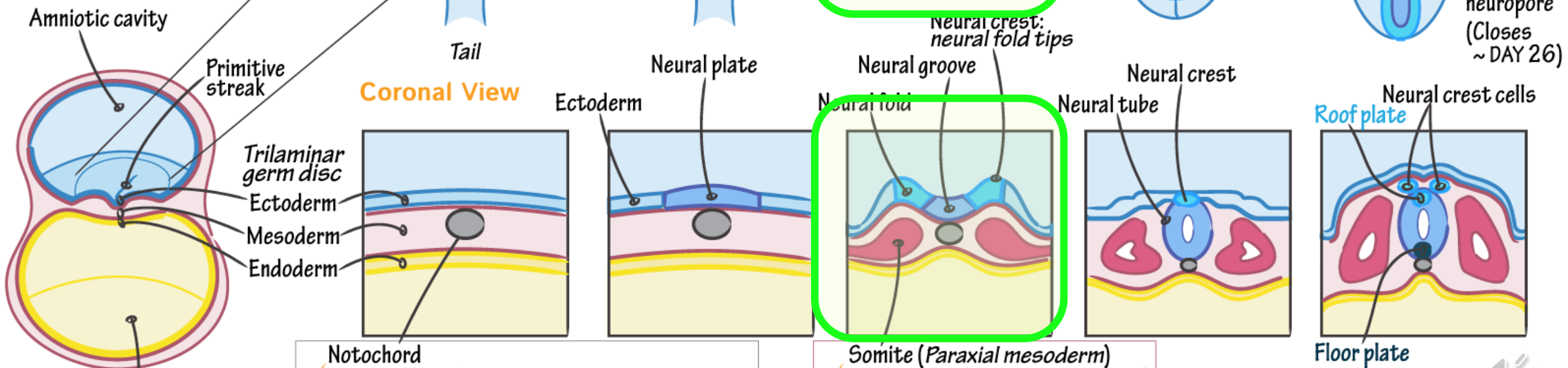
+ Neurulation

- ✓ Notochord induces overlying ectoderm to develop into the neural plate.
- ✓ The neural plate folds into the neural tube and the neural crests are pinched off.
- ✓ The neural tube derives the CNS.
- ✓ The neural crests derive the PNS + select other cells (eg. melanocytes).

Superior View



Coronal View



- ✓ Notochord
- ✓ Forms the embryonic central axis.
- ✓ Induces neural plate formation.
- ✓ Est. spine: degenerates to nucleus pulposus.

- ✓ Somite (Paraxial mesoderm)
- ✓ Sclerotome (bone and cartilage)
- ✓ Myotome (skeletal muscle)
- ✓ Dermatome (dermis)



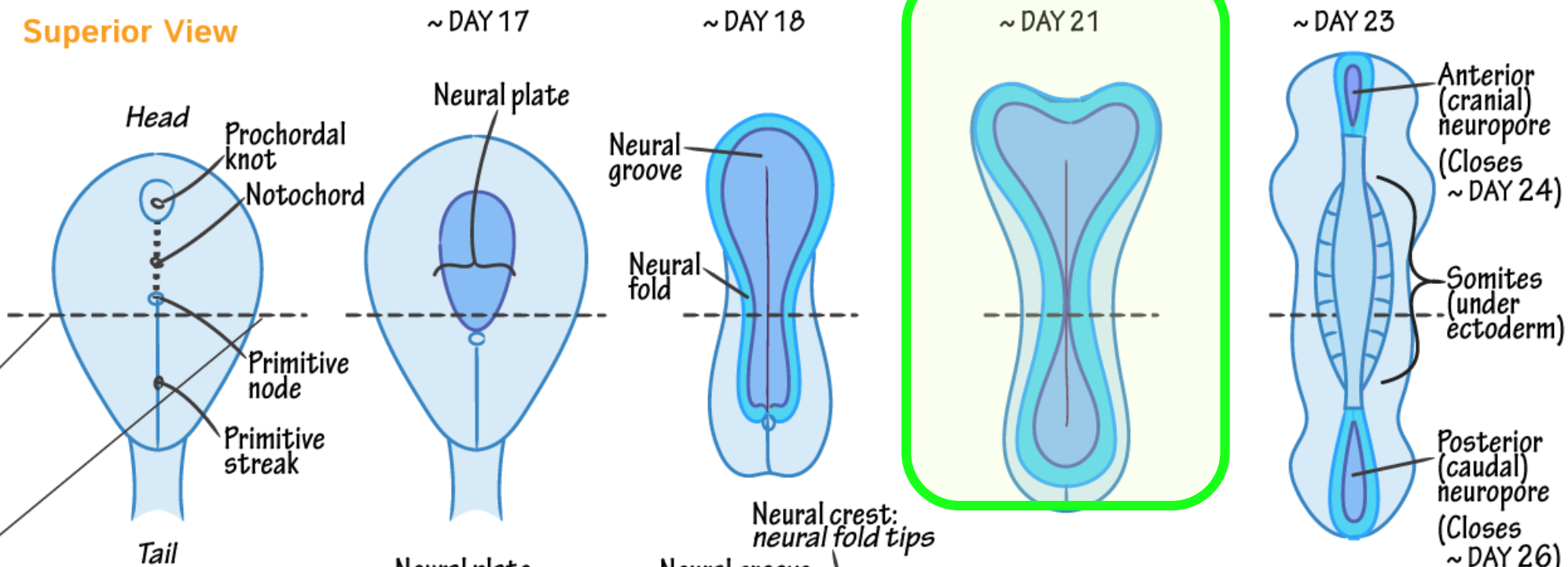


NEURULATION

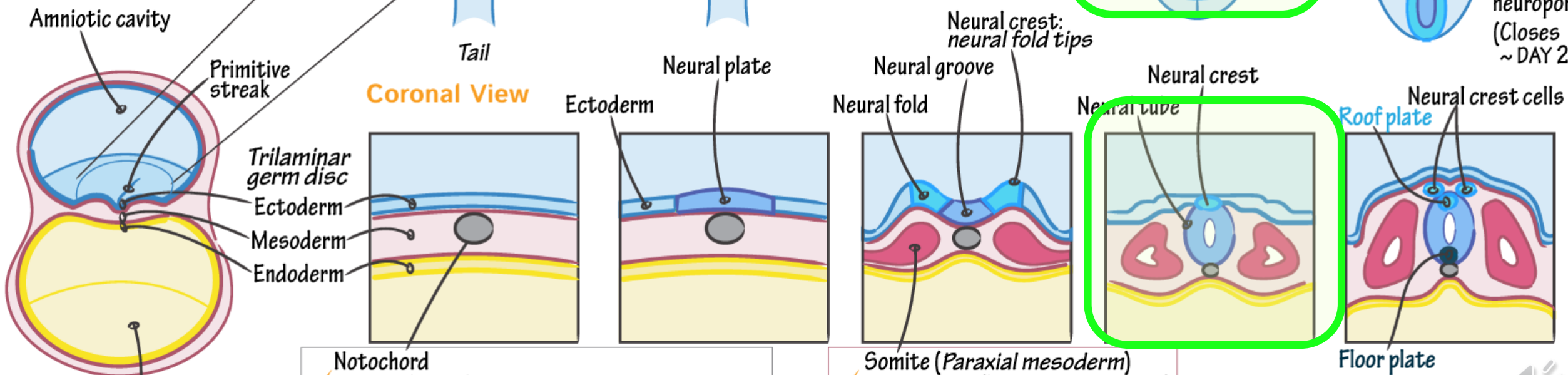
+ Neurulation

- ✓ Notochord induces overlying ectoderm to develop into the neural plate.
- ✓ The neural plate folds into the neural tube and the neural crests are pinched off.
- ✓ The neural tube derives the CNS.
- ✓ The neural crests derive the PNS + select other cells (eg. melanocytes).

Superior View



Coronal View



- ✓ Notochord
- ✓ Forms the embryonic central axis.
- ✓ Induces neural plate formation.
- ✓ Est. spine: degenerates to nucleus pulposus.

- ✓ Somite (Paraxial mesoderm)
- ✓ Sclerotome (bone and cartilage)
- ✓ Myotome (skeletal muscle)
- ✓ Dermatome (dermis)



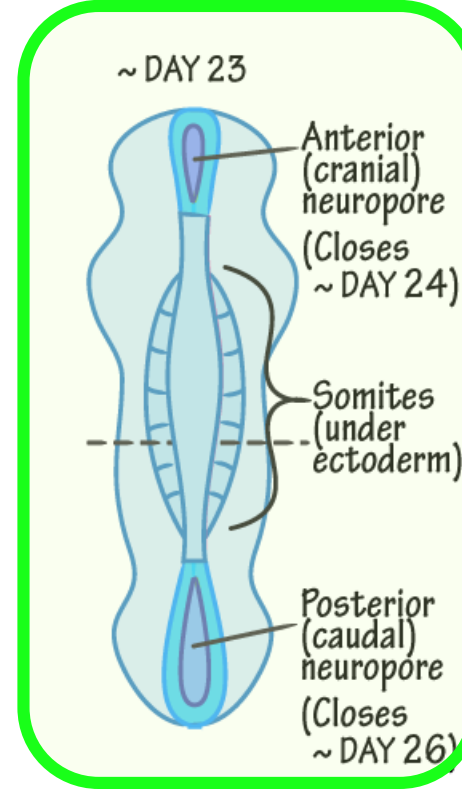
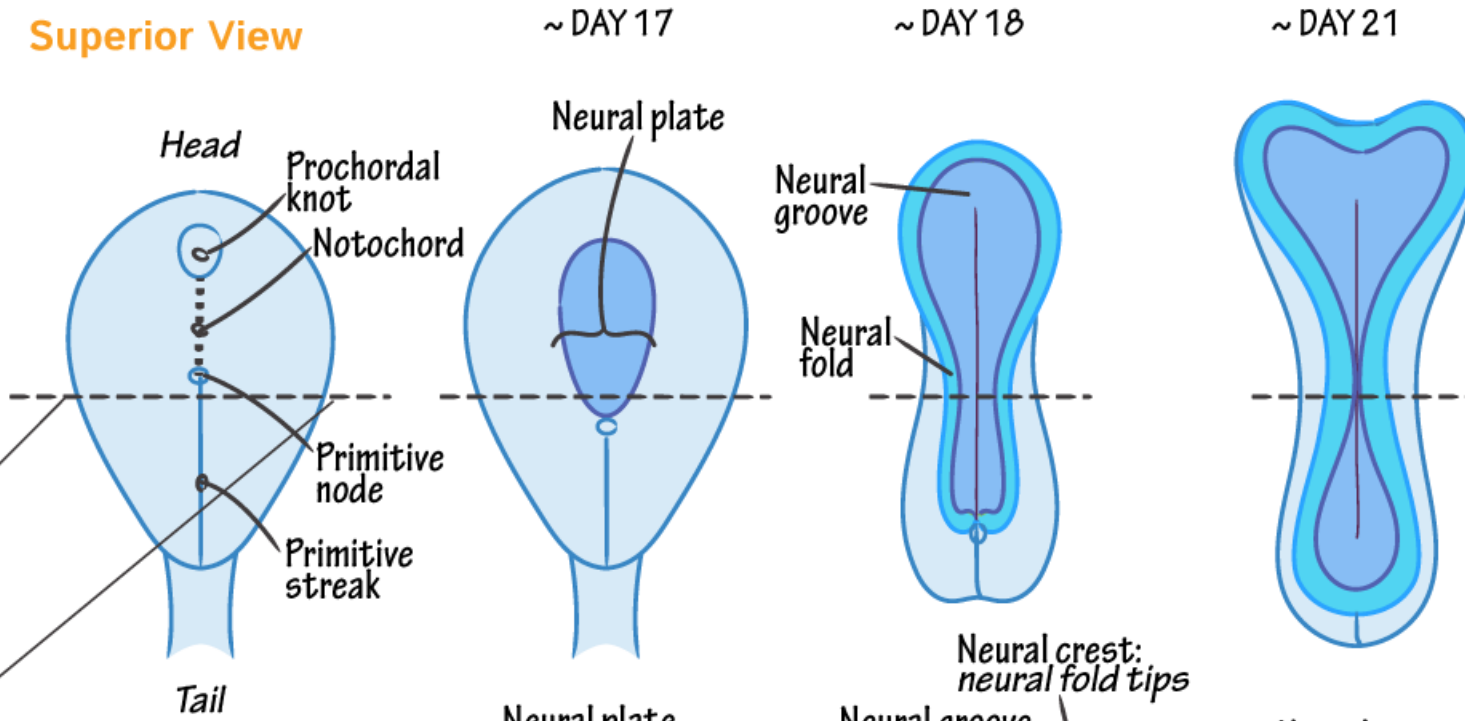


NEURULATION

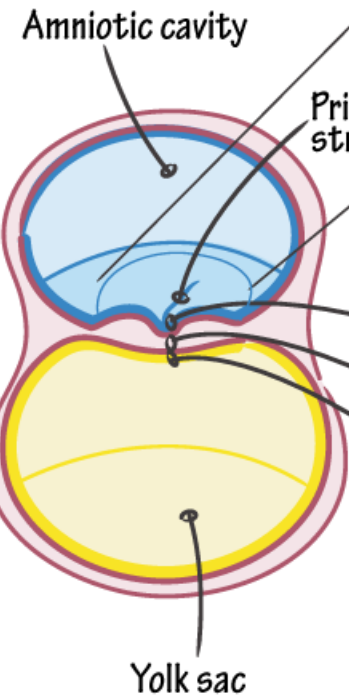
+ Neurulation

- ✓ Notochord induces overlying ectoderm to develop into the neural plate.
- ✓ The neural plate folds into the neural tube and the neural crests are pinched off.
- ✓ The neural tube derives the CNS.
- ✓ The neural crests derive the PNS + select other cells (eg, melanocytes).

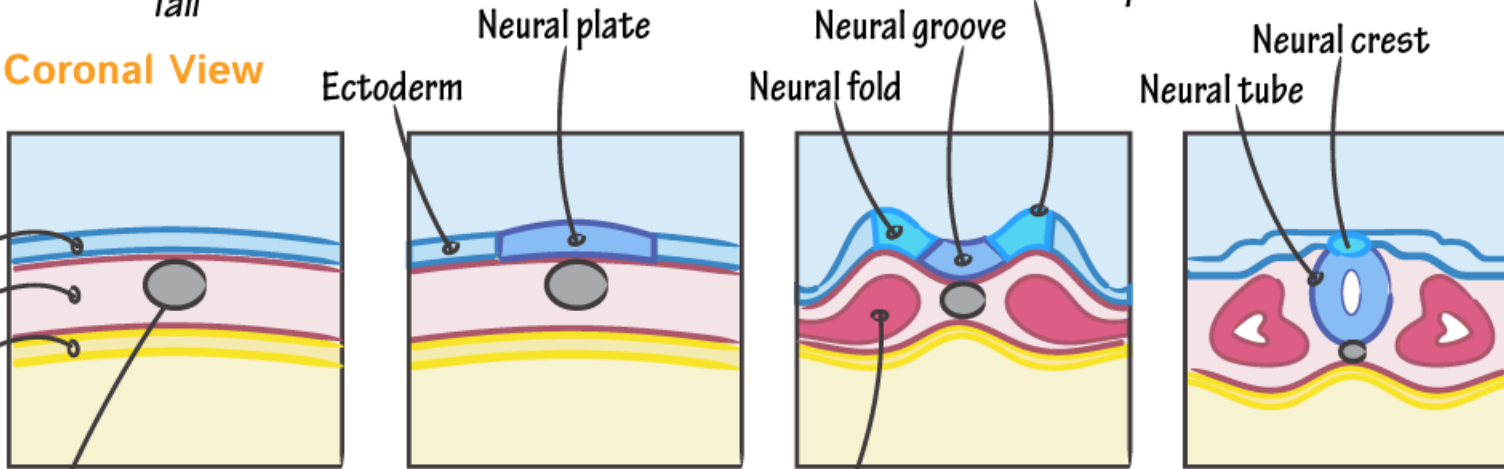
Superior View



Coronal View

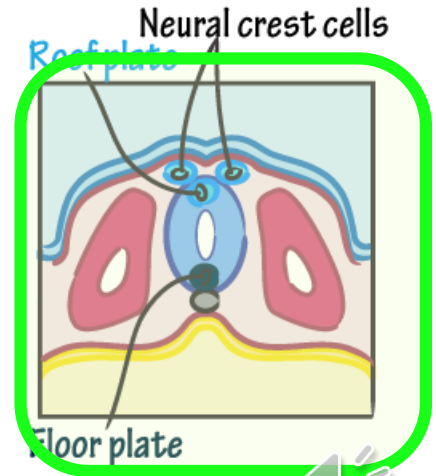


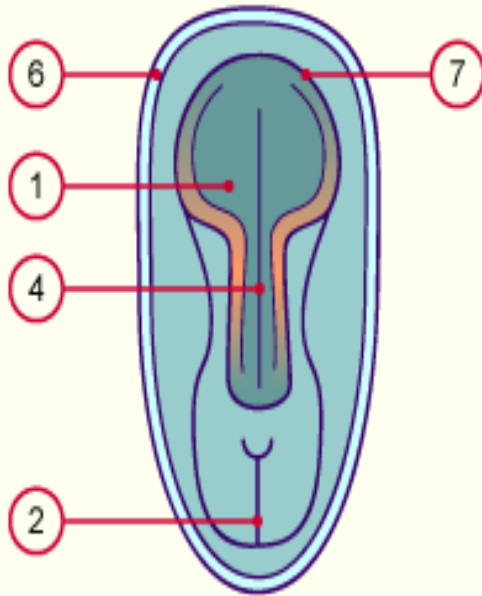
- Trilaminar germ disc
- Ectoderm
- Mesoderm
- Endoderm



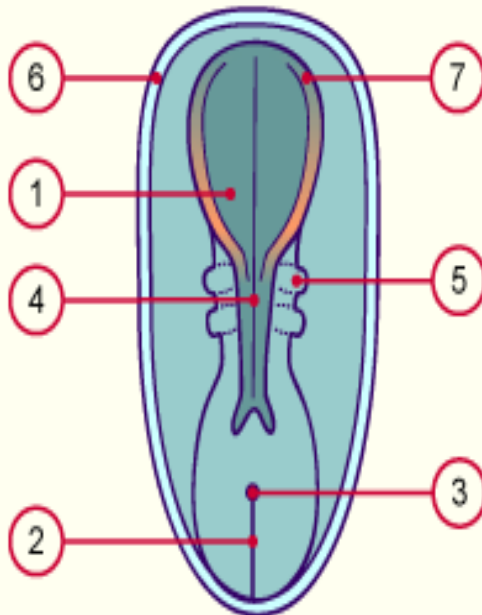
- Notochord
- ✓ Forms the embryonic central axis.
- ✓ Induces neural plate formation.
- ✓ Est. spine: degenerates to nucleus pulposus.

- Somite (Paraxial mesoderm)
- ✓ Sclerotome (bone and cartilage)
- ✓ Myotome (skeletal muscle)
- ✓ Dermatome (dermis)



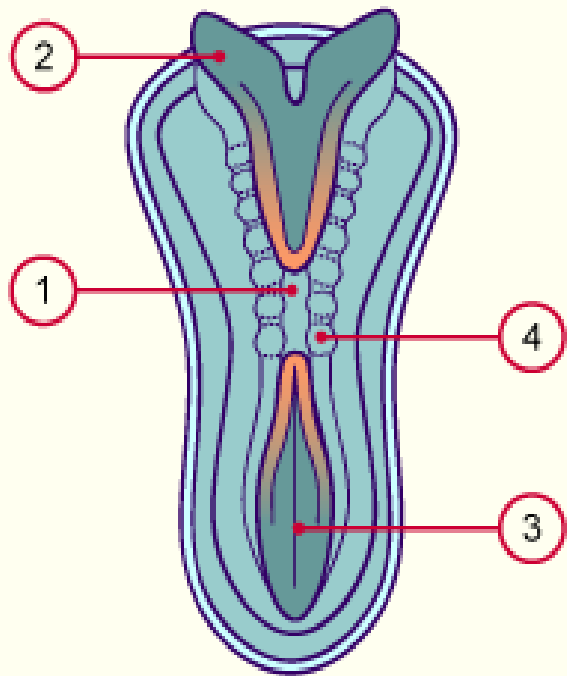


1. Surco neural a nivel cefálico (amplio)
2. Línea primitiva cerrándose
4. Surco neural a nivel troncal
6. Membrana amniótica (ect ext + mes. Ext.)
7. Neuroporo anterior

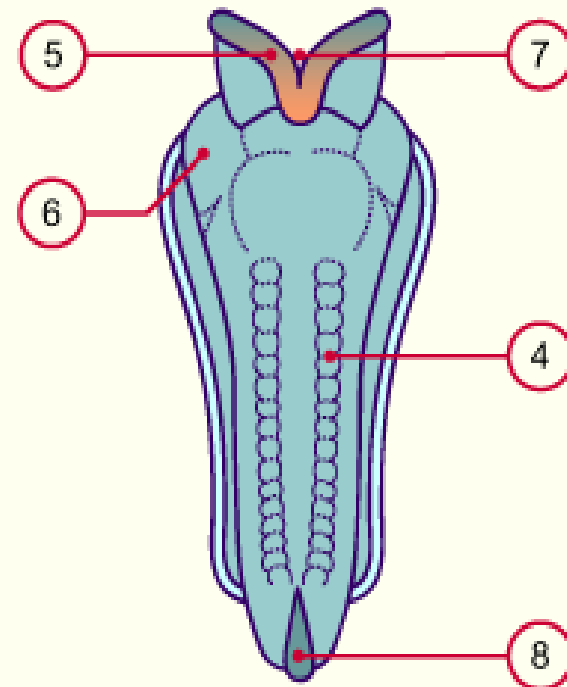


1. Surco neural a nivel cefálico
2. Línea primitiva en retroceso
3. Nudo de Hensen en retroceso
4. Cierre del tubo neural a nivel del cuello
5. Desarrollo de primeras somitas
6. Membrana amniótica (ect ext + mes. Ext.)
7. Neuroporo anterior





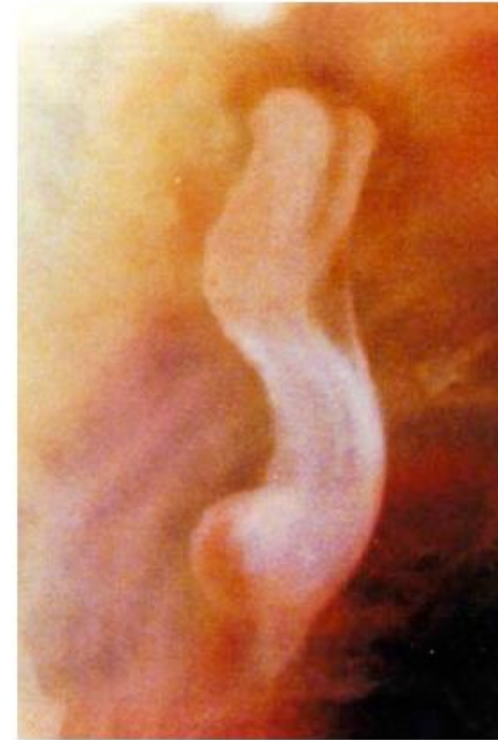
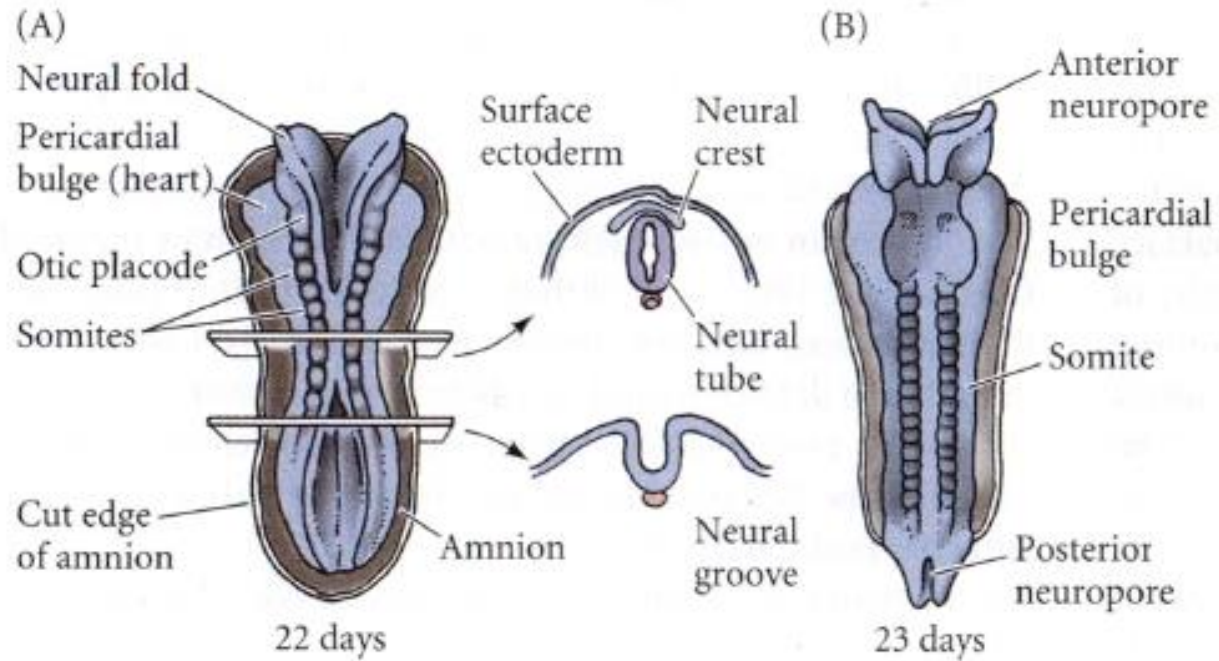
1. Tubo neural cerrado a nivel del cuello
2. Neuroporo anterior
3. Neuroporo posterior
4. Somitas



4. Somitas
5. Neuroporo anterior
6. Cierre del tubo neural en la región anterior, desarrollo del cerebro y cefalización.
7. Surco neural amplio en la región anterior
8. Neuroporo posterior

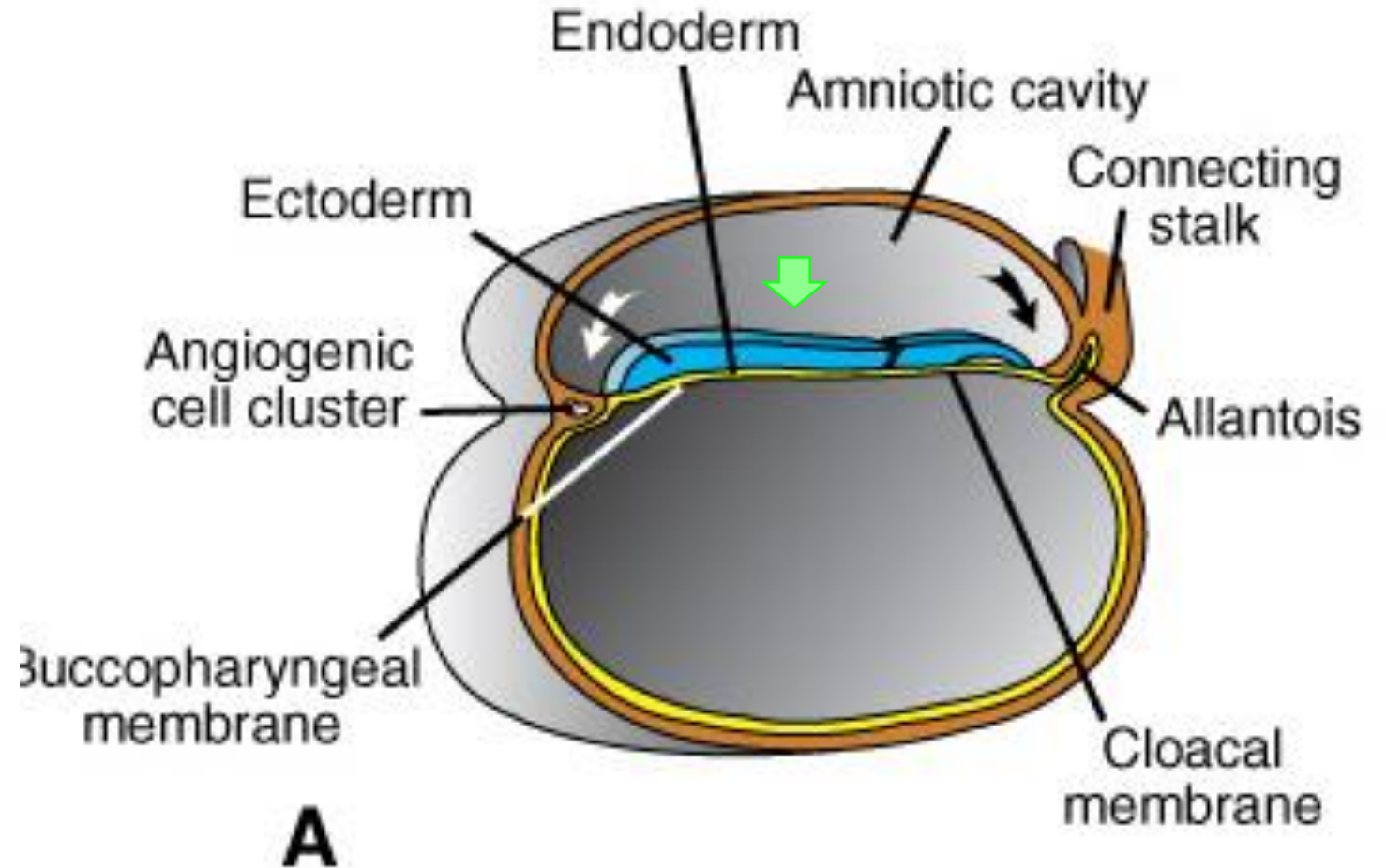
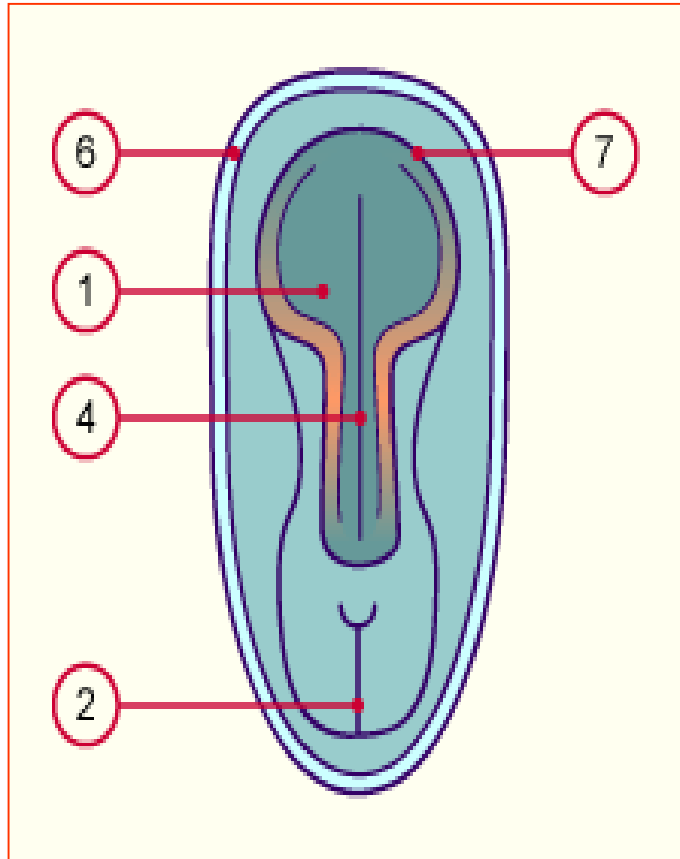


Human embryo undergoing neurulation
(3 weeks post-fertilization; 2 mm long)

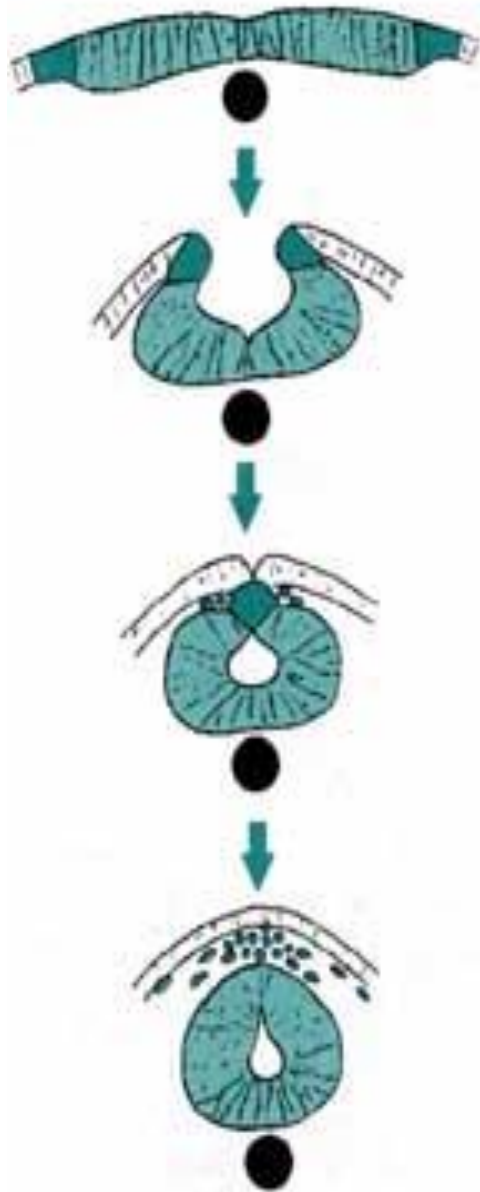


[from Lennart Nilsson *A Child is Born*, p. 76]

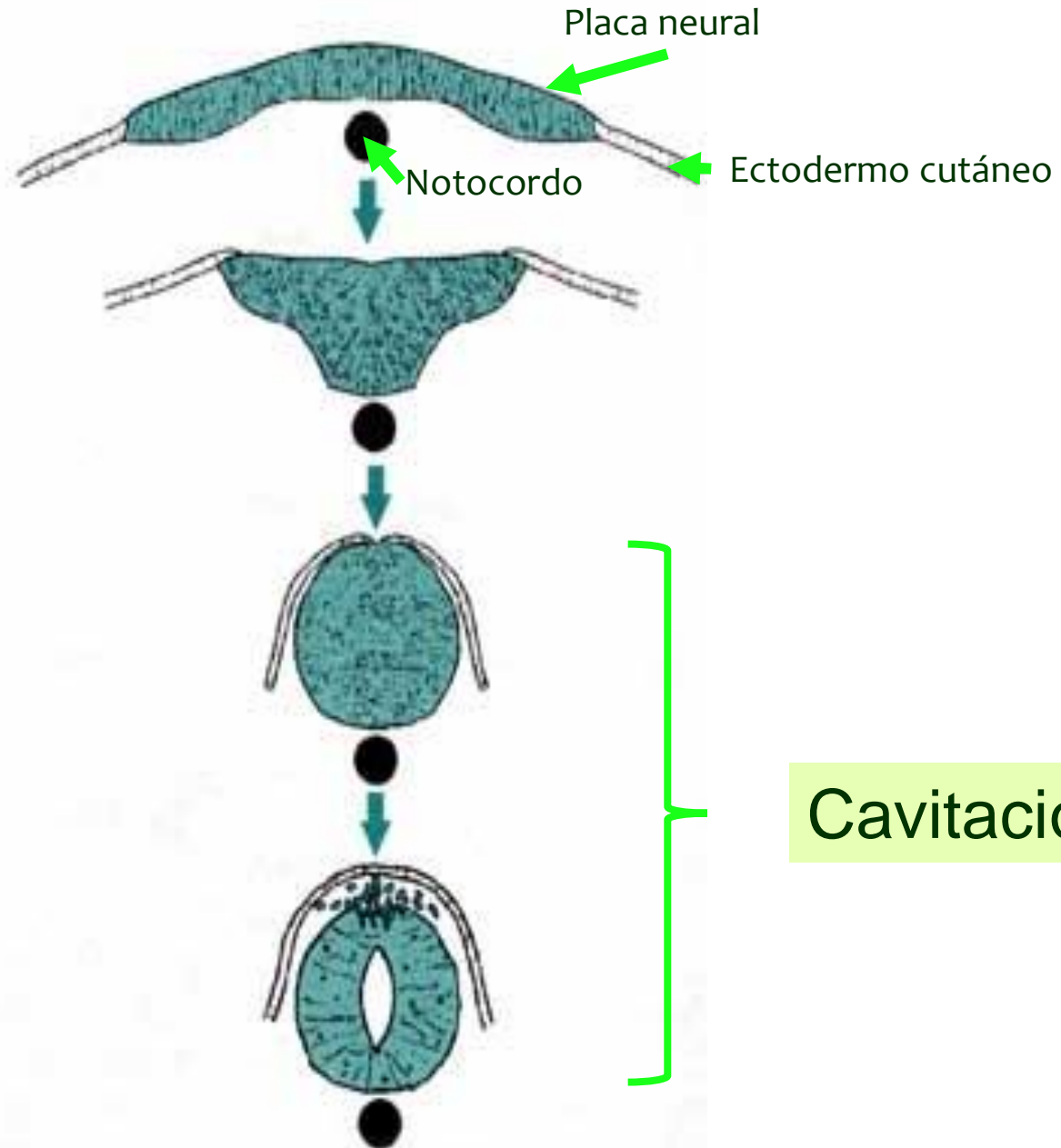




A. Amphibian



B. Teleost fish



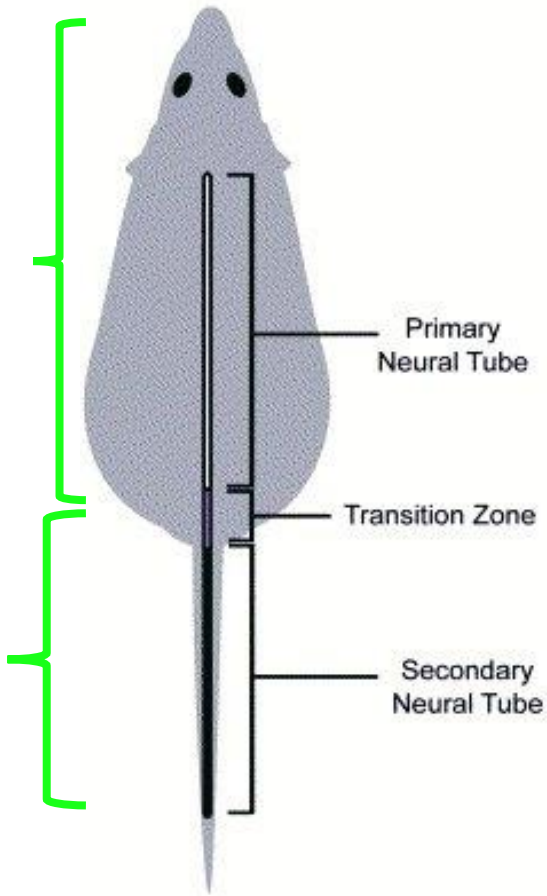
Neurulación

A

B

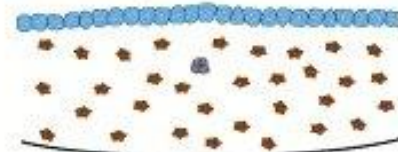
1a

2a

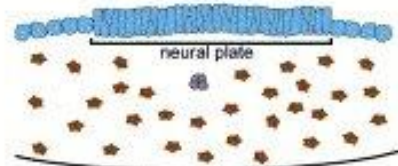


Primary Neurulation

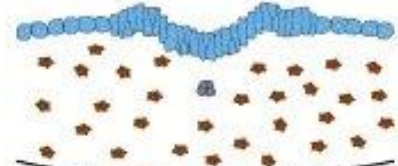
1. Initial epithelium



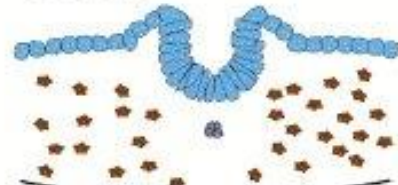2. Columnarization



3. Rolling/folding



4. Closure

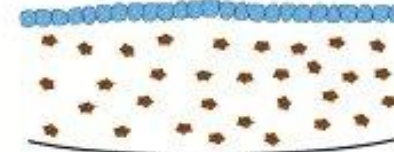

5. Neural tube complete



Secondary neurulation

1. Dispersed mesenchyme



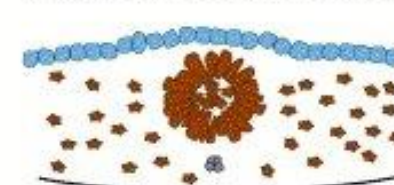
2. Mesenchymal condensation



3. Medullary cord/neural rod



4. Epithelial transition/cavitation



5. Neural tube complete



Mesénquima
primario



Condensación celular



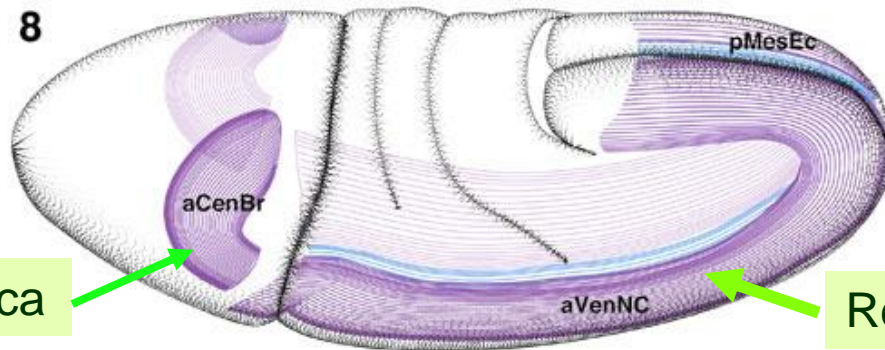
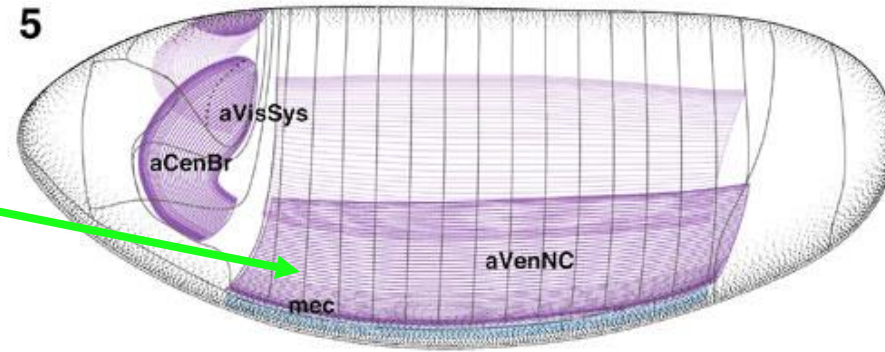
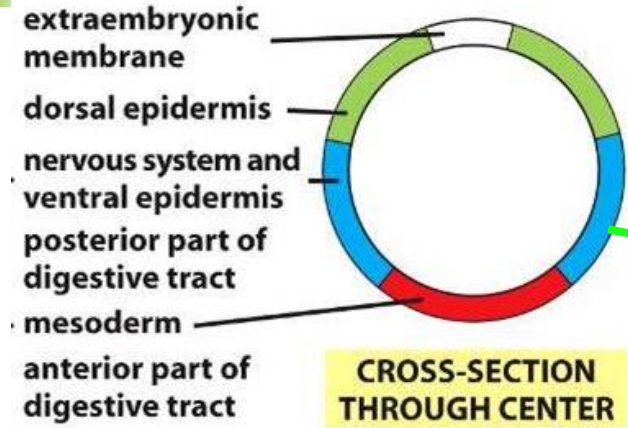
Cavitación



Tubo neural

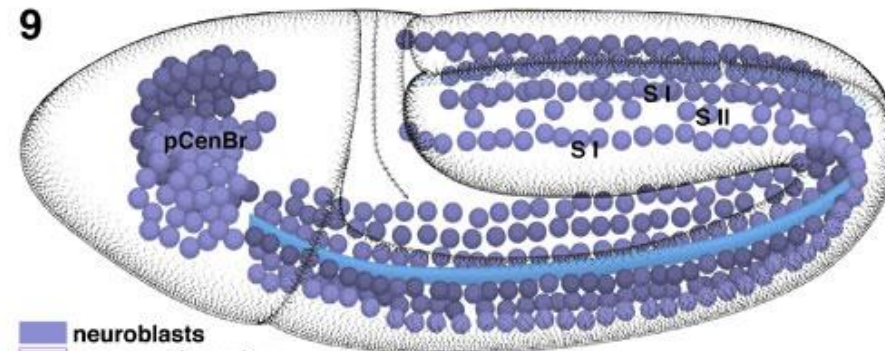


Central Nervous System



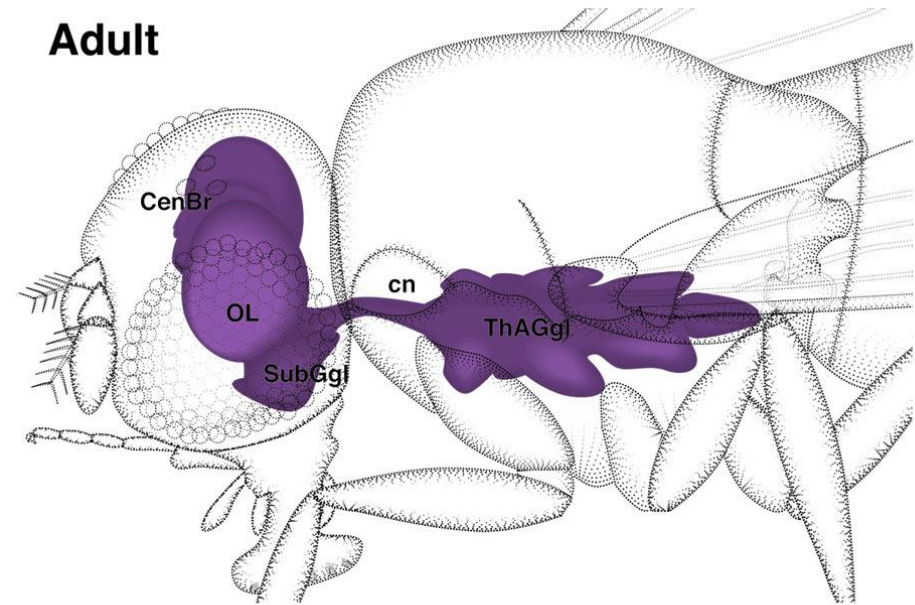
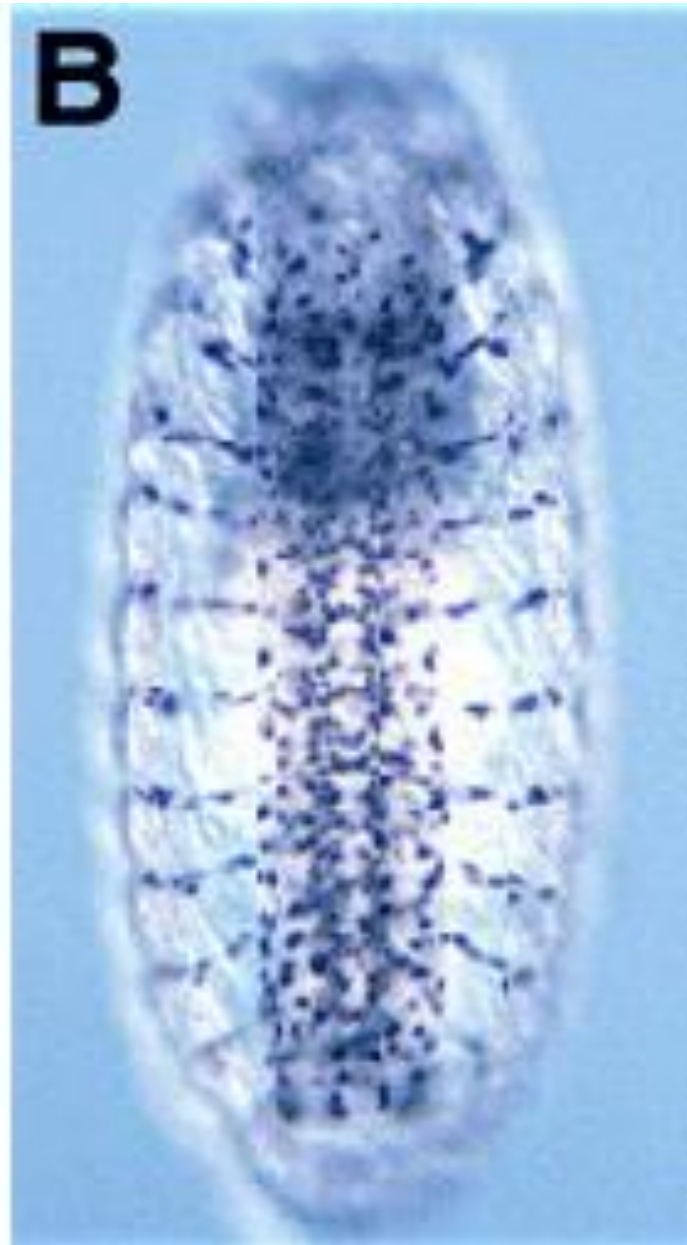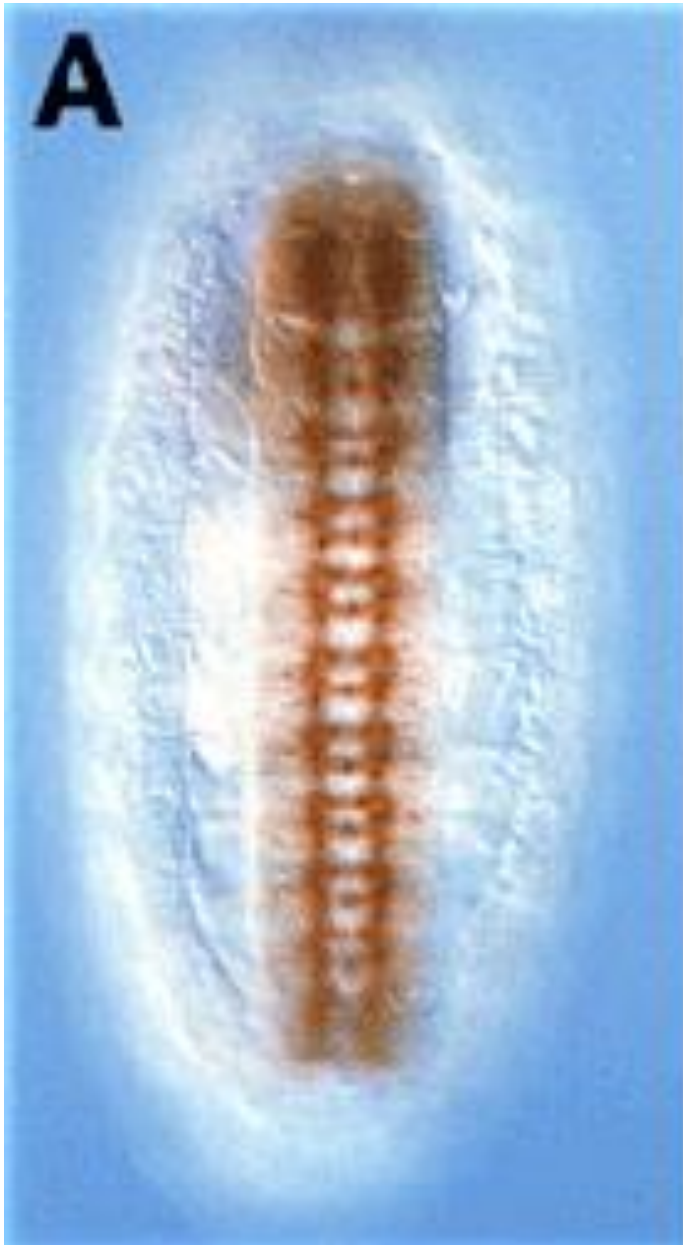Región neurogénica procefálica


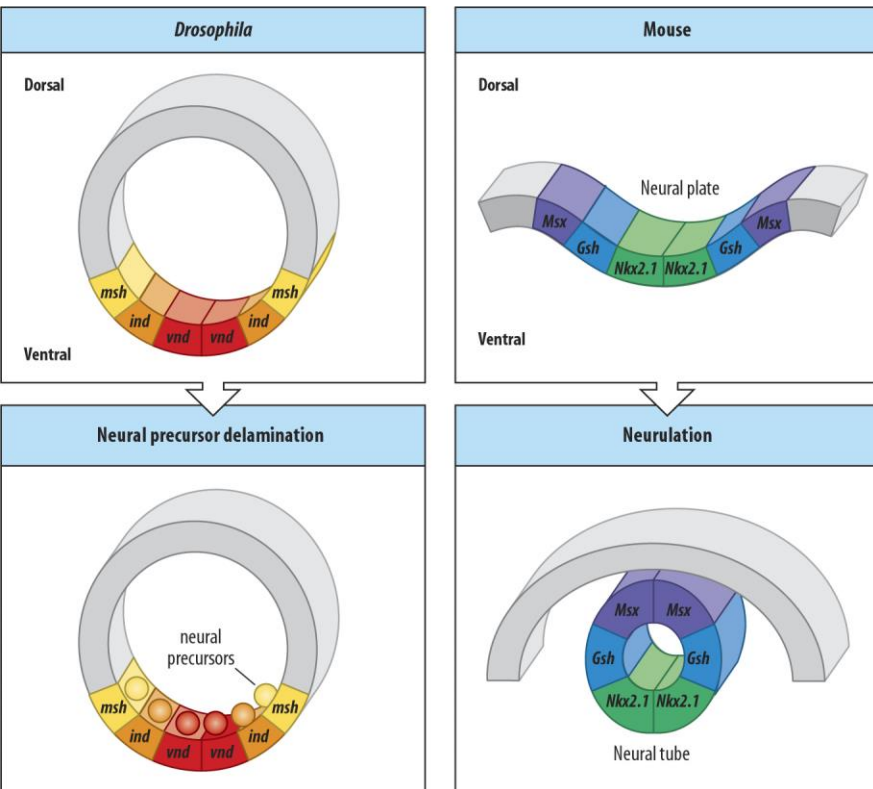
Región neurogénica ventral



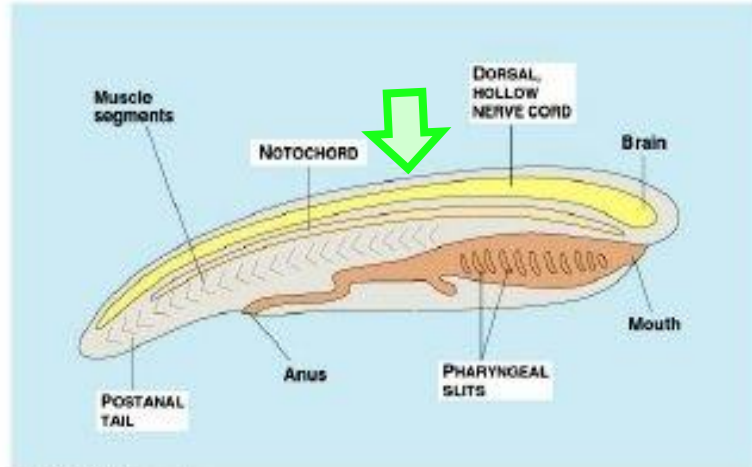
neuroblasts
neurogenic region
mesectoderm







DORSAL ectoderm in deuterostomes

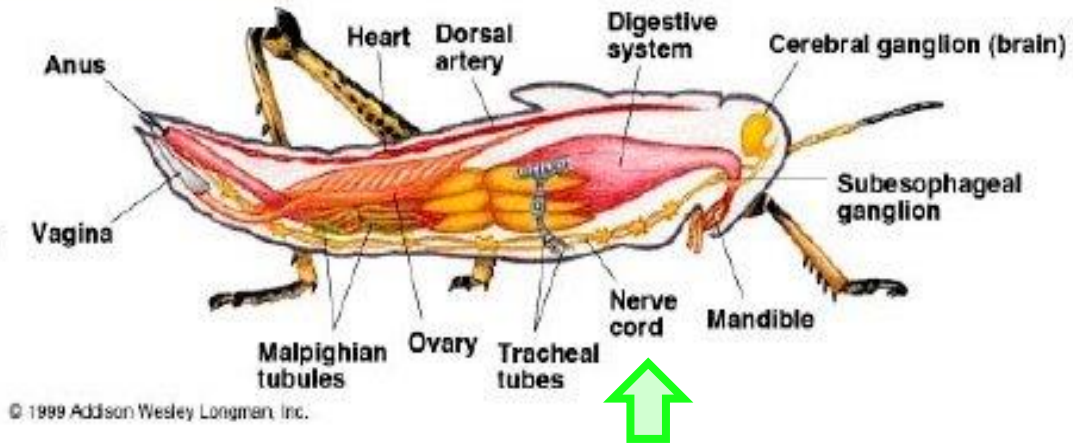


© 1990 Addison Wesley Longman, Inc.

Campbell 34.1

and

VENTRAL ectoderm in protostomes



© 1999 Addison Wesley Longman, Inc.

*Many of the same signaling molecules are employed!
Implications for evolution?*



